

6-27-2013

Treatment of dentin hypersensitivity with a combination of nano-fluorhydroxyapatite and Nd:YAG laser

Saeed ALI

Kholood AL SAFFI

Raad NIAMA DAYEM

Follow this and additional works at: <https://digitalcommons.aaru.edu.jo/iajd>

Recommended Citation

ALI, Saeed; AL SAFFI, Kholood; and NIAMA DAYEM, Raad (2013) "Treatment of dentin hypersensitivity with a combination of nano- fluorhydroxyapatite and Nd:YAG laser," *International Arab Journal of Dentistry*. Vol. 4: Iss. 2, Article 6.

Available at: <https://digitalcommons.aaru.edu.jo/iajd/vol4/iss2/6>

This Original Article is brought to you for free and open access by Arab Journals Platform. It has been accepted for inclusion in International Arab Journal of Dentistry by an authorized editor. The journal is hosted on [Digital Commons](#), an Elsevier platform. For more information, please contact rakan@aarj.edu.jo, marah@aarj.edu.jo, u.murad@aarj.edu.jo.

TREATMENT OF DENTIN HYPERSENSITIVITY WITH A COMBINATION OF NANO- FLUOR-HYDROXYAPATITE AND Nd:YAG LASER

Saeed Ali* | Kholood Al Saffi** | Raad Niama Dayem***

Abstract

The aim of this study was to evaluate a new treatment modality of dentin hypersensitivity combining nano-fluor-hydroxyapatite (NFH) and Nd:YAG laser and to compare its effect with other therapies such as cyanoacrylate and sodium fluoride using scanning electron microscope.

Sixty freshly extracted human premolar teeth were collected. The coronal portion of each tooth was removed and the canals were instrumented and obturated with gutta-percha. A 3 mm wide ring of root surface was cut with a rotary instrument to expose the underlying dentin. Teeth were randomly separated into six groups of ten teeth each: 1) combination of NFH and Nd:YAG laser; 2) Nd:YAG laser; 3) NFH; 4) desensitizing cyanoacrylate resin bonding (Tetric® N Ceram); 5) 2% sodium fluoride; 6) control group. The topography of each group after treatment was determined by scanning electron micrograph. The percentage of occluded tubules was calculated by dividing the total number of occluded tubules by the total number of tubules in each photomicrography.

The highest occluding effect of dentinal tubules was obtained for the combination of NFH and Nd:YAG laser ($99.8 \pm 3.3\%$). However, no significant difference was found among groups 2 ($83.1 \pm 5.2\%$), 3 ($82.3 \pm 4.4\%$), 4 ($82.1 \pm 7.2\%$) and 5 ($81.4 \pm 3.5\%$) ($p > 0.05$); these treatment modalities showed similar occluding effect on dentinal tubules.

The use of NFH and Nd:YAG laser was beneficial for closure of exposed dentinal tubules compared to other treatment modalities. This approach could be promising for dentin hypersensitivity treatment.

Keywords: *Dentin hypersensitivity – nano-fluor-hydroxyapatite - Nd:YAG laser - scanning electron microscope – dentinal tubules.*

IAJD 2013;4(2):83-88.

TRAITEMENT DE L'HYPERSENSIBILITÉ DENTINAIRE AVEC UNE COMBINAISON DE NANO-FLUORHYDROXYAPATITE ET DE LASER Nd: YAG

Résumé

Le but de cette étude était d'évaluer une nouvelle modalité de traitement de l'hypersensibilité dentinaire combinant la nanofluorohydroxyapatite (NFH) et laser Nd: YAG et de la comparer à d'autres thérapies telles que le fluorure de sodium et le cyanoacrylate.

Soixante prémolaires humaines fraîchement extraites ont été recueillies. La partie coronaire de chaque dent a été coupée et les canaux ont été instrumentés et obturés avec de la gutta-percha. Un anneau de 3 mm de largeur de la surface de la racine a été coupé avec un instrument rotatif pour exposer la dentine sous-jacente. Les dents ont été aléatoirement réparties en six groupes de dix dents chacun: 1) couplage NFH / laser Nd: YAG, 2) laser Nd: YAG; 3) NFH; 4) résine cyanoacrylate (Tetric® N Ceram); 5) 2% de fluorure de sodium; 6) groupe témoin. La topographie de chaque groupe après le traitement a été déterminée par microscopie électronique à balayage et le pourcentage de tubules oblitérés a été calculé.

Un plus grand nombre de tubulis oblitérés a été observé dans le groupe 1 (couplage NFH / laser Nd: YAG ($99,8 \pm 3,3\%$)). Toutefois, aucune différence statistiquement significative n'a été observée entre les groupes 2 ($83,1 \pm 5,2\%$), 3 ($82,3 \pm 4,4\%$), 4 ($82,1 \pm 7,2\%$) et 5 ($81,4 \pm 3,5\%$) ($p > 0,05$).

L'utilisation combinée de l'NFH et du laser Nd: YAG a été bénéfique pour la fermeture des tubulis dentinaires exposés par rapport aux autres modalités de traitement. Cette approche paraît très prometteuse pour le traitement de l'hypersensibilité dentinaire.

Mots-clés: *hypersensibilité dentinaire – nanofluorohydroxyapatite - microscope électronique à balayage – tubulis dentinaires.*

IAJD 2013;4(2):83-88.

* BDS, MSc
College of Dentistry, Hawler University, Erbil, Iraq

** BDS, MSc, PhD
College of Dentistry, University of Baghdad, Iraq

*** BDS, MSc, PhD
Michigan, USA
raad_niama2003@yahoo.com

Introduction

Dentin hypersensitivity (DH) is a sharp, localized and short pain in response to thermal, chemical, mechanical or osmotic stimuli, ceasing after the stimulus removal. The etiology of hypersensitivity is multifactorial and the factors involved are unclear [1].

There are several theories for dentinal hypersensitivity such as the odontoblastic transduction theory [2, 3], the neural theory [4] and the hydrodynamic theory [5, 6]. The most accepted for dentinal hypersensitivity is the hydrodynamic theory first described by Brannstrom [5, 6]: the free endings of the nerve fibers located around the odontoblastic body and the inner dentine are probably activated by fluid movement within tubules from a variety of stimuli. Hoang et al. [7] confirmed in their study that the flow of liquids in dentinal tubules can trigger nerves along the pulpal canal of the dentin, causing pain.

In order to exhibit a response to the stimulus, the tubules would have to be opened at the dentin surface. The most important variable affecting the fluid flow in dentin is the radius of the tubuli. If the radius is reduced by one-half, the fluid flow within the tubuli falls to one-sixteenth of its original rate. Consequently, the creation of a smear layer or obliteration of the tubules can greatly increase the effectiveness of a desensitizing treatment [8]. Various findings concerning the occluding effect of desensitizing agents on open dentinal tubules have been reported, but the permeation through dentinal tubules is still problematic [9].

There is a surprisingly large number of treatment options for managing dentinal hypersensitivity.

Chemical or physical agents are used to either desensitize the nerve or cover the exposed dentinal tubules [8].

Cyanoacrylate has an immediate desensitizing effect on hypersensitive dentin, has been shown to be biocompatible, and may be used to treat hypersensitive teeth. It blocks the den-

tinal tubules, prevents displacement of fluids within the tubules, and results in little or no response to stimuli [10]. It has the advantages of being a low-cost product, readily available, easily applicable, effective and safe [11].

Treatment of the exposed root surfaces with sodium fluoride toothpaste and concentrated fluoride solutions is very efficient in managing dentinal hypersensitivity. The mode of action appears to be through the induction of a high mineral content which creates a calcific barrier blocking the tubular openings on the dentine surface [12].

Hydroxyapatite (HA) is the main component of human bones and teeth [13, 14]. Synthetic HA has become one of the hot topics for biological material research over the past few decades due to its biocompatibility and its bioactivity. Since HA has a crystal structure similar to human teeth, preliminary researches exploring the effects of HA in easing dentine hypersensitivity, remineralization of early enamel lesion, and whitening by adding HA to dentifrice have been reported in recent years [15, 16].

In fact, the fluor-hydroxyapatite forms solid solutions with HA by the replacement of OH⁻ by F⁻. Hence, modulation of the extent of fluoride substitution provides an effective way of controlling the solubility of the apatite [17].

Mesoporous silica biomaterial, which contains nano-sized calcium oxide particles (40 nm) has been used by Chiang et al. [18]. These nano-carriers can penetrate through dentinal tubules with a depth of 100 µm and significantly reduce dentin permeability. Thus, using nano-sized particles might have great potential applications for the clinical treatment of dentin hypersensitivity. Further investigations are being conducted to test its feasibility under clinical application parameters, such as wear resistance, longevity in saliva, and biocompatibility.

Laser technology has gained popularity over the recent years, and many applications of laser technology in dentistry and medicine have been proposed. The first use of laser in the treatment of

DH was reported by Matsumoto et al. [19]. The mechanism of action of the neodimium:yttrium-aluminum garnet (Nd:YAG) laser on dentin involves thermal energy absorption. Hydroxyapatite crystals melt in the presence of sufficient amount of energy leading to the closure of dentin tubules [20]. Given its ability to close the dentin tubules and decrease hydraulic conductance, the Nd:YAG laser would appear to have a potential to reduce root surface hypersensitivity without harming the dentin surface [21].

The use of a combination of nano-fluor-hydroxyapatite (NFH) with laser to induce closing the dentinal tubules is not described in the literature. The aim of this study was to evaluate the use of a combination of NFH and Nd:YAG laser in reducing dentin permeability and obliterating dentinal tubules and to compare the generated effect with other conventional modalities.

Material and Methods

Sample preparation

Sixty freshly extracted human premolar teeth were collected and stored in normal saline solution at room temperature. The coronal portion of each tooth was removed to the level of the cervical line using a diamond disc. The patency of each canal was established using a k-file #10, the pulpal tissue was removed by using barbed broaches and the working length was determined by subtracting 1 mm from the length at which the tip of the k-file just appeared at the apical foramen. The canals were instrumented using a conventional hand instrumentation technique and a master apical file # 60 k-type. Each canal was irrigated with 2.5% sodium hypochlorite solution then dried with paper points. Master gutta-percha cones were fitted to within 1 mm of the working length. The canals were obturated completely using the lateral condensation technique and zinc oxide type sealer. Excess gutta-percha was removed with a heated instrument to a level 2 mm apical to the canals ori-

Groups	Treatment groups	Mean (%)
1	NFH + Nd:YAG laser	99.8 ± 3.3
2	Nd:YAG laser	83.1 ± 5.2
3	NFH	82.3 ± 4.4
4	Cyanoacrylate (Tetric® N Ceram)	82.1 ± 7.2
5	2% Sodium fluoride	81.4 ± 3.5
6	Control	2.1 ± 0.7

Table 1: Mean percentage of occluding dentinal tubules on the dentin surface.

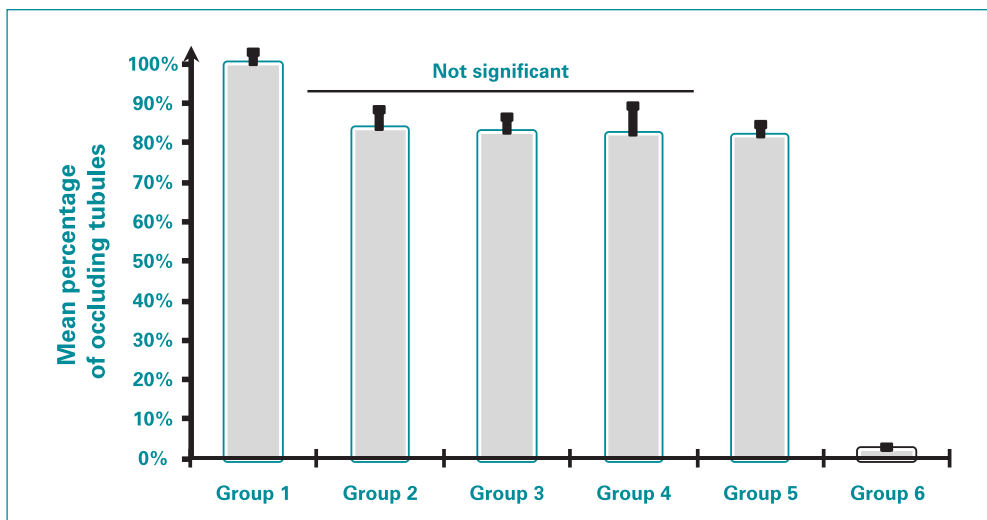


Fig. 1: Mean percentage of occluded dentinal tubules on the dentin surface in the different groups.

fices and the coronal access preparations were closed with zinc phosphate cement. All teeth were stored in 100% humidity at 37°C for 48h. A 3 mm wide ring of root surface, 2 mm apical to the coronal rim of each specimen was cut by a rotary instrument attached to a special microlathe to expose underlying dentin [10].

Treatment groups

The prepared teeth were randomly separated into six groups of ten teeth each:

- Group 1: The exposed dentinal tubules were treated with the combination of NFH and Nd:YAG laser (focus mode, wavelength of 1064 nm, 100 mJ, 100 Hz repetition rate) for 2 seconds.
- Group 2: The teeth were treated with Nd:YAG laser only (focus mode,

wavelength of 1064 nm, 100 mJ, 100 Hz repetition rate for 2 seconds.

- Group 3: The teeth were treated with NFH by applying a single layer on the surface of the exposed dentinal tubules.
- Group 4: The teeth were treated with a cyanoacrylate adhesive system (Tetric® N Ceram) by applying a single layer on the surface of the exposed dentinal tubules.
- Group 5: The teeth were treated with a single application of 2% sodium fluoride.
- Group 6: Control group.

Scanning electron microscope examination

The teeth were air-dried and mounted on aluminum stubs. After sputtering with a 40 nm layer of gold by using Balzers SCD 050 apparatus, wall surfaces of the treated samples were

examined using a scanning electron microscope (SEM) (5000x) operating at 10-15 kV. The surface topography of the dentine substrate was evaluated after treatment of all groups [11]. Photomicrographs were taken from each dentinal surface examined, approximately 100 µm above the gingival margin, at x 5000 magnification.

Statistical analyses

The primary outcome variable of the study was the percentage of occluded tubules obtained when dividing the total number of occluded tubules by the total number of tubules in each photomicrography.

Analysis of variance followed by Tukey post hoc test was conducted for comparison between groups. The level of significance was 0.05.




Fig. 2: Scanning electron micrograph of dentin after treatment with NFH and Nd:YAG laser (x 5000).




Fig. 3: Scanning electron micrograph of dentin surface treated with Nd:YAG laser (x 5000).




Fig. 4: Scanning electron micrograph of dentin surface treated with NFH (x 5000).




Fig. 5: Scanning electron micrograph of dentin surface treated with dentin adhesive system-Tetric® N Ceram (x 5000).




Fig.6: Scanning electron micrograph of dentin surface treated with sodium fluoride (x 5000).




Fig.7: Scanning electron micrograph of dentin surface in the absence of treatment (x 5000).

Results

A significant difference was found between the group 1 combining NFH and Nd:YAG laser and the others treatment modalities ($p < 0.05$); the per-

tage of the occluded tubules observed in this group was $99.8 \pm 3.3\%$.

Furthermore, no significant difference was found among groups 2 ($83.1 \pm 5.2\%$), 3 ($82.3 \pm 4.4\%$), 4 ($82.1 \pm 7.2\%$) and 5 ($81.4 \pm 3.5\%$) ($p > 0.05$) (Table 1, Fig. 1). These treatment modalities showed similar occluding effect on dentinal tubules.

Moreover, there were highly significant differences between the control group ($2.1 \pm 0.7\%$) and the other five groups. Scanning electron micrograph of specimens in group 1 showed many deposits in and around the orifices of the dentinal tubules and a recrystallization of the dentin substrate with NFH (Fig. 2). Group 2 showed partial deposits on the

dentinal surface; some orifices of dentinal tubules remained patent (Fig. 3). Group 3 showed deposition of NFH on the dentin surface but the dentinal tubules were not completely obliterated (Fig. 4). In group 4, a partial closure of some dentinal tubules was observed, others were still patent (Fig. 5). Also, in group 5, the dentinal tubules were not completely closed (Fig. 6). In the control group, the dentinal tubules looked open with some deposit of smear layer around the tubules orifices (Fig. 7).

Discussion

Dentine hypersensitivity refers to the transient and severe pain arising from stimulation of exposed dentine with cold, heat and mechanical pressure.

The increase in human life expectancy at the same time increases the lifetime of teeth in the mouth. Many diseases, including physiological wear, enamel hypoplasia, wedge-shaped defects, and gingival recession can lead to exposed dentine [22].

The prevalence of dentine hypersensitivity thus shows a clear upward trend all around the world. It was reported that the prevalence of dentine hypersensitivity was about 4–57 % in adults and that the prevalence reached up to 60–98 % in patients with periodontal diseases [23].

Numerous desensitizing agents have been tried and used in the history of dentistry to alleviate the pain from hypersensitive dentine.

The delivery mode of these desensitizing agents on the tooth surfaces can be in various forms such as dentifrices, gel, varnishes, tooth mousse and solutions which take longer time to act, and reduce the hypersensitivity only after multiple applications.

Most of the DH treatments aim to block exposed dentin tubules reducing dentine permeability, and reducing or preventing dentin fluid flow due to external stimulus [24].

The objective of the present study was to evaluate different agents used

in treating dentin hypersensitivity, as they can affect dentin permeability or cause dentinal tubule occlusion. To date, most of the therapies have failed to satisfy the patients.

In our study, occlusion of the dentinal tubules was obtained in all the experimental groups with varying degrees; the difference between these experimental groups and the control group was statistically significant.

Sodium fluoride solutions are very efficient in managing dentinal hypersensitivity [25]. Tal et al. [26] suggested that the probable desensitizing effects of fluoride are related to the precipitated fluoride compounds mechanically blocking the exposed dentinal tubules or the transmission of stimuli. In our study, and after a single application, 81.4% of the dentinal tubules were blocked.

Sealing of dentinal tubules with resins and adhesives (cyanoacrylate) has been advocated for many years in the management of dentinal hypersensitivity [27]. In our study, 82% of the tubules were sealed as shown in the SEM. However, problems arise when the adhesive breaks away resulting in tubules exposure. This technique is generally reserved for localized dentinal hypersensitivity rather than generalized dentinal pain [28].

The effect of Nd:YAG laser on DH can be related to the laser-induced occlusion or narrowing of the dentin tubules [29]. Direct nerve analgesia [30] and suppressive effect achieved by blocking the depolarization of Aδ and C fibers [31] are also considered to be the possible mechanisms by which Nd:YAG laser irradiation reduces DH. The occlusion of some dentinal tubules could be due to the recrystallization of dentin and bending of the inner walls of the tubules orifices to the inside direction [32]. Used alone, it caused the occlusion of 82.3% of the dentinal tubules. Because laser devices are still relatively costly, their use is limited [33].

Conclusion

The ideal desensitizing agent is yet not known. Study results are variable and certain agents work best in certain circumstances and with certain individuals.

Our study shows that the combination of NFH and Nd:YAG laser was an excellent method for closure of exposed dentinal tubules compared to other treatment modalities and could be a promising treatment modality for dentin hypersensitivity.

Hence, this *in vitro* study should be followed by prospective clinical studies to evaluate the long-term efficacy of NFH and Nd:YAG laser on the hypersensitivity of teeth compared to other classic treatment modalities.

References

- Addy EG, Addy M, Adams D. Dentin hypersensitivity: A study of the patency of dentinal tubules in sensitive and non-sensitive cervical dentin. *J Clin Periodontol* 1997;14:280-4.
- Bernick S. Innervation of the human tooth. *Anat Res* 1948;101:293-297.
- Frank RM. Attachment sites between the odontoblast process of the intradental nerve fiber. *Arch Oral Biol* 1968;13:833-834.
- Frank RM, Steuer P. Transmission electron microscopy of the human odontoblast process in peripheral root dentin. *Arch Oral Biol* 1988;31:91-98.
- Brannstrom M, Astrom A. The hydrodynamics of the dentine, its possible relationship to dentinal pain. *Int Dent J* 1972;22:219-227.
- Brannstrom M, Johnson G, Nordenvall KJ. Transmission and control of dental pain: resin impregnation for the desensitization of dentin. *J Am Dent Assoc* 1979;99:612-618.
- Hoang BT. Evaluation of a natural resin-based new material (Shellac F) as a potential desensitizing agent. *Dent Mater* 2008;24:1001-7.
- Bartold PM. Dentinal hypersensitivity: A review. *Australian Dent J* 2006;51:(3):212-218.
- Kleinberg K. Dentinal hypersensitivity. Part II. Treatment of sensitive dentin. *Compend Cont Educ* 1986;7:281.
- Javid B, Barkhordar RA, Bhinda SV. Cyanoacrylate — A new treatment for hypersensitive dentin and cementum. *J Am Dent Assoc* 1987;114:486-488.
- Kaplan M, Bozkurt S, Kut MS, Kullu S, Demirtas MM. Histopathological effects of ethyl 2-cyanoacrylate tissue adhesive following surgical application: An experimental study. *Eur J Cardiothorac Surg* 2004;25:167-172.
- Furseth R. A study of experimentally exposed and fluoride treated dental cementum in pigs. *Acta Odont Scand* 1970;28:833-850.
- Driessens FC. Mineral aspects of dentistry. *Monogr Oral Sci* 1982;10:1-215.
- LeGeros RZ. Calcium phosphates in oral biology and medicine. *Monogr Oral Sci* 1991;15: 1-201.
- Kim MS, Chae GJ, Choi SH, Chai JK, Kim CK, et al. Effect of hydroxyapatite containing dentifrice on teeth hypersensitivity after periodontal therapy. *J Korean Acad Periodontol* 2008;38:1-6.
- Kang SJ, Kwon YH, Park JB, Herr Y, Chung JH. The effects of hydroxyapatite toothpaste on tooth hypersensitivity. *J Korean Acad Periodontol* 2009;39: 9-16.
- Kim HW, Kong YM, Bae CJ, Noh YJ, Kim HE. Sol-gel derived fluor hydroxyapatite biocoatings on zirconia substrate. *Biomaterials* 2004;25:2919-2926.
- Chiang YC, Chen HJ, Liu HC, Kang SH, Lee BS, Lin FH, Lin PH and Lin CP. A novel mesoporous biomaterial for treating dentin hypersensitivity. *J Dent Res* 2010;89(3):236-40 .
- Matsumoto K, Funai H, Shirasuka T, Wakabayashi H. Effects of Nd: YAG- laser in treatment of cervical hypersensitive dentine. *J Conserv Dent* 1985;28:760-765.
- Lan WH, Lee BS, Liu HC, Lin CP. Morphologic study of Nd:YAG laser usage in treatment of dentinal hypersensitivity. *J Endod* 2004;30:131-134.
- Gutknecht N, Moritz A, Dercks HW, Lampert F. Treatment of hypersensitive teeth using neodymium:yttrium-aluminum-garnet lasers: A comparison of the use of various settings in an *in vivo* study. *J Clin Laser Med Surg* 1997;15:171-174.
- Parolia A, Kundabala M, Mohan M. Management of dentinal hypersensitivity: A review. *J Calif Dent Assoc* 2011;39:167-179.
- Cummins D. Recent advances in dentin hypersensitivity: Clinically proven treatments for instant and lasting sensitivity relief. *Am J Dent* 2010;23: 3A-13A.
- Jacobsen PL, Bruce G. Clinical dentin hypersensitivity: Understanding the causes and prescribing a treatment. *J Contemp Dent Pract* 2001;2:1-12.
- Kerns DG, Scheidt MJ, Pashley DH, Horner JA, Strong SL, Van Dyke TE. Dentinal tubule occlusion and root hypersensitivity. *J Periodontol* 1991;62:421-428.
- Tal M, Orion M, Gedalia I, Ehrlich J. X-ray diffraction and scanning electron microscope investigations of fluoride-treated dentine in man. *Arch Oral Biol* 1976;21:285-290.
- Brannstrom M, Johnson G. Effects of various conditioners and cleansing agents on prepared dentin surfaces. A scanning electron microscopic investigation. *J Prosthet Dent* 1974;31:422-426.
- Addy M, Dowell P. Dentine hypersensitivity – A review. Clinical and *in vitro* evaluation of treatments. *J Clin Periodontol* 1983;10:351-363.
- Lan WH, Liu HC. Treatment of dentin hypersensitivity by Nd: YAG laser. *J Clin Laser Med Surg*. 1996;14:89-92.
- Whitters CJ, Hall A, Creanor SL, Moseley H, Gilmour WH, Strang R, Saunders WP, Orchardson R. A clinical study of pulsed Nd: YAG laser-induced pulpal analgesia. *J Dent* 1995;23:145-150.
- Orchardson R, Gangarosa LP, Sr, Holland GR, Pashley DH, Trowbridge HO et al. Dentine hypersensitivity-into the 21st century. *Arch Oral Biol* 1994;39(Suppl):113S-119S.
- Tope WD, Kageyama N. "Hot" KTP-laser treatment of facial angiofibromata. *Lasers Surg Med* 2001;29:78-81.
- KimuraY, Wilder-SmithP, YonagaK, MatsumotoK. Treatment of dentine hypersensitivity by lasers: A review. *J Clin Periodontol* 2000;27:715-721.