

2020

FIELD CANCERIZATION IN SALIVARY TISSUE: AN IMMUNOHISTOCHEMICAL STUDY OF Mdm2 AND Bcl-2 IN HISTOLOGICALLY NORMAL TISSUE ADJACENT TO SALIVARY TUMORS

Essam Gaballah
Delta University for Science and technology

Follow this and additional works at: <https://digitalcommons.aaru.edu.jo/dusj>



Part of the [Medicine and Health Sciences Commons](#)

Recommended Citation

Gaballah, Essam (2020) "FIELD CANCERIZATION IN SALIVARY TISSUE: AN IMMUNOHISTOCHEMICAL STUDY OF Mdm2 AND Bcl-2 IN HISTOLOGICALLY NORMAL TISSUE ADJACENT TO SALIVARY TUMORS," *Delta University Scientific Journal*: Vol. 3 : No. 2 , Article 1.

Available at: <https://digitalcommons.aaru.edu.jo/dusj/vol3/iss2/1>

This Article is brought to you for free and open access by Arab Journals Platform. It has been accepted for inclusion in Delta University Scientific Journal by an authorized editor. The journal is hosted on [Digital Commons](#), an Elsevier platform. For more information, please contact rakan@aar.edu.jo, marah@aar.edu.jo, dr_ahmad@aar.edu.jo.



**FIELD CANCERIZATION IN SALIVARY TISSUE: AN
IMMUNOHISTOCHEMICAL STUDY OF Mdm2 AND Bcl-2 IN HISTOLOGICALLY
NORMAL TISSUE ADJACENT TO SALIVARY TUMORS**

Essam Gaballah

**Professor of Oral Pathology, Vice Dean for Postgraduate and Research Affairs, Faculty
of Dentistry, Delta University for Science and Technology**

Abstract

The present study was carried-out to investigate the concept of field cancerization in salivary tissue by an immunohistochemical detection of Mdm2 and Bcl-2 oncoproteins in histologically normal tissue adjacent to salivary tumors. Sections from 18 archival paraffin blocks of salivary gland carcinomas were processed to demonstrate the immunohistochemical expression of Mdm2 and Bcl-2 oncoproteins in peritumoral normal salivary tissue. Eight cases (44.4%) showed Mdm2 expression and another four cases (22.2%) showed Bcl-2 reactivity. A perfect positive correlation ($R=0.98$) between Mdm2 and Bcl-2 expression in normal salivary tissue around salivary tumors was reported in the present study. The findings of the present work suggests that, although the studied peritumoral salivary tissue appeared histologically normal, it revealed an immunohistochemical expression of anti-apoptotic oncoproteins which may signal the tumorigenesis of this tissue. These oncoproteins may be useful in the early detection, risk assessment, disease monitoring and chemoprevention of salivary gland tumors.

Introduction:

In their classical paper in 1953, Slaughter and colleagues ⁽¹⁾ used the term field cancerization for the first time when studying oral cancer. The authors did not provide a clear definition, but by performing extensive histological studies, a concept was proposed describing tissues covered by the field cancerization: (a) Oral cancer develops in multifocal areas of precancerous change ; (b) Abnormal tissue surrounds the tumor ;(c) oral cancer often consists of multiple independent lesions that sometimes coalesce ; and (d) the persistence of abnormal tissue after surgery ⁽²⁾.

Many recent studies have addressed the molecular basis of the process of cancer development and the genetic progression models have been proposed for various tumor types. It is now well established that an accumulation of genetic alterations forms the basis for the progression from a normal cell to a cancer cell, referred to as the process of multistep carcinogenesis ⁽³⁾. The process of field cancerization can be defined in molecular terms, and its position in the process of multistep carcinogenesis can be delineated ⁽²⁾. Organs in which field cancerization has been investigated are squamous cell carcinoma of the oral cavity, oropharynx and larynx ⁽⁴⁾, Lung ⁽⁵⁾, esophagus

(6), stomach (7), vulva (8), cervix (9), breast (10), skin (11), prostate (12), pancreas (13) and ovary (14).

Apoptosis is genetically programmed form of cell death, which primarily functions to eliminate senescent or altered cells that are useless or harmful for the multicellular organism. Aberrations of the apoptotic mechanisms that cause excessive or deficient programmed cell death have been linked to a wide array of pathologic conditions such as cancer, autoimmunity and various degenerative diseases (15).

Murine double minute (Mdm2) is a cellular proto-oncogene which in conditions of over expression or amplification is capable of inactivating the functions of P53, leading to tumorigenesis. In salivary gland tumors immunoexpression of Mdm2 was previously reported and was linked to rapid tumor progression and worse prognosis (16).

Bcl-2 (B- cell lymphoma / leukemia – 2) is an oncogene located on human chromosome 18q21 identified originally as a novel transcript associated with t (14;18) chromosomal breakpoint which occur in most follicular lymphomas. The protein is expressed also in a variety of other tissue. The over expression of Bcl-2 prevents death by apoptosis and counteracts apoptotic mechanisms. Bcl-2 was suggested to have a biological role in salivary gland tumor histogenesis (17).

To our knowledge , in the English language literature, no studies investigating field cancerization in salivary tissue were found, therefore the present study was-carried out to investigate the concept of field cancerization in salivary tissue by an immunohistochemical detection of Mdm2 and Bcl-2 proteins in histologically normal tissue adjacent to salivary tumors.

Materials and methods

Before the commitment of the present study, careful microscopical examination of hematoxylin and eosin stained sections of archival salivary gland carcinoma cases which were obtained from Cairo National Cancer Institute of Egypt (50 cases) and from General Pathology Department of Mansoura Faculty of Medicine in Egypt (15 cases). Out of these 65 cases, only 18 cases showed normal salivary tissue around tumor tissue. This normal tissue was selected according to the following criteria; (a) not involved within the tumor tissue; (b) absence of any invasion from the tumor cells to the surrounding normal tissue;(c) enough amount of normally appearing tissue must be present for histochemical study.

The paraffin blocks of these selected 18 cases were obtained, from each paraffin block two sections each of 5 microns thickness were cut, deparafinized and rehydrated in graded alcohols, then treated with blocking reagent for 5 minutes, washed in phosphate buffer working solution (PBS) for 5 minutes, one drop of monoclonal mouse primary antibody to Mdm2 and Bcl-2 (Dako A/S Copenhagen- Denmark) was placed on each of the sections respectively.

Negative controls were obtained by omitting the primary antibody of each of the two markers and replacing it with two to three drops of non- specific serum. Then slides were incubated overnight in a humidity chamber . Two to three drops of streptavidine enzyme were placed on each slide, then several drops of the working color reagent (DAB) were placed on each slide, slides were counterstained with Myer's hematoxylin, dehydrated and covers were mounted using Canada balsam.

For each of the slides, mean number of reactive cells per 5 high power fields (HPFs) was calculated. Statistical analysis was carried-out by tables and descriptive statistics (means and standard deviations). The SPSS 10 software was used for analysis and processing of data.

Results

Immunohistochemical expression of the studied oncoproteins was evident in 12 out of the studied 18 cases (66.6%), of these 12 cases, 8 cases were reactive to Mdm2 and the remaining 4 cases showed Bcl-2 expression (table 1).

a- Mdm2 findings

Mdm2 appeared in the present study as brownish diffuse cytoplasmic staining which was expressed only in ductal cells of the studied cases. Mdm2 expression was reported in the present study in 8 out of the studied 18 cases (44.4%), with 12.3 ± 2.1 positive cells / 5 HPFs (Figures 1 and 2).

b- Bcl-2 findings

Expression of Bcl-2 was seen in the basal layer of cells lining salivary ducts and in one of the studied cases, it was expressed in stromal lymphocytes. It was evident as a brownish nuclear staining with ring like distribution in the nuclei of ductal cells. The nuclear distribution of Bcl-2 expression was more diffuse in the surrounding lymphocytes. Only 4 (22.2%) out of the studied 18 cases showed Bcl-2 reactivity among their ductal cells, the number of positive cells per 5 HPFs was 11.1 ± 3.7 (Figures 2 and 3).

c- Correlation between mdm2 and Bcl-2 expression

Non of the cases of the present work revealed co-expression of both Bcl-2 and Mdm2. Meanwhile in all of the studied cases, only ductal cells of the were immunoreactive

to either Mdm2 or Bcl-2. No any other type of cells was reactive except some stromal lymphocytes in a single case stained with Bcl-2. Using Pearson correlation coefficient there was a perfect positive correlation between the expression of Mdm2 and Bcl-2 in the studied normal salivary tissue ($R = 0.98$).

Table1: Correlation between Mdm2 and Bcl-2 expression in the studied normal tissue around salivary tumors

Marker	Mdm2	Bcl-2
Number of reactive cases	8/18	4/18
Percentage of reactive cases	44.4	22.2
Mean number of reactive cells / 5HPFs \pm SD.	$12.3 \pm 2.1^*$	$11.1 \pm 3.7^*$

* = Perfect positive correlation ($R=0.98$)

HPFs = High power fields

SD. = Standered deviation

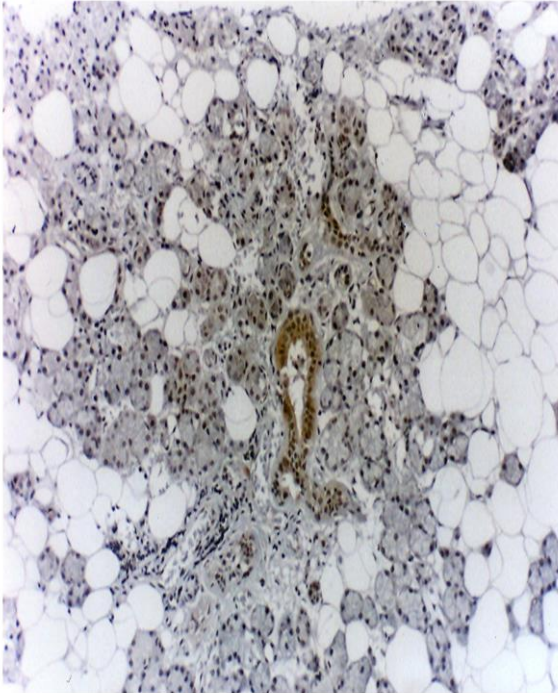


Figure1: Mdm2 expression in a duct within peritumoral normal salivary tissue (Anti-Mdm2, Original magnification X 40)

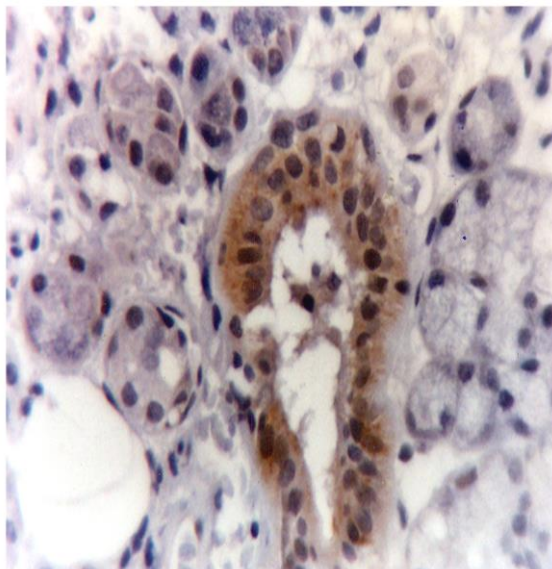


Figure2: Higher magnification of the previous field showing cytoplasmic Mdm2 expression in a salivary duct and absence of reactivity in the surrounding acini of normal peritumoral

salivary tissue (Anti-Mdm2 , Original magnification X 400).

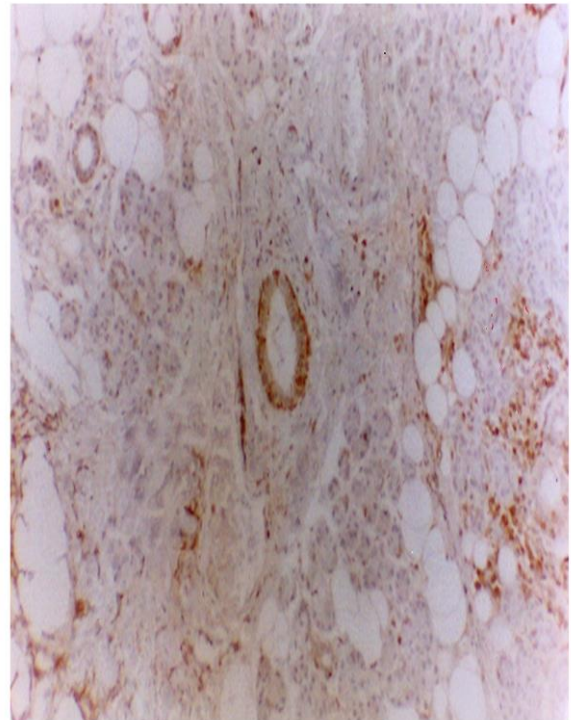


Figure3: Bcl-2 expression in normal salivary duct and in a group of lymphocytes in normal salivary tissue around a salivary tumor (Anti-Bcl-2 , Original magnification X 40).

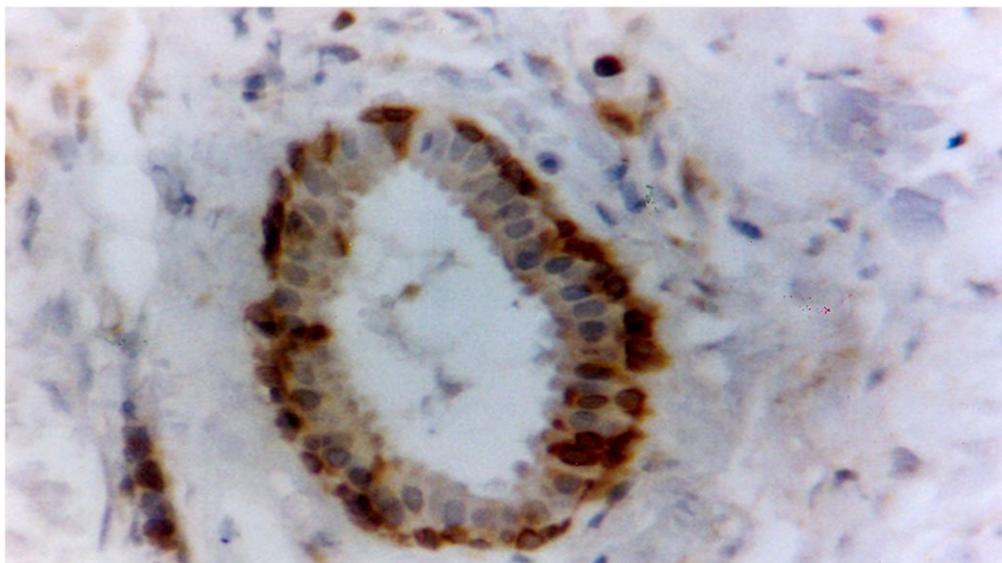


Figure4: Higher magnification of the previous section revealing ring like nuclear reaction of Bcl-2 in the basal layer of cells lining a salivary duct and more diffuse nuclear reaction in the surrounding lymphocytes (Anti-Bcl-2 , Original magnification X 400).

Discussion

Field cancerization is a well known and well documented process of malignant transformation. Several studies confirm the importance of this phenomenon in the tumor development, with technological advancement the future should benefit from well designed studies aimed at identifying genetic markers and pathways useful in disease management ⁽¹⁸⁾. Recent molecular and immunohistochemical studies have enabled detection of alterations in all genomic levels, numerous abnormalities have been demonstrated in both precancerous lesions and normal appearing cells close to tumors ^(19,20).

Although some investigators reported the presence of multifocal salivary gland tumors ^(21,22), nearly all previous studies have relied heavily on markers associated with a particular salivary gland tumors. In the English language literature we could not identify any researches investigating field cancerization in normal salivary tissue around

tumors. Only very scanty studies were found using salivary tissue around tumors as control. Therefore, in the present discussion comparisons were made to similar studies on other glandular organs, also to studies on salivary gland tumors in order to assess the concept of field cancerization in normal salivary tissues.

Over the last three decades, apoptosis has emerged as an important biological process involved in normal physiology and in the pathogenesis of a variety of disease especially tumors ⁽²³⁾. In multicellular organism, normal cells have a number of potent apoptotic mechanisms for elimination of cells damaged by a variety of stresses. It is therefore essential for cells to overcome cell death induced by these stresses for cancer to develop ⁽²⁴⁾. Thus, tumor cells evade apoptosis by inactivation of apoptosis inducing genes or by enhancement of the activity of anti apoptotic genes⁽²³⁾.

The findings of the present study yielded an immunohistochemical expression

of both Mdm2 and Bcl-2 in normal salivary tissue around salivary tumors in 66.6% of cases, which is a higher percentage than that reported in the glandular epithelial cells in normal breast lobules adjacent to cancer focus, where loss of heterozygosity was reported in eight (26.6%) out of thirty cases⁽²⁵⁾. Also it was higher than that reported in the study of Zawa and coworkers⁽²⁶⁾, as they reported K-ras expression in 16.7% in normal pancreatic epithelium and papillary hyperplasia of the pancreas.

Even in non glandular neoplasms, the immunohistochemical expression of Mdm2 and Bcl-2 in the present study was much higher, for example loss of heterozygosity was reported in 10 out of 28 cases (35.7%) of the studied tumor biopsy taken from macroscopically normal mucosa adjacent to the tumor⁽²⁷⁾. This variation in abnormalities in peritumoral tissue between the present study and those of other investigators may be due to either the difference in the nature of the tissue under study or may be due to different method of evaluating the genetic abnormalities or that Bcl-2 and Mdm2 may play a major role in the early stages of tumorigenesis of salivary gland tumors.

On the other hand, in the study of Carlinfante and colleagues⁽²⁸⁾ they reported high expression of Bcl-2 in 19 out of 21 adenoid cystic carcinoma cases (90%) where most tumor cells were immunoreactive, a relation to histologic types, clinical staging and survival was not found. Therefore, the high immunoreactivity against this oncoprotein in the studied tumor cells suggests that this oncogene may be involved since the early stage of carcinogenesis. Similarly, Andrea et al⁽¹⁶⁾ postulated that the over expression of Mdm2 is related to tumorigenesis of salivary gland tumors, they stated that the strong expression of Mdm2

may represent an alternative mechanism in the development of salivary gland tumors.

In the present study, Mdm2 reactivity was cytoplasmic which contradicts our previous study⁽²⁹⁾ where Mdm2 expression was mainly nuclear with few cases revealing cytoplasmic staining among the cells of polymorphous low grade adenocarcinoma cases. This difference in the site of intracellular Mdm2 expression may be due to a very early role of mdm2 in the process of tumorigenesis where it acts on the mitochondria, meanwhile, in more advanced stages of tumorigenesis its action may be nuclear. This concept may be explained on the basis of the central role of mitochondria as death regulator of the intrinsic apoptotic pathway in response to DNA damage, growth factor withdrawal, hypoxia or oncogenic deregulation and it is critical for P53 dependent cell death^(30,31) which is antagonized by Mdm2 leading to cessation of apoptosis and cell proliferation.

All the studied cases revealed only ductal expression of either Bcl-2 or Mdm2 with complete absence of acinar reactivity to either of the two markers used in the present study, these findings were similar to those of Kong and coworkers⁽³²⁾, who reported expression of Bcl-2 in control salivary gland ductal cells but not in acinar cells. Similarly, murine Bcl-2 was highly expressed in the gland ducts in the study of Actis and colleagues⁽³³⁾, they stated that since these proteins have been reported to play roles in maintaining homeostasis via control of cell growth, their analysis in normal salivary tissue will hopefully contribute to the study of salivary gland tumorigenesis. The reported high value of standard deviation (3.7) for mean number of Bcl-2 reactive cells/5 HPFs in the present study appear to be due to low number of reactive cases (4/18).

The immunohistochemical expression of Mdm2 and Bcl-2 proteins in ductal cells of the studied normal salivary tissue in the present study may signal a major histogenetic role of ductal cells as an origin for the development of salivary gland tumors, moreover, the expression of Bcl-2 in the basal layer of ductal cells may be due to the role of these cells as an origin to salivary tumors a point which need further investigations to be confirmed.

The findings of the present study suggest an important role of anti-apoptotic oncoproteins in the early development and carcinogenesis of salivary gland tumors. These findings are further supported by those of Hong-Fang et al ⁽³⁴⁾, who reported higher expression of Bcl-2 in grade I mucoepidermoid carcinoma cases than in grades II and III tumors; they proposed that this may be due to Bcl-2 role in the early stages of tumorigenesis. Moreover, Soini and co workers ⁽³⁵⁾ reported strong immunohistochemical expression of Bcl-2 in pleomorphic adenoma and Warthin's tumor cases, meanwhile, the malignant tumors in their study yielded a very weak Bcl-2 expression which further supports the findings of the present study. Similarly, several recent studies yielded evident Mdm2 reactivity in many types of salivary tumors ^(36, 37, 38 and 39) which further supports the importance of the novel Mdm2 in tumorigenesis of normal salivary tissue.

Non of the cases of the present study revealed co - expression of both Bcl-2 and mdm2 , instead, out of the 12 reactive cases , 4 cases were Bcl-2 positive and the remaining 8 cases showed Mdm2 expression. Therefore, the findings of the present study suggests that both Bcl-2 and Mdm2 share the process of salivary gland tumorigenesis but in different

stages of the process of multistep tumorigenesis or , on the other hand, as Gross and colleagues ⁽⁴⁰⁾ suggested that the apoptotic process occurs in three interdependent phases: induction, decision and execution. Therefore, each one of the studied oncoproteins may stop the apoptotic process at different stage, thus, not expressed simultaneously.

Conclusion

From the findings of the present study it can be concluded that normal salivary tissue around salivary tumors revealed abundant expression of an anti apoptotic oncoproteins which signal that this tissue may progress to salivary tumor. Moreover, currently biopsies for cancer diagnosis are reviewed by histology; the absence of abnormal cells often precludes the diagnosis of cancer. However, histologically normal biopsy specimen those posses' molecular signatures of cancer fields suggest either the tumor was missed by the biopsy procedure or that some cells in the tissue are progressing towards malignancy. Such high risk patients will require close surveillance for early cancer detection, a similar suggestion was proposed by Dakubo and co workers ⁽¹⁸⁾.

Another important message from the above work is that using histologically normal appearing samples as the sole control tissue in cancer research is probably inappropriate, instead the use of normal salivary gland tissue from an autopsy samples (if available) may be more appropriate⁽⁴¹⁾. Therefore, if the normal tissue adjacent to tumor tissue must be used as the only normal control, it should first be examined for the absence of genetic abnormalities ⁽⁴²⁾.

The findings of the present work may suggest that future biomarkers discovery and

validation efforts should focus on identification of biosensors that signal the genesis of the disease, rather than biomarkers of the disease itself. Such biosensors will be useful in risk assessment, early detection, disease monitoring and chemoprevention.

References

- 1- Slaughter D.P., Southwick H.W. and Smejkal W. "Field cancerization" in oral stratified squamous epithelium. *Cancer*, 1953; 6:963-967. Quoted from Braakhuis B.J.M., Tabor M.P., Kummer J.A., Leemans C.R. and Brakenhoff R.H. A genetic explanation of field cancerization: evidence and clinical implications. *Cancer Research*, 2003; 63:1727-1730.
- 2- Braakhuis B.J.M., Tabor M.P., Kummer J.A., Leemans C.R. and Brakenhoff R.H. A genetic explanation of field cancerization: evidence and clinical implications. *Cancer Research*, 2003; 63:1727-1730.
- 3- Fearon E.R. and Vogelstein B. A genetic model for colorectal tumorigenesis. *Cell*, 1990; 61:759-767.
- 4- Copper M.p., Braakhuis B.J., De Vries N., Van Dongen G.A., Nauta J.J. and Snow G.B. A panel of biomarkers of carcinogenesis of the upper aerodigestive tract as potential intermediate endpoints in chemoprevention trials. *Cancer*, 1993; 71:825-830.
- 5- Franklin W. A., Gazdar A.F., Haney J., Wistuba I.I., La Rosa F.G., Kennedy T., Ritchey D. and Miller Y.E. Widely dispersed P53 mutation in respiratory epithelium. A novel mechanism for field carcinogenesis. *J. Clin. Invest.* 1997; 100:2133-2137.
- 6- Prevo L.J., Sanchez C.A., Galipeau P.C. and Reid B.J. P53- mutant clones and field effects in Barrett's Esophagus. *Cancer*, 1999; 59:4748-4787.
- 7- Kim S.K., Jang H.R., Kim J.H., Noh S.m., Song K.s., Kim M.R., Kim S.Y., Yeom Y.I., Kim N.S., Yoo H.S., and Kim Y.S. The epigenetic silencing of LIMS2 in gastric cancer and its inhibitory effect on cell migration. *Biochem Biophys Res Commun.* 2006; 34:1032-1040.
- 8- Rosenthal A.N., Ryan A., Hopster D. and Jacobs I.J. Molecular evidence of a common clonal origin and subsequent divergent clonal evolution in vulval intraepithelial neoplasia, vulval squamous cell carcinoma and lymph node metastasis. *Int. J. Cancer*, 2002; 99:549-554.
- 9- Chu T.Y., Shen C.Y., Lee H.s. and Liu H.s. Monoclonality and surface lesion – specific microsatellite alterations in premalignant and malignant neoplasia of uterine cervix. A clonal field effect of genomic instability and clonal evolution. *Genes Chromosomes Cancer*, 1999; 24:127-134.
- 10- Frosti A., Louhelainen J., Soderberg M., Wijkstrom H. and Hemminiki K. Loss of heterozygosity in tumor adjacent normal tissue of breast and bladder cancer. *Eur. J. Cancer*, 2001; 37:1372-1380.
- 11- Stem R.S., Bolshakov S., Nataraj A.J., and Ananthaswamy H.N. P53 mutation in non-melanoma skin cancers occurring in psoralen

- ultraviolet α - treated patients. Evidence for heterogeneity and field cancerization. *J. Investig. Dermatol.* 2002; 119:522-526.
- 12- Hanson J.A., Gillespie J.W., Grover A., Tangrea M.A., Chuaqui R.F., Emmert-Buck M.R., Tangrea J.A., Libutti S.K., Linehan W.M. and Woodson K.G. Gene promoter methylation in prostate tumor-associated stromal cells. *J Natl Cancer Inst.* 2006; 98:255-261.
- 13- Kitago M., Ueda M., Aiura K., Suzuki K., Hoshimoto S., Takahashi S., Mukai M. and Kitajima M. Comparison of K-ras point mutation distributions in intraductal papillary-mucinous tumors and ductal adenocarcinoma of the pancreas. *Int J Cancer.* 2004; 110:177-182.
- 14- Furlan D., Carnevali I., Marcomini B./ Cerutti R., Dainese E., Capella C. and Riva C. The high frequency of de novo promoter methylation in synchronous primary endometrial and ovarian carcinomas. *Clin Cancer Res.* 2006; 12: 3329- 3336.
- 15- Nikolas N.G., John S.j. and Stavros I.p. The role of apoptosis in oral disease: Mechanisms, aberrations in neoplastic, autoimmune, infectious, hematologic and developmental disease; and therapeutic opportunities. *Oral Surgery, Oral Medicine, Oral Pathology, Oral Radiology & Endodontics.* 2004; 97 (4):476-490.
- 16- Andrea M., Lourenco S.V., Israel B., Bernardo G., Daumas N.F. and Vera Cavalcanti D. Mdm2 mRNA expression in salivary gland tumor cell lines. *Journal of Oral Pathology and Medicine.* 2004; 33(2): 96-101.
- 17- Nagler R.M., Kerner H., Ben-Eliezer S., Minkov I. and Ben – Itzhak O. Prognostic role of apoptotic Bcl-2, c-erb B2 and P53 tumor markers in salivary gland tumor malignancies. *Oncology.* 2003; 64:389-398.
- 18- Dakubo G.D., Jakupciak J.P., Brich-Machin M. and Parr R.L. Clinical implications and utility of field cancerization. *Cancer Cell Int.* 2007; 7:2-9.
- 19- Sui G., Zhou S., Wang J., Canto M., Lee E.E., Eshlema I.R., Montgomery E.A., Sidransky D., Califano J.A and Maitra A. Mitochondrial DNA mutations in Preneoplastic lesions of the gastro intestinal tract : A biomarker for the early detection of cancer. *Mol Cancer.* 2006; 5:73-39.
- 20- Heaphy C.M., Bisoffi M., Fordyce C.A., Haaland C.M., Hines W. C., Joste N.E. and Griffith J.K. Telomerase DNA content and allelic imbalance demonstrate field cancerization in histologically normal tissue adjacent to breast tumors. *Int J Cancer.* 2006; 119:108-116.
- 21- Rousseau A., Mock D., Dover D.G. and Jordan P.C.K. Multiple canalicular adenomas: A case report and review of the literature. *Oral Surgery, Oral Medicine, Oral Pathology, Oral Radiology & Endodontics.* 1999; 87(3): 346-350.
- 22- Johns M.E., Shikhani A.H., Kashima H.K. and Matanosk G.M. Multiple primary neoplasms in patients with salivary gland or thyroid gland tumors. *Laryngoscope.* 1986; 96(7): 718-721.
- 23- Loro L.L., Vintermyr O.K. and Johannessen A.C. Review article: Apoptosis in normal and diseased oral

- tissues. *Oral Diseases*. 2005;11: 274-287.
- 24- Hoeijmakers J.H. Genome maintenance mechanisms for preventing cancer. *Nature*. 2001; 411: 366-374.
- 25- Deng G., Lu Y., Zlotnikov G., Thor A.D. and Smith H.S. Loss of Heterozygosity in normal tissue adjacent to breast carcinomas. *Science*. 1996; 274: 2057- 2059.
- 26- Izawa T., Obara T., Tanno S., Mizukami Y., Yanagawa N. and Kohgo Y. Clonality and field cancerization in intraductal papillary - mucinous tumors of the pancreas. *Cancer*. 2001; 92: 1807-1817.
- 27- Tabor M.P., Brakenhoff R. H., van Houten V. M. M., Kummer J. A., Snel M. H. J., Snijders P. F. G., Snow G. B., Leemans C. R. and Braakhuis B. J. M. Persistence of genetically altered fields in head and neck cancer patients : Biological and clinical implications. *Clin Cancer Res*. 2001;7: 1523-1532.
- 28- Carlinfante G., Lazzavetti M, Ferrari S. and Bianchi B.C.P. P53, Bcl-2 and Ki-67 expression in adenoid cystic carcinoma of the palate. A clinico – pathologic study of 21 cases with long term follow – up. *Pathology – Research and Practice*. 2005; 200: 791-799.
- 29- Gaballah E.T.M.A.,and Zedan W. Immunohistochemical expression of Mdm2 in polymorphous low grade adenocarcinoma (PLGA) of salivary glands. *Egyptian Dental Journal*. 2006; 52(2):1243.
- 30- Mihara M., Ester s., Zaika O., Petrenko O., Chittenden T., Pancosa P. and moll U. M. p53 has a direct apoptogenic role at the mitochondria. *Mol. Cell*. 2003; 11: 577-590.
- 31- Desai B., Myers B. and Schreiber S. FKBP12- rapamycin associated protein associates with mitochondria and senses osmotic stress via mitochondrial dysfunction. *Proc. Natl. Acad. Sci. USA*. 2002; 99: 4319-4324.
- 32- Kong L., Ogawa N., Mc Guff H.S., Nakabayashi T., Sakata K., Masago R., Vela- Roch N., Talal N. and Dang H. Bcl-2 family expression in salivary glands from patients with primary Sjogrens syndrome: Involvement of Bax in salivary gland destruction. *Clinical Immunology and Immunopathology*. 1998; 88(2):133-141.
- 33- Actis A.B., Lampe P.D. and Eynard A.R. Cellular basis and clinical implications of biological markers in salivary tissues: their topological distribution in murine submandibular gland. *Oral Oncology*. 2002;38(5): 441-449.
- 34- Hong-fang Y., Norihiko O. and Minoru T. Apoptosis and apoptotic-related factors in mucoepidermoid carcinoma of the oral minor salivary glands. *Pathology International*. 2000; 50(8): 603-609.
- 35- Soini I., Torman L. and Paakk O. Apoptosis is inversely related to bcl-2 but not to bax expression in salivary gland tumors. *Histopathology*. 2001; 32(1):38-34.
- 36- Schlott T.,Nagel H., Laskawi R., Eiffert H. and Droese M. Genetic analysis of the human oncoprotein Mdm2 in benign and malignant tumors of the salivary gland. *Pathobiology*. 2001;69:67-76.

- 37- Marques Y.M., de Lima M.D., de Melo Alves Sde s.jr., Soares F.A., de Araujo V.C., Pinto D. S. jr and Mantesso A. Mdm2, P53, P21 and pAKT protein pathways in neoplasms of the salivary gland. *Oral Oncol.* 2008; 44(9): 903-908.
- 38- Thom e Capuano A.C., Dos Santos P.J.D., Cavallhosa A.A. and de Araujo VC. Immuno-profile of carcinosarcoma of the submandibular gland. *Oral Surg. Oral Med. Oral Pathol. Oral Radiol and Endodontics.* 2007; 103(3):398-402.
- 39- Kishi m., Nakamura M., Nishimine M., Kirita T. and Konishi N. genetic and epigenetic alteration profiles for multiple genes in salivary gland carcinomas. *Oral Oncol.* 2005; 41(2):161-169.
- 40- Gross A., Mc Donnell J. and Korsmeyer J. Bcl-2 family members and the mitochondria in apoptosis. *Gene Dev.* 1999; 13:1899-1911.
- 41- Dayan D., Vered M., Sivor S., Hiss Y. and Buchner A. Age-related changes in proliferative markers in labial salivary glands: a study of argyrophilic nucleolar organizer regions (Ag NORs) and Ki-67. *Experimental Gerontology.* 2002; 37:841-850.
- 42- Braakhuis B.J., Leemans C.R. and Brakenhoff R.H. Using tissue adjacent to carcinoma as a normal control: an obvious but questionable practice. *J Pathol.* 2004; 203:620-621.