

10-19-2012

Ewing's sarcoma of the mandible: A case report

Bhandarkar GOWRI PANDARINATH

Shetty HOBEICHE

Follow this and additional works at: <https://digitalcommons.aaru.edu.jo/iajd>

Recommended Citation

GOWRI PANDARINATH, Bhandarkar and HOBEICHE, Shetty (2012) "Ewing's sarcoma of the mandible: A case report," *International Arab Journal of Dentistry*. Vol. 3: Iss. 3, Article 5.

Available at: <https://digitalcommons.aaru.edu.jo/iajd/vol3/iss3/5>

This Scientific Article (Research Note) is brought to you for free and open access by Arab Journals Platform. It has been accepted for inclusion in International Arab Journal of Dentistry by an authorized editor. The journal is hosted on [Digital Commons](#), an Elsevier platform. For more information, please contact rakan@aar.edu.jo, marah@aar.edu.jo, u.murad@aar.edu.jo.

EWING'S SARCOMA OF THE MANDIBLE: A CASE REPORT

Bhandarkar Gowri Pandarinath* | Shetty Kushal**

Abstract

Ewing's sarcoma of the jaw is a primitive malignant tumor of the bone. It is commonly seen in children and adolescents. Its occurrence in the head and neck region is unusual and generally involves most frequently the mandible rather than the maxilla. The present case discuss the clinical, diagnostic (radiographic, histopathologic) and therapeutic findings of an ES of the mandible in a 14-year-old boy. Early detection of such lesions is difficult because the signs and the symptoms do not appear until the lesion has progressed considerably. This case elucidates the importance of professional knowledge of the relevant aspects of malignant lesions such as Ewing's sarcoma.

Keywords: Ewing's sarcoma – mandible – diagnosis – immunohistochemistry.

IAJD 2012;3(3):104-107.

SARCOMA D'EWING AU NIVEAU DE LA MANDIBULE: À PROPOS D'UN CAS

Résumé

Le sarcome d'Ewing de la mâchoire est une tumeur rare primitive et maligne de l'os. Il est communément observé chez les enfants et les adolescents. Sa survenue au niveau de la région de la tête et du cou est inhabituelle et implique plus souvent la mandibule que le maxillaire. Le cas présenté siège à la mandibule chez un garçon de 14 ans; les éléments cliniques, diagnostiques (radiographie, histopathologie) et thérapeutiques sont développés et discutés. La détection précoce de ces lésions est difficile car les signes et les symptômes n'apparaissent que tardivement, après une progression considérable de la lésion. Ce cas révèle l'importance d'une bonne connaissance des particularités des lésions malignes en général et du sarcome d'Ewing en particulier.

Mots-clés: sarcome d'Ewing – mandibule – diagnostic - immunohistochimie.

IAJD 2012;3(3):104-107.

* MDS, Oral Medicine,
Reader,
A.J. Institute of Dental Sciences,
Rajiv Gandhi University of Health Sciences, India
renuka.bhandari@rediffmail.com

** MDS, Professor,
Dpt of Pedodontics
A.J. Institute of Dental Sciences,
Rajiv Gandhi University of Health Sciences,
India

Introduction

Ewing's sarcoma (ES) was originally described by James Ewing in 1921 as arising from undifferentiated osseous mesenchymal cells. Ewing stated that the tumor was not associated with any form of myeloma or osteogenic sarcoma and he thus termed it a "round cell sarcoma". However, recent studies suggest that Ewing's tumor might be neuro-ectodermally derived from various degrees of differentiation of the primitive neural tissues. Clinically, this tumor has aggressive behaviour,

characterized by rapid growth and high probability of micrometastasis.

Approximately 80% of cases occur in the first 2 decades of life [1] with a 2:1 male to female ratio. The majority of the patients affected are between 5 and 20 years whereas it is rarely seen before the age of 5 and after the age of 30 years. It exhibits a marked predilection for Whites and is rarely seen among Blacks. These lesions account for 4-15% of all primary bone tumors [2] and 1% of all malignant tumors in children. 2/3 of all cases appear in the lower skeleton [3] with a predisposition for long bones of the extremities

and the pelvis; the involvement of facial skeleton is very rare (3%) [2], the mandible being the most commonly affected bone [4, 5].

Case Report

A 14-year-old boy visited the Department of Oral Medicine and Radiology at Bangalore Institute of Dental Sciences, Bangalore, with a chief complaint of a 6 months' history of a painful, rapid, progressively enlarging swelling in the right mandible associated with relapsing fever at night. On clinical examination, the

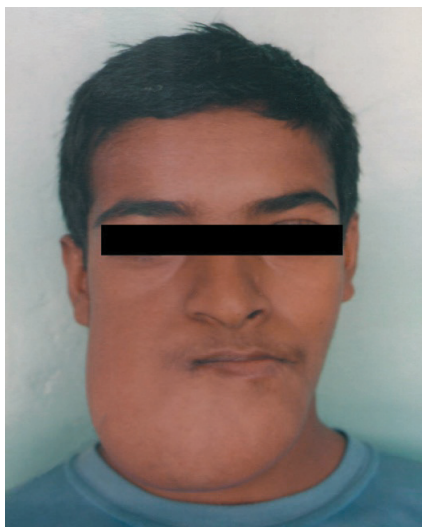

Fig. 1a: Tumor of right mandible crossing the midline to involve left parasymphysis
Fig. 1b: Tumor mass extending from right retromolar area with displacement of teeth.

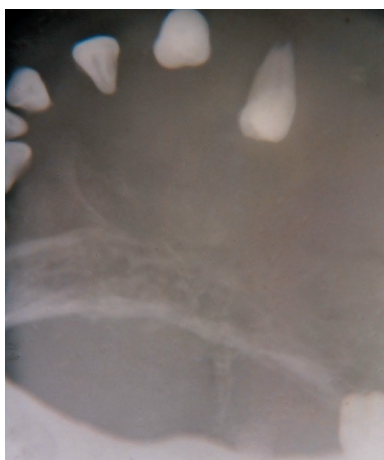
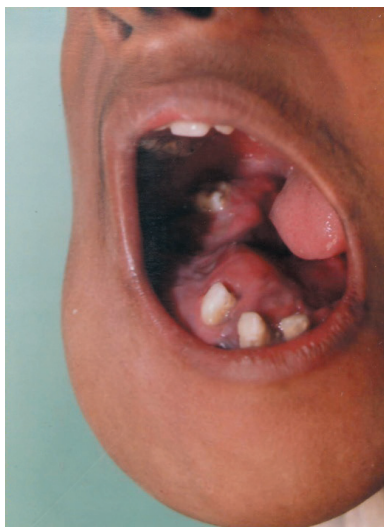

Fig. 2: Occlusal radiograph showing labially displaced anterior teeth giving floating teeth appearance.

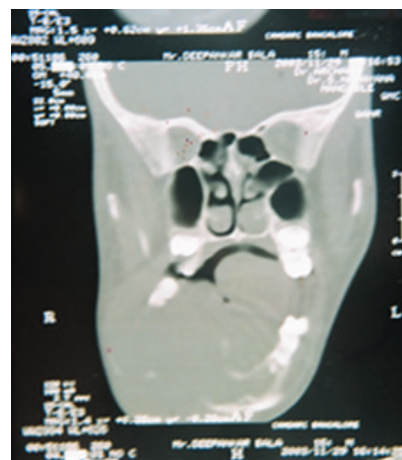

Fig. 3: The CT scan of the mandible revealed the osteolytic lesion eroding the right side.

patient was unable to close the mouth with paresthesia of the lower 1/3rd of the right side of the face (V3). Extra-orally, the right side of the face was grotesquely deformed with a diffuse, hard fixed, expansive mass (Fig. 1a). The tumor was extending superiorly up to 2 cm below the ala-tragus line and inferiorly below the inferior border of the mandible involving the submandibular region. Anteriorly, the tumor was extending up to the midline, crossing it and reaching the opposite side of the mandible up to the left parasymphyseal region. Posteriorly it extended to the right angle of the mandible. Overlying skin was distended and slightly erythematous. The tumor was hard to firm in consistency.

Intra-oral examination revealed an expansile mass growing mainly against the vestibular plate of the mandible, infiltrating the gingiva and the floor of the mouth. It was extending from the right retromolar area to the left mandibular premolars (Fig. 1b). The tumor was submucosal, and obstructing occlusion of the dental arch with displacement of the tongue to the left. The overlying mucosa was distended and erythematous. Ulceration was noted in posterior areas. On palpation, the swelling was non-tender and hard to firm in consistency. Bidigital palpation revealed expansion of the buccal cortical plate and perforation of buccal and lingual cortex. Grade II mobility and negative sensibility were

seen in the teeth from right mandibular second molars to left mandibular lateral incisor. No significant palpable lymph nodes were found in the neck. Chest radiograph revealed no abnormal findings. Mandibular occlusal radiograph showed poorly demarcated destructive lesion with labially displaced anterior teeth (floating teeth appearance) and eroded buccal and lingual cortical plates (Fig. 2). CT scan of the mandible revealed osteolytic lesion eroding the mandibular bone on its right side (Fig. 3).

Given the clinical and radiographic findings, the differential diagnosis included Ewing's sarcoma, osteogenic sarcoma, rhabdomyosarcoma,

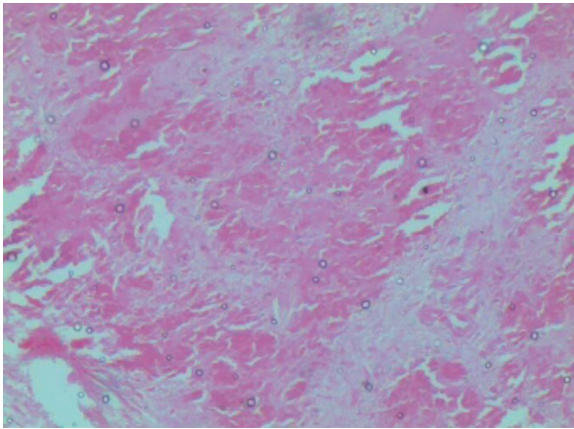


Fig. 4: The tumour cells arranged in diffuse sheets and trabeculae separated by fibroconnective septa. The tumor cells were round with round nuclei, basophilic nucleoli and granular cytoplasm.

Hodgkin's lymphoma, non-Hodgkin's lymphoma and metastatic diseases.

Haematological and biochemical investigations were within normal limits except for thrombocytosis and increased alkaline phosphatase levels. Haematopathologic report of bone marrow revealed no involvement of marrow.

Under local anaesthesia, patient underwent an incisional biopsy. On histopathological microscopic examination, H and E stained sections showed two bits of infiltrating tumor tissue with the tumor cells arranged in diffuse sheets and trabeculae separated by fibroconnective septa. The tumor cells were predominantly round with round nuclei, basophilic nucleoli and granular cytoplasm. Few hyperchromatic cells with scanty cytoplasm were also seen (Fig. 4). PAS stain was negative for glycogen.

Immunohistochemistry was done and the report revealed CK-focal positive; CD20, CD3 and tdt and MPO were negative. Desmin, Chromogranin and Synaptophysin were also negative. Mic2 showed membrane positivity. These findings were consistent with Ewing's sarcoma of the mandible. Cytogenetics was suggested and their report revealed 46, XY, t(11,22) (q24, q12). Other immunomarkers were all negative. Histopathological, immunohistochemical and cytogenetical findings supported the diagnosis of ES. The patient started a protocol consisting of antineoplastic agents: Vincristin

and Endoxan. After 2 months, the patient underwent surgery with wide resection of the affected area. Viable tumor was present in the resected mandible and all margins were negative. Histopathologic report confirmed the diagnosis of Ewing's sarcoma. After the operation, the patient's chemotherapy protocol was continued for 4 months. The patient was lost for follow-up.

Discussion

James Ewing first described Ewing's sarcoma (ES) in 1921, after observing radiosensitivity in a subgroup of bone tumors. Ewing's sarcoma is the second most common primary malignant tumor of the bone in children and adolescents [2]. The site of predilection is mostly the posterior regions with a 4:1 ratio compared to anterior regions [3]. In the head and neck region, there are non-specific clinical findings for ES; most of the patient's complaints at time of presentation are due to the mass effect of the tumor, its rapid growth, the swelling of the affected area and the pain sensation. When this tumor arises in the mandible, other signs and symptoms such as loosening of the teeth, otitis and paraesthesia may be observed. Systemic symptoms such as fever, often remittent about 38 °C, weight loss and anemia can be also noticed.

Ewing's sarcoma is a poorly differentiated neuroectodermal tumor with

small, round and blue cells [6]. More than 90% of cases show a characteristic translocation t(11;22) (q24;q12) resulting in the fusion of the EWS and FLI-1 genes [7]. This gene rearrangement causes a fusion product which functions as an oncogenic aberrant transcription factor with structural variability and potentially prognostic impact. Immunoreactivity against FLI 1 and CD99 can confirm the diagnosis [6].

The present case exhibited clinical aspects similar to those reported in the literature for cases in the head and neck region: it was located in the mandible, displayed a rapidly progressive growth and was accompanied by pain and fever. This presentation is not specific, but it demands complementary exams that can avoid large errors in the diagnosis.

Radiographically, the lesion is poorly defined, permeative, osteolytic and may be frequently associated with cortical erosion. This aspect is not a pathognomonic feature, as other lesions can have the same image pattern such as osteogenic sarcoma, neuroblastoma, lymphosarcoma, histiocytosis X, rhabdomyosarcoma, pyogenic osteomyelitis and metastatic carcinoma [3]. The presence of "sun-ray" spicules of periosteal bone and displacement or destruction of unerupted tooth follicles have been described as the commonest radiological features for ES affecting jaw bones. But some authors reported an occasional "sun-ray" appearance [5, 8]. Further, the presence of the lamellar periosteal response (known as "onion skin" reaction), pointed out by many authors as a common radiological feature of ES of the long bones, is rarely seen in the jaw lesions [9]. In our case, neither "sun-ray" spicules of periosteal bone nor an "onion skin" reaction of cortical bone were observed. The osteolytic lesion was associated with severe cortical erosion of the mandible.

Histologically, ES is composed of small nucleoli and scanty cytoplasm. The intra-cytoplasmic glycogen may be demonstrated by PAS stain in 75% of the cases. Biopsy is necessary to

make a definitive diagnosis and the tumor must be distinguished from microscopically similar tumors and conditions such as eosinophilic granuloma, malignant lymphoma, metastatic neuroblastoma and rhabdomyosarcoma [10]. Recent advances in electron microscopy, immunohistochemical, cytogenetic and molecular genetic techniques have increased the accuracy of a differential diagnosis of Ewing's sarcoma. In our case, the use of immunohistochemistry and cytogenetics helped in the diagnosis of this tumor. In general, the tumor cells are positive for Vimentin and CD99 and negative for neural, skeletal, vascular and lymphoid cell markers. Regarding Mic2 antigen, recently published data have confirmed the high sensitivity of the Mic2 gene product (CD99) for all ES family tumors with over 95% of the cases showing positivity for this marker. In fact, the expression of CD99 protein is not conclusive to ES because other round cell tumors, such as Merkel cell carcinoma, small cell osteosarcoma, T-lymphoblastic lymphoma and poorly differentiated synovial sarcoma may express this marker. It has been reported that combined therapy including surgery, radiothe-

rapy and chemotherapy is the best approach for ES. The treatment should include wide surgical resection and neoadjuvant chemotherapy [6]. The multidisciplinary treatment protocols have dramatically improved the 5-year survival rate of patients with ES from less than 16% to more than 75% of cases. Radiotherapy alone must be undertaken only to treat non-resectable primary tumor or as an neoadjuvant therapy; chemotherapy alone also helps suppressing potential micrometastasis and reducing the size of the tumor prior to surgery. Radiotherapy in doses greater than 4,000 cGy has been effective in short-term control of tumor growth in about 86% of cases [11]. The chemotherapeutic agents most commonly used are Vincristine, Doxorubicine, Cyclophosphamide, Ifosfamide and Actinomycin-D. Metastatic workup of Ewing's sarcoma of the mandible should include a chest computed tomography scan, bone marrow aspirate and bone scan. Ewing's sarcoma is viewed as a systemic disease even when it is clinically localized and current chemotherapy regimens reflect this attitude [1]. Major prognostic factors include the tumor site and its volume as well as

the presence of metastases. Tumors arising in the jaw bones have better prognosis than those located in long bones. Younger children have better event-free survival than older adolescents and young adults [12]. Clinical features such as systemic symptoms (fever, anaemia), high erythrocyte sedimentation rate, thrombocytosis and elevated serum lactate dehydrogenase levels are related to poor prognosis. Increased serum lactate dehydrogenase levels prior to treatment correlate with metastatic disease and shorter disease-free survival [13].

Conclusion

The prognosis of ES is poor because haematogenous spread and lung metastasis can occur within few months after diagnosis. The clinical signs and symptoms of Ewing's sarcoma appear when the tumor is in an advanced stage, which limits treatment options and prognosis. Recently chemotherapy and radiotherapy have dramatically improved long-term survival rates. Surgery is justified only if tumor control and preservation of function are guaranteed.

References

- Berk R, Hellar A, Heller D, Schwartz S and Klein EA. Ewing's sarcoma of the mandible. *Oral Surg Oral Med Oral Pathol Oral Radiol Endod* 1995;79:159-162.
- Wang C, Yacobi R, Pharoah M, Thorner P. Ewing's sarcoma metastatic tumor to the jaw. *Oral Surg Oral Med Oral Pathol* 1991;71:597-602.
- Wood R, Nortje C, Heseling P, Med C, Grotepass F. Ewing's tumor of the jaw. *Oral Surg Oral Med Oral Pathol* 1990;69:120-7.
- Talesh T, Motamedi M, Jeihounian M. Ewing's sarcoma of the mandibular condyle: report of a case. *J Oral Maxillofac Surg* 2003;61:1216-1219.
- Potdar G. Ewing's sarcoma of the jaws. *Oral Surg Oral Med Oral Pathol* 1970;29:505-12.
- Solomon L, Frustino J, Loree T, Brecher M, Alberico R, Sullivan M. Ewing's sarcoma of the mandibular condyle: Multidisciplinary management optimizes outcome. *Head Neck* 2008; 30:405-410, Wiley InterScience VVC 2007 Wiley Periodicals, Inc.
- Gosau M, Baumhoer D, Ihrler S, Kleinheinz J and Driemel O. Ewing's sarcoma of the mandible mimicking an odontogenic abscess – a case report. *Head & Face Medicine* 2008;4:24.
- Rapoport A, Sobrinho J, Carvalho M, Magrin J, Quadros J. Costa FQ. Ewing's sarcoma of the mandible. *Oral Surg Oral Med Oral Pathol* 1977;44:89-94.
- Worth H. Principles and practice of oral radiologic interpretation. Chicago: Year Book Medical Publishers, 1963:580-1.
- Bacchini P, Marchetti C, Mancini L, Present D, Bertoni F and Stea G. Ewing's sarcoma of the mandible and maxilla. *Oral Surg Oral Med Oral Pathol* 1986;61:278-283.
- Gorospe L, Fernandez G, Garcia-Raya P, Royo A, Lopez-Barea F and Garcia M. Ewing's sarcoma of the mandible: Radiologic features with emphasis on magnetic resonance appearance. *Oral Surg Oral Med Oral Pathol Oral Radiol Endod* 2001;91:728-34.
- Shetty M, Karkera B, Pereira H & Pandey A. Ewing's sarcoma of the mandible in 11 year old female. *The Internet Journal of Pathology* 2009;8:1.
- Ewing family of tumors treatment – National cancer institute <http://cancerweb.ncl.ac.uk/cancernet/107968.html>.