

1-27-2012

Update on osteonecrosis related to bisphosphonates: A report of three clinical cases

Edgard NEHMÉ

Nadim KHOUEIR

Jeanine HOYEK GEBEILY

Follow this and additional works at: <https://digitalcommons.aaru.edu.jo/iajd>

Recommended Citation

NEHMÉ, Edgard; KHOUEIR, Nadim; and HOYEK GEBEILY, Jeanine (2012) "Update on osteonecrosis related to bisphosphonates: A report of three clinical cases," *International Arab Journal of Dentistry*. Vol. 3: Iss. 1, Article 2.

Available at: <https://digitalcommons.aaru.edu.jo/iajd/vol3/iss1/2>

This Original Article is brought to you for free and open access by Arab Journals Platform. It has been accepted for inclusion in International Arab Journal of Dentistry by an authorized editor. The journal is hosted on [Digital Commons](#), an Elsevier platform. For more information, please contact rakan@aarj.edu.jo, marah@aarj.edu.jo, u.murad@aarj.edu.jo.

UPDATE ON OSTEONECROSIS RELATED TO BISPHOSPHONATES: A REPORT OF THREE CLINICAL CASES

Edgard Nehmé* | Nadim Khoueir** | Jeanine Hoyek-Gebeily***

Abstract

The publications issued since 2003 on osteonecrosis related to oral and / or iv bisphosphonates (BsP) lend a controversy. The recommendations and guidelines from senior scientific authorities reviewed and updated in 2009 by the task force of the AAOMS, define patients in terms of risk and determine practically the prophylactic acts and the limits of operative oral and dental procedures. In these serial clinical cases, we report and discuss three situations with different therapeutic approaches and management.

Keywords: bisphosphonates – osteonecrosis- hypercalcemia.

IAJD 2012;3(1):7-13.

MISE À JOUR SUR L'OSTEONECROSE LIÉE AUX BISPHOSPHONATES: A PROPOS DE TROIS CAS CLINIQUES

Résumé

Les publications parues depuis 2003 sur les ostéonécroses liées aux prescriptions des bisphosphonates (BsP) oraux et/ou par voie intraveineuse prêtent à des controverses. Les recommandations émanant de hautes autorités scientifiques, revues et mises à jour en 2009 par l'AAOMS, définissent mieux les patients en termes de risque et déterminent de façon pratique les mesures prophylactiques et les limites des actes opératoires oraux et dentaires. Dans cette série de cas cliniques, nous rapportons, discussion à l'appui, trois situations et approches thérapeutiques différentes.

Mots- clés : bisphosphonates – ostéonécrose- hypercalcémie.

IAJD 2012;3(1):7-13.

* Professor, Dpt of Oral Pathology
Chairperson post-graduate program of Oral Pathology
Faculty of Dental Medicine,
Saint-Joseph University of Beirut.

** ENT resident
Faculty of Medicine,
Saint-Joseph University of Beirut
nadim_khoueir@hotmail.com

*** Associate Professor
Doctorat d'Université Biologie de la bouche
Head Dpt of Oral Pathology
Maître de conférence
Faculty of Dental Medicine, Saint-Joseph University
of Beirut.

Introduction

Bisphosphonates (BsP), known for inhibiting osteoclast's activity, have been used for the treatment of osteoporosis since 1960s. They've been also implicated in the treatment of hypercalcemia and metastatic cancers. In 2003, Marx [1] reported the first cases of BRONJ (Bisphosphonates-Related Osteonecrosis of the Jaws). In 2007, the American Association of Oral and Maxillofacial Surgeons (AAOMS) adopted in the position paper the case definition on BRONJ based on three main characteristics: current or previous treatment with a BsP, exposed bone in the maxillofacial region for

more than eight weeks and no history of radiation therapy in the jaws [2]. In 2006, Woo et al. [3] reviewed 368 cases revealed some main aspects of BRONJ: most of them (94%) were associated with the intra-venous form and in the treatment of cancer-related hypercalcemia (86%). Moreover, the mandible was the most affected site (65%) and more cases were described in women (sex ratio 3:2).

Numerous risk factors have been associated with BRONJ: potency of the drug, the intra-venous form, treatment duration, cancer, periodontal disease, dento-alveolar surgery, local anatomy

(tori, exostosis), age over 65 years and genetics [4]. Other factors have also been described like corticotherapy, head and neck radiotherapy, chemotherapy, anemia, smoking, coagulopathy, anemia and diabetes (Robertson et al., [5]).

Bone turnover can be evaluated using a test that measures carboxy-terminal collagen crosslinks (CTX) in serum. With this test, clinicians can assess the risk of developing BRONJ (CTX < 100 pg/ml ↔ high risk; CTX = 100- 150 pg/ml ↔ moderate risk; CTX > 150 pg/m ↔ minimal risk) (Marx et al., [6]). However this test has not been

independently validated and its use for estimating the risk of BRONJ is still controversial.

The true incidence of BRONJ is still unknown with wide variations among studies. Indeed, based on case-series, case-controlled and cohort studies, estimates of the cumulative incidence of BRONJ in case of iv route of administration range from 0.8%-12% (Marx et al., [6]). However, the incidence is much lower in the oral form series. For example, the incidence calculated by Merck with alendronate was 0.7/100,000 person/years of exposure [7]. Highest rates were reported in an Australian study (Ault, [8]) (0.01% to 0.04% with spontaneous occurrence and 0.09% to 0.34% after extractions). Finally the incidence estimated by Sedghizadeh [9] with the oral forms was as high as 4%.

Case 1

A 70-year old male presented in October 2008 with acute pain and open wound at the site of tooth #16 that was extracted 2 months ago. Upon examination, some degree of advanced bone necrosis was revealed (Fig.1). The patient had a history of a right renal adenocarcinoma with bone metastasis treated in 2006 with right nephrectomy, chemotherapy (Proleukine for 6 months) and total dose radiotherapy. His current medication included Sutent® (sunitinib, 50mg) and iv Zometa® (zoledronic acid, 15 mg every 2 weeks for 3 months; then 2mg every 4 weeks; then 1 mg every 4 weeks for 21 months). He was still complaining of back and hip pain. A bone scintigraphy done in May 2008 showed hyperfixation at vertebral levels (D9, L2, and L3), right iliac bone, bilateral humerus, proximal right femur and right maxillary sinus suggesting either a metastatic focus or an evidence of a chronic inflammatory disease (Fig.2).

A panoramic film was then taken; it showed a poorly-defined image of crestal maxillary bone loss around the lesion described above with no radiographic evidence of oral-sinus communication (Fig.3). A sinus CT scan also

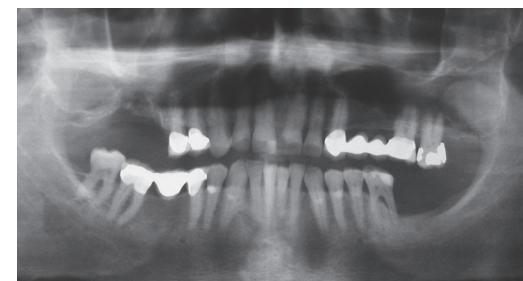
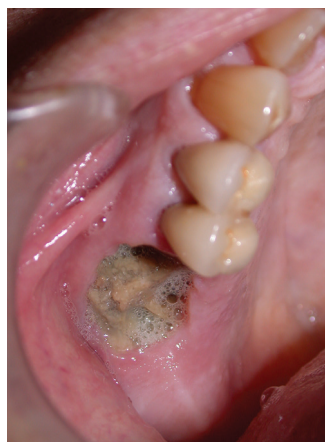

Fig. 3: Panoramic film.

Fig. 1: Osteonecrosis at tooth #16.

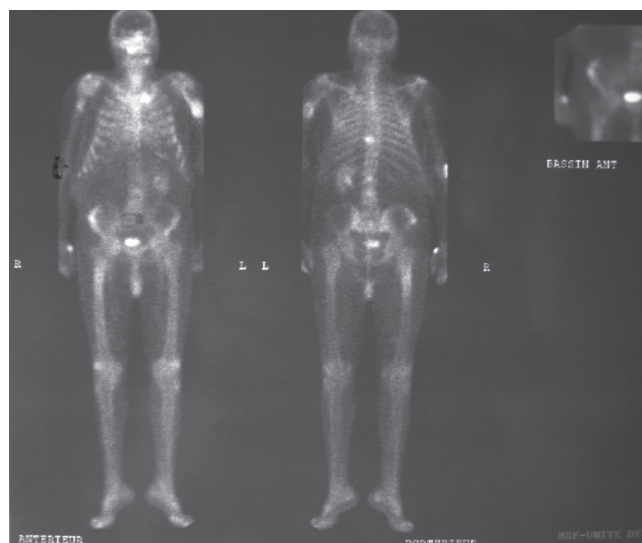


Fig. 2: Bone scintigraphy after iv injection of 19 mCi of HMDP-Tc.

revealed a condensation of the right maxillary sinus (Fig.4). The patient was subsequently admitted to the hospital for bone curettage extending to the right maxillary sinus wall (Fig.5). The purpose was to determine the histological nature of the hyperfixation image (inflammatory or metastatic origin). The histo-pathological exam showed signs of osteonecrosis and chronic sinusitis without evidence of malignancy. Thus, he was treated with iv antibiotics (amoxicillin + clavulanate) and Zometa® was stopped. The patient was discharged under oral antibiotics (amoxicillin + clavulanate) for 2 weeks and a stent (obturator) was placed a few days afterward.

A follow-up visit in May 2009 showed intense necrotic bone loss in

distal tooth #15 and a bone regularization was then conducted (Fig.6). In October 2009, the patient presented with an acute peri-mandibular cellulitis extending from tooth #36. He was treated with 4 weeks oral antibiotics (amoxicillin+clavulanate) and Bétadine® oral rinse. One week later, teeth #15 and #36 were extracted because of terminal bone loss with pain and mobility. Bone regularization was done (Fig.7). Fig.8 shows the aspect 22 weeks after Zometa® was stopped. In February 2011, an extraction of tooth #35 was done and the clinical exam revealed an extension of the osteonecrosis with a sub-total distal bone loss especially on the right maxillary molars quadrant (a large sequestrum was meanwhile rejected) (Fig.9).

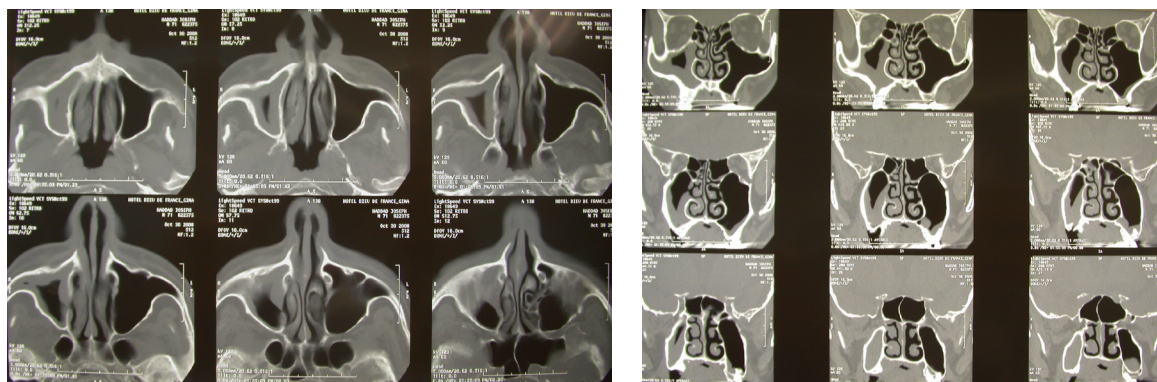


Fig. 4: Sinus CT scan.

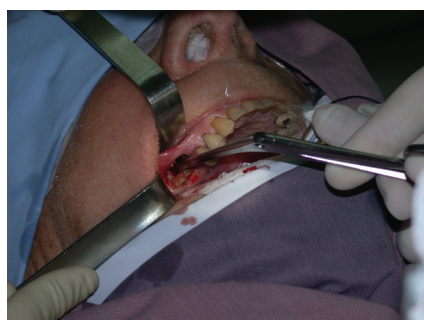

Fig. 5: Extensive bone curettage up to the maxillary sinus.

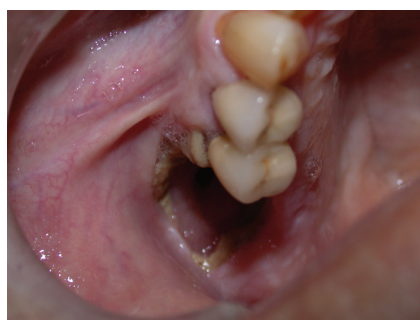

Fig. 6: Bone loss at tooth #15.

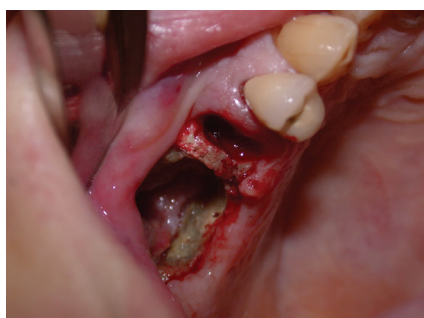

Fig. 7: Bone loss at tooth #36 and #15.

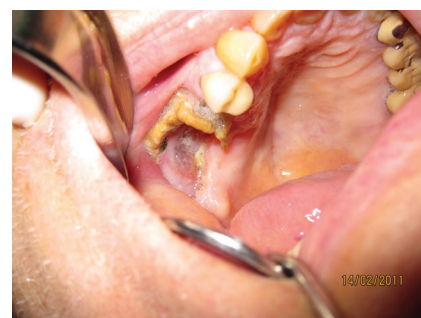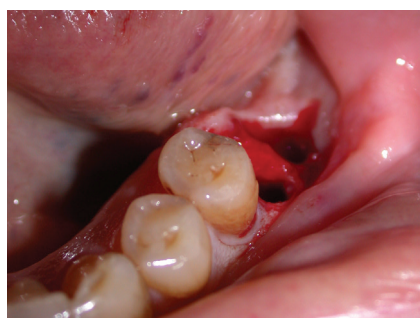


Fig. 8: 22 weeks after discontinuation.

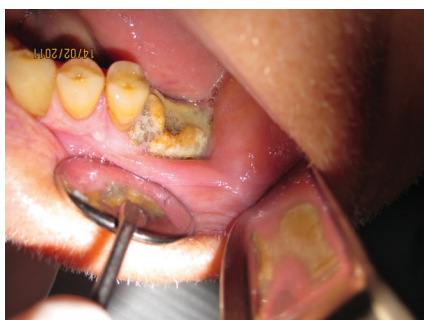

Fig. 9a: Advanced mesial and distal bone loss at the left posterior mandibule.

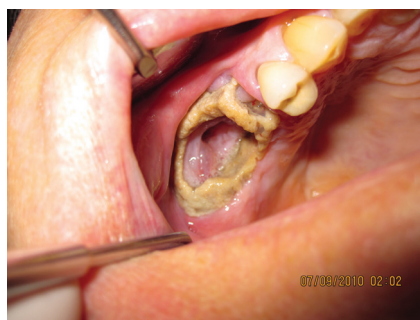
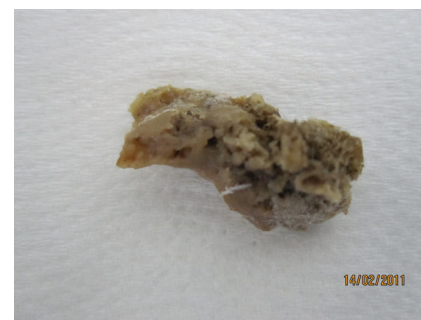
Fig. 9b: Sub-total distal bone loss at the right posterior maxilla.



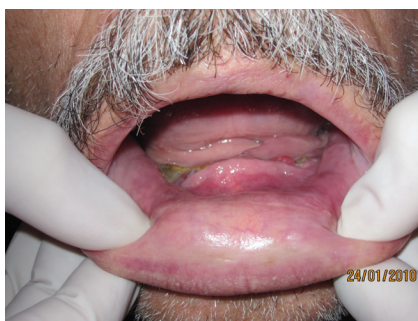

Fig. 10: Bilateral mandibular necrosis.

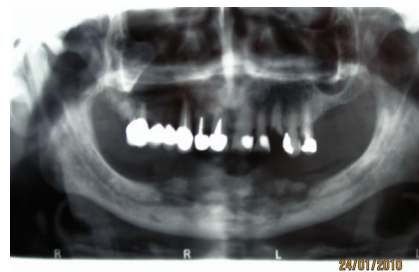


Fig. 11: Panoramic film showing bilateral osteonecrosis with sequestrum.

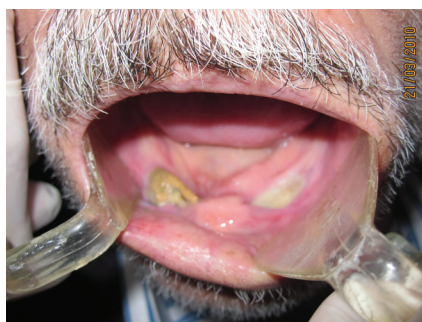
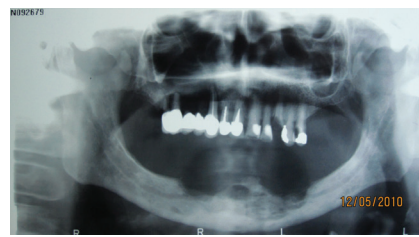
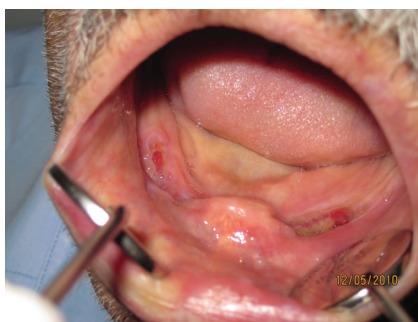Fig. 12: Loss of left and right sequestrum.



Case 2

A 68-year old man presented in January 2010 with acute and bilateral mandibular pain. The patient was edentulous and wore a very old removable and complete dental prosthesis. On physical exam, a bilateral mucosal ulceration was noted with halitosis accompanying an osteonecrosis (Fig.10). The patient had a history of multiple myeloma in February 2008 treated with chemotherapy. He also received iv Zometa® (zoledronic acid) one dose per month for a year (stopped in April 2009). He also took blood thinners (Sintrom®) and lipid-lowering (Simvast®).

The panoramic film done showed a diffuse mandibular osteonecrosis (Fig.11). Peripheral bone regularization limited to the inflammatory gingiva was thus performed and the patient was given oral antibiotic (amoxicillin + clavulanate) and anti-bacterial oral rinse (chlorhexidine). Apart from this regularization to relieve the pain, no

other intervention on the necrotic bone was considered.

During the follow-up he presented respectively in March and May 2010 with left and right mandibular sequestrum (Fig.12). Note that in April 2010 the patient received 10 sessions of pelvic radiotherapy following a bilateral acute back pain.

Case 3

A 53-year old woman presented in September 2010 with a healing defect at the site of tooth #48 that was extracted one year ago. She mentioned that a bone sequestrum was spontaneously eliminated in June 2010 while she was taking Ibuprofen. A mucosal curettage was then performed by her dentist. She had a history of breast cancer in 2006 treated with Decapeptyl® and mastectomy. She was started on iv Zometa® (zoledronic acid) in January 2009 followed by one dose every 6 months (the next dose was programmed in December 2010).

In November 2010 malodorous purulent discharge appeared at the site of the unhealed wound (Fig. 13). Curettage of the inflammatory tissue was then performed and the culture of the pus revealed only normal oral flora without other specific pathogens as Actinomyces. She was given one month of amoxicillin and metronidazol with anti-bacterial oral rinse (chlorhexidine). After a discussion with the oncologist, he decided to suspend the treatment with iv Zometa®. In December 2010, during her follow-up visit, the antibiotics were given for another month and the patient was seen again in January 2011: the mucosal healing was complete at the site of tooth #48 and a 3mm thin sequestrum was removed (Fig.14a,b). The plan was then to extract lately tooth #26 while having another month of antibiotics. Finally, after four months of a non-stop antibiotherapy (amoxicillin + metronidazol), the tooth #26 was removed on April 1st, 2011 by a partial thickness flap covering the wound with sutures

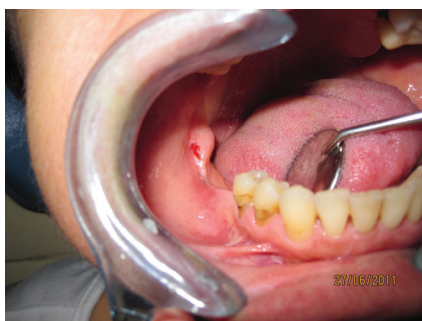

Fig. 13: Infection of unhealed wound and panoramic film.

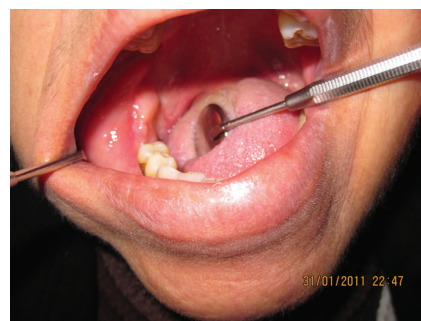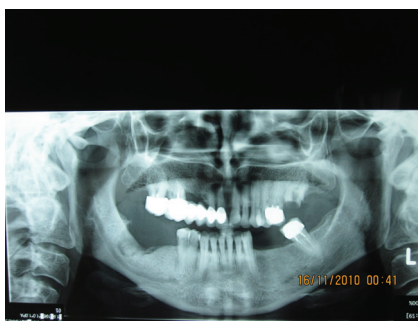


Fig. 14a: Healed wound.



Fig. 14b: Sequestrum

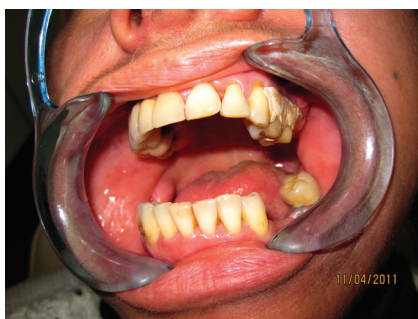

Fig. 15: Surgical removing of the tooth #26.

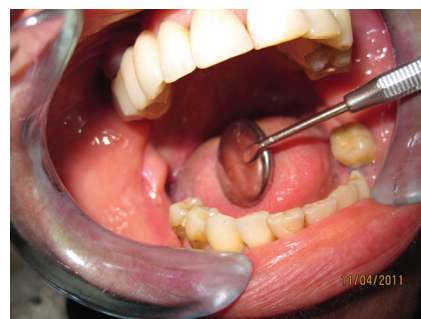

Fig. 16: Total mucosal healing of the area of wisdom tooth #48.

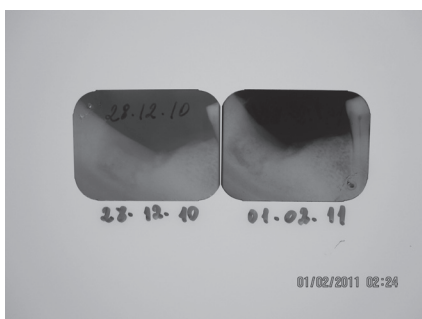

Fig. 17: Osteonecrosis evolution from October 28, 2010 to June 28, 2011.

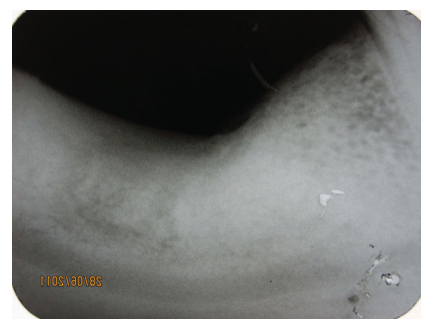
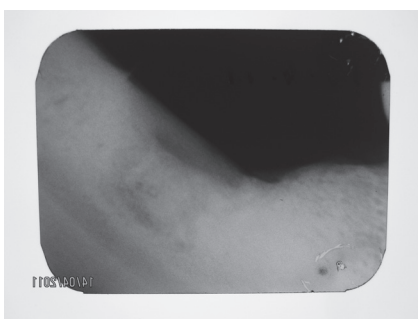
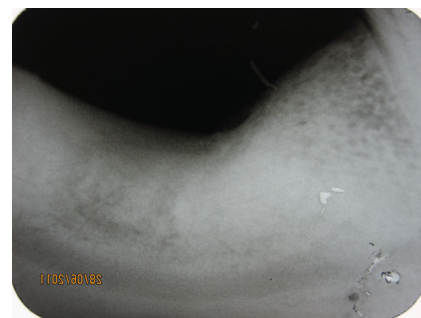


Fig. 18: Removal of sequestrum from site 48 and complete mucosal healing on both sites 48 and 26.

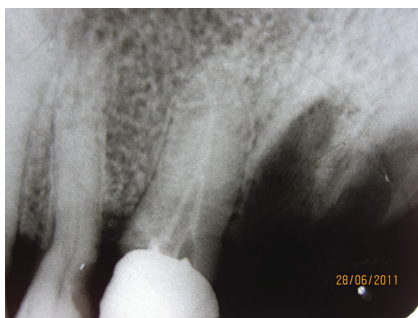

Fig. 19: Stabilization of the bone at the site of the missing tooth #48 and incomplete alveolar healing three months after the extraction of tooth #26.



and a dressing Coe-Pack®. Antibiotics as well as antibacterial oral rinse (chlorhexidine) were continued until wound healing (Fig.15). The radiographic control of BRONJ in April 12th, 2011 at the site of tooth #48 showed favorable bone remodeling consistent with perfect healing of fibromucosa at the clinical inspection (Fig.16). Fig.17 showed the evolution of osteonecrosis on retroalveolar films between October 28th, 2010 and June 28th, 2011.

In juin11, a blood test, a lung X-ray and an abdominal pelvic ultrasound revealed no evidence for recurrence or worsening of her cancer. Zometa was finalized since the last injection in December that had not been administered. Mucosal healing on sites 48 and 26 was complete and a small sequestrum that adheres to the emergent fibromucosa was removed at the forceps (Fig.18). Two retroalveolar films were taken to sites 48 and 26. It shows a stabilization of the bone at 48 and an incomplete alveolar healing three months after the extraction of 26 (Fig.19).

Discussion

The three cases presented above are similar concerning the development of jaw osteonecrosis in association with the intravenous route of administration of BsP. However the second case differs from the others in that it was revealed few months after the treatment was stopped. This is in complete concordance with the case definition of BRONJ [2] and with the fact that more than 90% of the disease is induced by iv bisphosphonates (Woo et al., [3]). Moreover in the 3 cases, BRONJ is not a spontaneous complication but was subsequent to trauma like tooth extraction (cases 1 and 3) or the presence of a denture (case 2). The low risk of developing spontaneous BRONJ is mentioned in many articles while reviewing the literature [9, 10].

Advanced stages of BRONJ are presented in the cases above. A stage 3 disease is noted in case1 because of

evidence of sinus wall involvement. A stage 2 disease concerns the cases 2 and 3 because of evidence of infection: pain and ulceration in case 2 and pain with pus in case 3 (Hoff et al., [11]).

The management of BRONJ in all cases seems in concordance with the recommendations of the AAOMS presented in the position paper on bisphosphonate-related osteonecrosis of the Jaw—2009 update [4]. Note that the first case was managed despite of the poor knowledge available at that time. Indeed a stage 2 BRONJ should be treated with oral antibiotics, oral antibacterial mouth rinse and superficial debridement to relieve tissue irritation. An extended surgical debridement should be also considered for stage 3 with reconstruction by a plate or an obturator periodically relined by a soft material (Viscogel®, Dentsply-Detrey). In addition, any bony sequestrum should be removed without exposing uninvolved bone and any symptomatic tooth at the site of the necrosis should be extracted because it does not exacerbate the process (Silverman & Landesberg, [12]).

Concerning the management of infection, any purulent discharge should be sampled for culture. If there is no evidence of actinomyces, oral amoxicillin with or without metronidazole is sufficient to cover the germs involved [4, 13]. Ruggiero [14] in 2006 recommended the biopsy only if a metastasis is suspected and considered that hyperbaric oxygen therapy is ineffective. The efficacy of this treatment is still controversial. Finally, the discontinuation of iv BsP in patients with BRONJ shows long-term benefits in terms of stabilizing the necrotic site, preventing new sites development and reducing clinical symptoms. It should be discussed with the oncologist to study the balance between the risks and benefits [4].

The duration and type of the antibiotics treatment is still controversial: some authors support a long-term pre-operative treatment with evidence of better outcome: less recurrence and better mucosal healing without evi-

dence of increased rate of actinomyces infection. Mitsimponas et al. [15] administered ampicillin and clavulanate intravenously for 6 days followed by an oral medication for at least 6 days. Bagan et al. [16] recommended a 10-to-15 day antibiotic regime with amoxicillin and clavulanate or clindamycin accompanied by CHX mouth rinses. For a poor response, they prolonged this scheme for up to 1 month. Stanton and Balasanian [17] administered only antibiotics before operation if an active inflammation was obvious. Otherwise antibiotics were initiated immediately after surgery [18].

Nowadays, prevention is the most effective way to limit the development of BRONJ. First of all, the risk of BRONJ is reduced if some precautions are taken before initiation the treatment with BsP: oral evaluation including panoramic x-ray, removal of symptomatic teeth and complete all the invasive dental procedures. This procedure is possible if the systemic condition of the patients permits the treatment delay [4]. Moreover in an asymptomatic patient taking iv BsP, frequent oral dental evaluation with strict oral hygiene are crucial for reducing the risk of BRONJ. Implants are not recommended and any elective jaw surgery should be avoided or if necessary, BsP discontinuation should be discussed with the oncologist [4, 14].

Many studies have demonstrated the potential for simvastatin to promote bone regeneration by enhancing osteoblastic activity and inhibiting osteoclastic activity: enhancing BMP-induced osteoblast differentiation, reversing the suppressive effect of TNF, promoting phosphatase alkaline activity and mineralization, anti-inflammatory effect... It is also demonstrated that low doses (1mg/kg/day orally) decreases bone regeneration while higher doses (20mg/kg/day orally) stimulates it [19]. However other studies state that simvastatin is similar to placebo concerning the effect on bone regeneration [20]. These contradicted results are mainly due to the variability in the route of administration, the

duration of exposure and the experimental animal model [19].

Finally, it is interesting to note in connection with the case 3 the following elements:

- Osteonecrosis in the site 48 was installed when the patient had already undergone four injections every six months.
- The suspension of the fifth injection and wound healing two months later.
- The absence of another outbreak of osteonecrosis despite the presence of residual roots at the site of the tooth #26 which is in itself a potential source of infection.

Acknowledgements

The authors thank Professor Amine Haddad, Head of Department of E.N.T. at Hotel-Dieu Hospital, Beirut, Lebanon for the surgical management and the follow-up of the case # 1.

References

1. Marx R. Pamidronate (Aredia) and zoledronate (Zometa) induced avascular necrosis of the jaws: a growing epidemic. *J Oral Maxillo fac Surg* 2003(9):1115-7.
2. American Association of Oral and Maxillofacial Surgeons position paper on Bisphosphonate-Related Osteonecrosis of the Jaws. Advisory Task Force on Bisphosphonate-Related Osteonecrosis of the Jaws. *J Oral Maxillofac Surg* 2007;65:369.
3. Woo S, Hellstein J, Kalmar J. Systematic review: Bisphosphonates and osteonecrosis of the jaws. *Annals of Internal Medicine* 2006;144:753-761.
4. American Association of Oral and Maxillofacial Surgeons position paper on Bisphosphonate-Related Osteonecrosis of the Jaws-2009 update. Task Force on Bisphosphonate-Related Osteonecrosis of the Jaws.
5. Robertson A, Kraenzlin M, Zeilhofer H-F, Meier C. Ostéonécrose maxillaire due aux bisphosphonates. Recommandations diagnostiques et thérapeutiques. *Curriculum Forum Med Suisse* 2007;7:410.
6. Marx R, Sawatari Y, Fortin M et al. Bisphosphonate-induced exposed bone (osteonecrosis/osteopetrosis) of the jaws: risk factors, recognition, prevention, and treatment. *J Oral Maxillofac Surg*. 2005;63(11):1567-157.
7. Report of the Council of Scientific Affairs. Expert panel recommendations: dental management of patients on oral bisphosphonate therapy. ADA, June 2006.
8. Ault A. Jaw necrosis affects 1 in 1,700 on oral bisphosphonates. *Internal Medicine News* 41:23, August 1, 2008.
9. Sedghizadeh P, Stanley K, Caligiuri M, Hofkes S, Lowry B, Shuler C. Oral bisphosphonate use and the prevalence of osteonecrosis of the jaw: An institutional inquiry. *J Am Dent Assoc* 2009;140:61-66.
10. Durie B, Katz M, Crowley J. Osteonecrosis of the jaws and bisphosphonates. *N Engl J Med* 2005; 353:99-110.
11. Hoff A, Toth B, Altundag K et al. Osteonecrosis of the jaw in patients receiving intravenous bisphosphonate therapy. ASCO Annual Meeting Proceedings. *J Clin Oncol*. 2006;24:8528.
12. Silverman SL, Landesberg R. Osteonecrosis of the jaw and the role of bisphosphonates: a critical review. *Am J Med*. 2009 Feb;122(2 Suppl):33-45.
13. Kademani D, Koka S, Lacy MQ, Rajkumar SV. Primary surgical therapy for osteonecrosis of the jaw secondary to bisphosphonate therapy. *Mayo Clin Proc* 2006;81:1100.
14. Ruggiero S et al: Practical guidelines for the prevention, diagnosis and treatment of osteonecrosis of the jaw in patients with cancer. *J Oncol Prac* 2006; 2(1):7-14.
15. Mitsimponas K, Sereti M, Semergidis T. Bisphosphonate - associated osteonecrosis: role of surgery. *J Craniomaxillofac Surg*. 2008;36(suppl):33.
16. Bagan J, Blade J, Cozar JM et al. Recommendations for the prevention, diagnosis, and treatment of osteonecrosis of the jaw (ONJ) in cancer patients treated with bisphosphonates. *Med Oral Pathol Oral Bucal*. 2007;12:336-340.
17. Stanton DC, Balasanian E. Outcome of surgical management of bisphosphonate-related osteonecrosis of the jaws: review of 33 surgical cases. *J Oral Maxillofac Surg*. 2009 May;67(5):943-50.
18. Hoefert S, Eufinger H. Relevance of a prolonged preoperative antibiotic regime in the treatment of bisphosphonate-related osteonecrosis of the jaw. *J Oral Maxillofac Surg*. 2011 Feb;69(2):362-80.
19. Jun-Beom Park. Simvastatine review. *Med Oral Patol Oral Cir Bucal*. 2009 Sep 1;14(9):485-8.
20. Zhang L, Liu X, Tian F, Zhang H, Han D. Effects of simvastatin on bone formation relative factors of trabecular bone and osteogenic differentiation of bone marrow mesenchymal stem cells in young rats. *Zhongguo Xiu Fu Chong Jian Wai Ke Za Zhi*. 2011;2:155-9.