

1-27-2012

Oral symptoms leading to diagnosis of sarcoidosis

D.R. MAHESH

Follow this and additional works at: <https://digitalcommons.aaru.edu.jo/iajd>

Recommended Citation

MAHESH, D.R. (2012) "Oral symptoms leading to diagnosis of sarcoidosis," *International Arab Journal of Dentistry*. Vol. 3: Iss. 1, Article 5.

Available at: <https://digitalcommons.aaru.edu.jo/iajd/vol3/iss1/5>

This Original Article is brought to you for free and open access by Arab Journals Platform. It has been accepted for inclusion in International Arab Journal of Dentistry by an authorized editor. The journal is hosted on [Digital Commons](#), an Elsevier platform. For more information, please contact rakan@aar.edu.jo, marah@aar.edu.jo, u.murad@aar.edu.jo.

ORAL SYMPTOMS LEADING TO DIAGNOSIS OF SARCOIDOSIS

D.R. Mahesh*

Abstract

Sarcoidosis is a multisystemic granulomatous disease of unknown etiology that may manifest in the oral and maxillofacial region. Enlargement of the major salivary glands may be the first identifiable sign of this condition, which is often characterized by a variety of nonspecific symptoms. In this report, we present the case of a patient suffering from xerostomia, dysgeusia, burning sensation, xerophthalmia and bilateral parotid gland enlargement. The diagnosis of systemic sarcoidosis was established, based on the clinical associated symptoms as well as the histopathologic results of a biopsy of labial minor salivary glands.

Keywords: sarcoidosis – biopsy - salivary glands - xerostomia - xerophthalmia.

IAJD 2012;3(1):31-33.

SYMPTÔMES ORAUX MENANT AU DIAGNOSTIC DE LA SARCOÏDOSE

Résumé

La sarcoïdose est une affection granulomateuse bénigne, non caséuse, multisystémique et idiopathique. L'hypertrophie des glandes salivaires majeures peut être le premier signe révélateur de cette affection souvent caractérisée par une variété de symptômes non spécifiques. Dans cet article, nous présentons le cas d'un patient souffrant de xérostomie, de dysgueusie, de sensation de brûlure buccale, de xérophtalmie et d'un élargissement bilatéral des glandes parotides. Le diagnostic de sarcoïdose systémique a été posé en se basant sur les données cliniques et le résultat histopathologique de la biopsie des glandes salivaires mineures.

Mots- clés: sarcoïdose – biopsie – glandes salivaires – xérostomie - xérophtalmie.

IAJD 2012;3(1):31-33.

* Assistant Professor.

Oral medicine Dpt,

Rajiv Gandhi University of Health Sciences, India

maheshsvdc@rediffmail.com

Introduction

Sarcoidosis is a multisystemic granulomatous disease of unknown etiology, affecting multiple organs [1]. It usually presents with bilateral hilar adenopathies, pulmonary infiltrations, ocular and cutaneous lesions. Oral involvement is relatively less frequent. The most common oral or para-oral symptom appears to be an asymptomatic swelling, usually of the parotid glands or the cervical nodes. The diagnosis is established when a clinical and a radiological compatible

profiles are supported by the histological demonstration of non-caseating granulomas in one or more tissues. In this article, we present a patient with systemic sarcoidosis who developed specific symptoms in the oral cavity.

Case report

A 57-year-old woman reported with complaints of severe xerostomia, burning tongue sensation, dysgeusia, dysphagia and diminished taste acuity. She had recently noticed an increased fullness in her facial appearance. Her

oral symptoms began several months ago but had mostly exacerbated during the last month.

The patient denied any alcohol or drug abuse. A systemic evaluation revealed a dryness of the skin, mouth, nose and eyes as well as fatigue and pain in multiple joints.

A slightly deviated facial profile was observed on the extraoral examination with bilateral parotid glands enlargement inducing a raise in her ears lobes (Fig. 1- 2). This bilateral enlargement was tender on palpation. No increase in submandibular and lacrimal glands

sizes was observed. No lymphadenopathy was detected. A Schirmer-test revealed diminished tear production in both eyes (3 mm/five min; normal: > 8 mm/five min). The patient's oral mucosa was extremely dry with a wrinkled, erythematous appearance, and her tongue was coated with a brownish residue. A clear, sluggish flow was discharged from patent Stensen's and Wharton's ducts, with and without digital and gustatory stimulation. Unstimulated and stimulated whole salivary flow rates were 0.05 mL/min (normal: > 0.1 mL/min) and 0.7 mL/min (normal: > 1.0 mL/min), respectively, indicating a diminished saliva flow rate. The patient was dentate, with no obvious clinical caries.

A Sjögren's syndrome was at first suspected, therefore serologic tests for Sjögren's syndrome antibodies (SS-A, SS-B), antinuclear antibody and rheumatoid factor were conducted but the results were negative.

A specimen of labial minor salivary glands was biopsied; its histologic examination demonstrated the encroachment of minor salivary gland tissue by noncaseating granulomas, suggestive of foreign-body implantation or a systemic granulomatous disease. No necrosis was identified. A Ziehl-Neelsen stain was negative for mycobacteria; periodic acid-Schiff and Gomori's methenamine-silver stains were negative for fungi.

Taking these findings into consideration, the sarcoidosis was suggested as a possible cause of the oro-facial signs and symptoms. The patient was therefore referred to a rheumatologist who subsequently diagnosed systemic sarcoidosis on the basis of abnormal findings on conventional chest radiographs and computed tomographic scans, an elevated serum angiotensin-converting enzyme (SACE) level, as well as the histologic results and the exclusion of other causes of granulomatous inflammation. A short-term systemic corticotherapy was prescribed to help resolve the orofacial symptoms. The patient was prescribed sugar-free candies and artificial saliva, was advised




Fig. 1: Deviated facial profile observed on the extraoral examination.

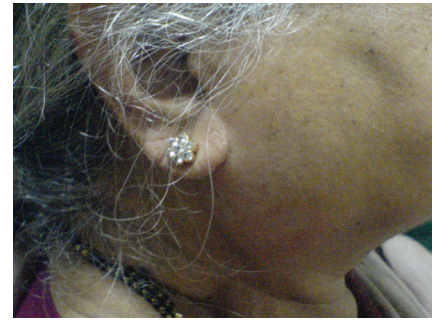

Fig. 2: Bilateral parotid gland enlargement.

to increase the water intake for symptomatic relief of xerostomia, oral burning sensation and dysphagia.

Discussion

Sarcoïd lesions of the jaw bones may appear as diffuse, poorly defined radiolucencies on dental radiographs, and they can result in tooth mobility on clinical examination [2].

A differential diagnosis for bilateral parotid swellings, with or without xerostomia, includes immunologic conditions (ex: Sjögren's syndrome, benign lymphoepithelial lesion), granulomatous disorders (ex: sarcoidosis), salivary gland neoplasms (ex: Warthin's tumor), metabolic disorders (ex: diabetes), viral conditions (ex: mumps, HIV parotitis), sialadenosis due to malnutrition or alcoholism, sialadenitis (bacterial or obstructive), lymphoma and medication-induced hypertrophy.

In our case-report, bilateral swellings, absence of pain (particularly at mealtimes) and lack of pus excluded both obstructive (sialolithiasis, ductal stricture) and bacterial sialadenitis as the underlying disease. The patient denied abusing alcohol and did not fit the profile of a malnourished person. Also, the relatively rapid onset of parotid swellings and the firmness of the parotid glands on palpation contradicted the insidious onset and normal texture of the enlarged parotid glands seen in sialadenosis [3]. The patient wasn't diabetic, had no risk factors for HIV disease and reported a distant history of childhood mumps. Therefore,

Sjögren's syndrome and sarcoidosis were considered potential causes of the patient's symptoms.

Sarcoidosis is a multifocal, immune-mediated, systemic inflammatory disorder characterized by the presence of noncaseating granulomas in the involved organs [2, 4-6]. The disease occurs worldwide and may affect people of either sex, as well as those from any ethnic or age group [2, 7-10]. It usually arises in the second to fourth decades of life [5, 8, 10], with women being somewhat more frequently affected and at a greater risk than men of developing serious complications [7, 11].

Diverse treatments have been employed for lesions of sarcoidosis in oral mucous membrane. Asymptomatic lesions do not require any treatment, as spontaneous remission is not uncommon. The treatment most frequently carried out is surgical extirpation, which is the treatment of choice for singular nodular lesions that are uncomfortable [12, 13]. The oral administration

of corticoids should be considered only for painful or progressive lesions that interfere with the functionality of the oral mucous membrane, making eating or speech difficult [12, 13].

The management of patients with sarcoidosis should take into consideration the systemic implications of the disease and the applied therapy.

The long-term corticotherapy may render the patients susceptible to infections [3], thus requiring the prescription of prophylactic antibiotics, especially when invasive dental pro-

cedures are planned [3]. On the other hand, anemia and other hematologic changes may be observed, resulting from granulomatous infiltration of bone marrow. In addition, platelet retention associated with hypersplenism may lead to occasional thrombocytopenia [10], necessitating preoperative blood count tests.

Therefore, clinicians should defer major dental interventions, especially those requiring general anesthesia until a patient's medical status and degree of vital organ dysfunction have been evaluated and proven stable [2]. Sarcoid infiltration of major salivary glands and subsequent xerostomia predispose patients to caries, periodontal disease and candidosis, highlighting the need for frequent recall

appointments and aggressive preventive measures with the prescription of salivary stimulants and anti-fungal medications as well as the regular application of topical fluoride [2, 11].

Conclusion

Enlargement of the major salivary glands may be the first sign revealing an underlying sarcoidosis. This case emphasizes the importance of including sarcoidosis in the differential diagnosis of bilateral parotid swelling associated with xerostomia. It also highlights the potential role of the dentist in the diagnosis and dental treatment of patients with systemic sarcoidosis.

References

- Hunninghake GW, Costabel U, Ando M, Baughman R, Cordier JF, Du Bois R, et al. ATS/ERS/WASOG statement on sarcoidosis. American Thoracic Society/European Respiratory Society/World Association of Sarcoidosis and other Granulomatous Disorders. *Sarcoidosis Vasc Diffuse Lung Dis.* 1999;16:149-73.
- Batal H, Chou LL, Cottrell DA. Sarcoidosis: medical and dental implications. *Oral Surg Oral Med Oral Pathol Oral Radiol Endod* 1999; 88:386-90.
- Small EW. Aspiration biopsy in parotid gland sarcoidosis. *JADA* 1966; 73:96-9.
- Baughman RP, Lower EE, du Bois RM. Sarcoidosis. *Lancet* 2003; 361:1111-8.
- Kimani AP, Aguayo SM. Sarcoidosis: an overview for the primary care physician. *Compr Ther* 1998; 24(1):20-5.
- James DG. Sarcoidosis 2001. *Postgrad Med J* 2001; 77:177-80.
- Vourlekis JS, Sawyer RT, Newman LS. Sarcoidosis: developments in etiology, immunology and therapeutics. *Adv Intern Med* 2000; 45:209-57.
- Thomas KW, Hunninghake GW. Sarcoidosis. *JAMA* 2003; 289:3300-3.
- English JC 3rd, Patel PJ, Greer KE. Sarcoidosis. *J Am Acad Dermatol* 2001; 44:725-43.
- Reed TM. Sarcoidosis: a review and case report. *J Am Podiatr Med Assoc* 1988; 78:279-86.
- Steinberg MJ, Mueller DP. Treating oral sarcoidosis. *JADA* 1994; 125:76-9.
- Kasamatsu A, Kanazawa H, Watanabe T, Matsuzaki O. Oral sarcoidosis: report of a case and review of literature. *J Oral Maxillofac Surg.* 2007;65:1256-9.
- Suresh L, Radfar L. Oral sarcoidosis: a review of literature. *Oral Dis.* 2005;11:138-45.