

2-18-2013

## Inducing apical barrier in fractured non-vital immature permanent incisors using single calcium hydroxide dressing – A case report

Mahsa OROOJI

Rami MAKSOUUD

Follow this and additional works at: <https://digitalcommons.aaru.edu.jo/iajd>

---

### Recommended Citation

OROOJI, Mahsa and MAKSOUUD, Rami (2013) "Inducing apical barrier in fractured non-vital immature permanent incisors using single calcium hydroxide dressing – A case report," *International Arab Journal of Dentistry*. Vol. 4: Iss. 1, Article 6.

Available at: <https://digitalcommons.aaru.edu.jo/iajd/vol4/iss1/6>

This Original Article is brought to you for free and open access by Arab Journals Platform. It has been accepted for inclusion in International Arab Journal of Dentistry by an authorized editor. The journal is hosted on [Digital Commons](#), an Elsevier platform. For more information, please contact [rakan@aar.edu.jo](mailto:rakan@aar.edu.jo), [marah@aar.edu.jo](mailto:marah@aar.edu.jo), [u.murad@aar.edu.jo](mailto:u.murad@aar.edu.jo).

## INDUCING APICAL BARRIER IN FRACTURED NON-VITAL IMMATURE PERMANENT INCISORS USING SINGLE CALCIUM HYDROXIDE DRESSING – A CASE REPORT

Mahsa Orooji\* | Rami Maksoud\*\*

### Abstract

*Endodontic treatment of immature traumatic non-vital permanent teeth is delicate since open apices and divergent canal walls render the debridement and obturation difficult. Its success depends on the closure of the root apex and the establishment of an apical barrier. Different materials are used for the apexification procedure. Calcium hydroxide apexification is the most common treatment for necrotic, immature permanent teeth. The aim of this report is to present a case of apexification using a single injected calcium hydroxide dressing for the treatment of a necrotic pulp of permanent incisors with wide open apices in a young patient. The obtained result indicated that an apical stop is created with single visit apexification. Radiologic examination after 5 months showed that the apices of the maxillary incisors are completed by newly formed tissue. In spite of success in apical barrier formation by single visit calcium hydroxide dressing, long-term follow-up of these teeth is necessary.*

**Keywords:** Calcium hydroxide – apexification - apical closure - open apex - immature teeth.

IAJD 2013;4(1):38-41.

## BARRIÈRE APICALE INDUITE AU NIVEAU DES INCISIVES PERMANENTS IMMATURES FRACTURÉES ET NON VIVANTES EN UTILISANT UN PANSEMENT A L'HYDROXYDE DE CALCIUM. A PROPOS D'UN CAS

### Résumé

Le traitement endodontique des dents permanentes immatures à la suite d'un trauma est délicat puisque les apex ouverts et la divergence des parois canalaire rendent le débridement et l'obturation difficiles. Son succès dépend de la création d'une constriction apicale. Différents matériaux sont utilisés pour la procédure d'apexification. L'apexification au moyen de l'hydroxyde de calcium est le traitement le plus répandu pour les dents permanentes immatures et/ou à pulpe nécrosée. L'objectif de ce rapport est de présenter un cas d'apexification réalisée en une seule séance à l'aide d'un hydroxyde de calcium injecté dans le cadre du traitement de la pulpe nécrosée des incisives permanentes immatures à apex largement ouverts chez une jeune patiente. L'examen radiologique à 5 mois a montré la fermeture complète des apex des incisives supérieures.

**Mots-clés :** Hydroxide de calcium – apexification – dent immature.

IAJD 2013;4(1):38-41.

\* Postgraduate student,  
Dpt of Pediatric Dentistry  
Faculty of Dentistry  
University of Aleppo, Syria  
mahsaorooji@gmail.com

\*\* Assistant professor,  
Dpt of Pediatric dentistry  
Faculty of dentistry,  
University of Aleppo, Syria  
maksoudds@hotmail.com

## Introduction

Dental traumatic injuries are very frequent among children and teenagers, especially in the range of 7 to 14 years old [1]. They may lead to tooth non-vitality. The anterior permanent incisors are usually the most affected teeth. When the apices are incompletely formed and the canals are wide, the endodontic treatment is often a major challenge because of the lack of apical constriction.

Apexification is the traditional technique to manage such cases; it is defined as "a method to induce a calcified barrier in a root with an open apex or the continued apical development of an incomplete root in teeth with necrotic pulp" [2].

Calcium hydroxide (Ca(OH)<sub>2</sub>) has been the material of choice for the apexification of immature permanent teeth [2, 3]. The time taken for complete apexification using calcium hydroxide has been reported to be variable, ranging from 5-20 months [3, 4] or 12.9 months as an average [5].

In this period, how frequently the calcium hydroxide dressing should be changed is a controversy in the endodontic literature. A report advocated changes at 1 month and at 6-8 months intervals until apical barrier formation [6]. Other studies have shown that replacing the dressing could be beneficial when calcium hydroxide is washed out of the canal [7].

This long course treatment has some challenges, like losing the temporary coronal restoration leading to re-infection [8], the risk of tooth fracture if the treatment is prolonged for extended periods [9, 10] and the need for many recall visits. Furthermore, this treatment requires a high level of patient compliance and the follow-up appointments to radiographically assess the barrier formation become critical.

For these reasons, a single-visit apexification using a single dressing with Ca(OH)<sub>2</sub> has been suggested to

induce apical barrier formation in non-vital immature teeth [11-13].

This case report describes the management of immature anterior incisors in a single visit, using Ca(OH)<sub>2</sub> injected dressing to induce apexification.

## Case report

A 9-year-old girl presented to our department with a fractured permanent maxillary right and left central incisors. The patient fell while playing 6 months ago. The fracture in the permanent maxillary central incisors was evident on clinical examination. The pulp was necrotic since no response was obtained when applying vitality tests (cold and heat tests). The patient had mild pain on percussion. There was absence of any sinus tract. Periapical radiography showed incomplete root formation with wide open apices (Fig. 1).

Both incisors were treated to induce apical development. In the first visit, an access cavity was prepared with high-speed round diamond bur under coolant. The necrotic pulp tissues in the chamber were removed with slow-speed round bur and the remained tissues in the canal were removed with broaches. The canal working length was determined with a K-file #30. Irrigation with 5% sodium hypochlorite was done throughout cleaning and shaping. The canal was dried using sterile absorbent paper points. After preparing the canal, a plastic needle was pushed down through the canal. Then Ca(OH)<sub>2</sub> Calcipex (Calcipex and Calcipex Plain; Nippon Shika Yakuhin KK, Shimonoseki, Japan) was injected into the canal during the pulling out process until the canal was completely filled (Fig. 2). The access cavity was temporarily obturated with Cavisol, an impermanent filling material that hardens when in contact with the saliva.

Periapical radiographs of both incisors showed continued apical development. At the recall visit 5 months later, the closure of the apex was evident on the radiograph.

Apexification was confirmed clinically by using paper point. At that time point, the canals were conventionally obturated with gutta percha (Fig. 3) and a composite restoration in the access cavity.

## Discussion

Different materials have been used in the apexification of non-vital pulp in permanent teeth such as zinc oxide-iodoform [14], poly-antibiotic paste [15], antiseptic paste [16], calcium hydroxide based materials [17], Vitapex [18], or even no material at all [19].

The calcium hydroxide, introduced by Hermann in 1930 [20], has been used with great success to induce the formation of an apical hard tissue barrier in immature open apices. Its biological characteristics and bacteriological effects are numerous. Calcium hydroxide has an antimicrobial effect [3] by releasing hydroxyl ions [21, 22] which cause protein denaturation and bacterial DNA damage. According to Sheehy and Roberts [23], the use of calcium hydroxide for apical barrier formation is successful in 74-100% of cases.

Kaiser [24] and Frank [25] were the first to use it and to report the reliable closure of immature roots. Because of its enhanced success rate, easy availability for clinician and affordability for patients, it has gained widest acceptance in the literature.

Chawla [12] has suggested that the amount of Ca(OH)<sub>2</sub> in the single root canal dressing was sufficient to initiate and complete the bridge in 92.3% of the teeth in his study. Chosack et al. [26] suggested that repeated root filling are not required as Ca(OH)<sub>2</sub> is only required to initiate healing process. They also reported that the Ca(OH)<sub>2</sub> has to be replaced if there are any symptoms or displacement of the medicament.

The frequency of Ca(OH)<sub>2</sub> dressing change is one of the few variables within the operator's control, which also has an effect on the speed of bar-

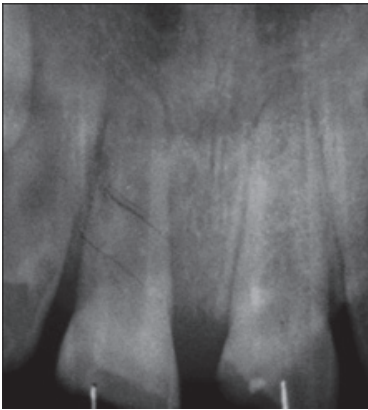


Fig. 1: Incomplete root formation with wide open apices.

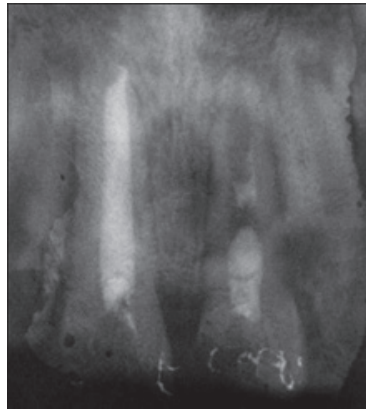


Fig. 2: Canals filled with Ca(OH)2.

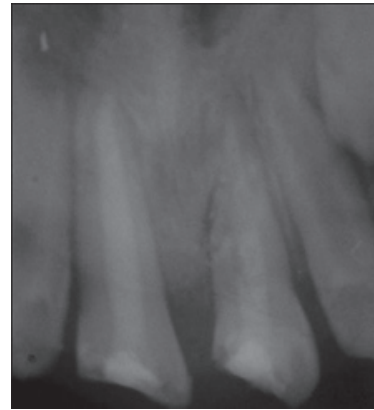

Fig. 3: Periapical radiograph showing the apices formation.

rier formation. The time interval for calcium hydroxide apexification has been reported to be variable, ranging from 3-24 months [10]. Some studies showed that when the frequency of changes was low, rapid barrier formation was seen whereas when the frequency of the changes was high, it needed more time for barrier to be formed [27, 28]. Also it is confirmed that, if the apical barrier is disturbed by repeated instrumentation and dressing changes, the time needed for apex formation will be prolonged [29].

Calcipex is a calcium hydroxide water-based paste for root canal dressing. It is easy to handle and the most easily removed. Its high radiopacity facilitates the radiological control during follow-up visits [30].

Patient compliance was not a concern in this study since an apical barrier was observed in a short period of 5 months and one single visit was necessary to achieve that.

## Conclusion

The case described in this report showed that a single Ca(OH)<sub>2</sub> dressing is enough to induce the apical barrier formation in immature teeth. However, this result can't be generalized. Further studies on a larger sample with long-term follow-ups are necessary to prove the efficacy of this procedure.

## References

1. Andreasen, J. O. & Ravn, J. J. Epidemiology of traumatic dental injury to primary and permanent teeth. *Int. J. Oral Surg.*, 1:235-9, 1972.
2. Kleier DJ, Barr ES. A study of endodontically apexified teeth. *Endod Dent Traumatol.* 1991;7:112-7.
3. Rafter M : Apexification: A review. *Dent Traumatol* 2005;21:1-8.
4. Dominguez Reyes A. Munoz Munoz L, Aznar Martin T. Study of calcium hydroxide apexification in 26 young permanent incisors. *Dent Traumatol* 2005;21:141-5.
5. Ghose LJ, Baghdady VS, Hikmat M. Apexification of immature apices of pulpless permanent anterior teeth with calcium hydroxide. *J Endod.* 1987;13:285-90.
6. Cvek M. Treatment of non-vital permanent incisors with calcium hydroxide: I: Follow-up of periapical repair and apical closure of immature roots. *Odontol Revy* 1972;23:27-44.
7. Feiglin B. Differences in apex formation during apexification with calcium hydroxide paste. *Endod Dent Traumatol* 1985;1:195-9. 4.
8. Magura ME, Kafrawy AH, Brown CE Jr, Newton C. Human saliva coronal microleakage in obturated root canals: An *in vitro* study. *J Endod* 1991;17: 324-31.
9. Andreasen JO, Munksgaard EC, Bakland LK. Comparison of fracture resistance in root canals of immature sheep teeth after filling with calcium hydroxide or MTA. *Dent Traumatol* 2006; 22:154-6.
10. Andreasen Joet al. Long-term calcium hydroxide as a root cannal dressing may increase the risk of root fracture. *Dent Traumatol* 2002 Jun;18 3:134-7.
11. Morse DR, O'Larnic J, Yesilsoy C. Apexification: review of the literature. *Quintessence Int* 1990; 21, 589-98.
12. Chawla HS. Apical closure in a nonvital permanent tooth using one Ca(OH)<sub>2</sub> dressing. *ASDC J Dent Child.* 1986;53:44-7.
13. Vellore KG. Calcium hydroxide induced apical barrier in fractured nonvital immature permanent incisors. *J Indian Soc Pedod Prev Dent* 2010;28:110-2.

14. Cooke C, Rowbotham TC. Root canal therapy in non-vital teeth with open apices. *Br Dent J* 1960;108:147-50.
15. Ball JS. Apical root formation in nonvital immature permanent incisor. Report of a case. *Br Dent J* 1964;116:166-7.
16. Bouchon F. Apex formation following treatment of necrotized immature permanent incisor. *J Dent Child* 1966; 33:378-80.
17. Dylewski J. Apical closures of non-vital teeth. *Oral Surg* 1971;32:82-89.
18. Lu YM, Qin JN. A comparison of the effect between Vitapex paste and antibiotic paste in apexification. *Shanghai Kou Qiang Yi Xue*. 2004;13:449-51.
19. Chawla HS, Tewari A, Ramakrishnan E. A study of apexification without a catalyst paste. *J Dent Child* 1980;47:431-4.
20. Hermann BW. Dentinobliteration der wurzelkanäle nach behandlung mit kalzium. *Zahnärztl Rundschau* 1930;39:888-90.
21. Estrela C, Pimento FC, Ito IY, et al. *In vitro* determination of direct antimicrobial effect of calcium hydroxide. *J Endod* 1988;24:15-7.
22. Jiang J, Zuo J, Chen SH, et al. Calcium hydroxide reduces lipopolysaccharide-stimulated osteoclast formation. *Oral Surg* 2003;95:348-54.
23. Sheehy EC, Roberts GJ. Use of calcium hydroxide for apical barrier formation and healing in non-vital immature permanent teeth: A review. *Br Dent J*. 1997 Oct 11;183 7:241-6.
24. Kaiser JH. Presentation to the American Association of Endodontists. Washington, DC, April, 1964.
25. Frank, AL. Therapy for divergent pulpless tooth by continued apical formation. *J Am Dent Assoc* 1966;72:87-931.
26. Chosack A, Sela J, Cleaton-Jones P. A histological and quantitative histomorphometric study of apexification of nonvital permanent incisors of vervet monkeys after repeated root filling with a calcium hydroxide paste. *Endod Dent Traumatol*. 1997; 13:211-7.
27. Vojinović O. Induction of apical formation in immature teeth by different endodontic methods of treatment. Experimental pathohistological study. *J Oral Rehabil*. 1974;1:85-97.
28. De-Deus G, Coutinho-Filho T. The use of white Portland cement as an apical plug in a tooth with a necrotic pulp and wide-open apex: a case report. *Int Endod J*. 2007;40:653-60.
29. Kinirons MJ, Srinivasan V, Welbury RR, Finucane D. A study in two centers of variations in the time of apical barrier detection and barrier position in non-vital immature permanent incisors. *Int J Paediatr Dent*. 200;11:447-51.
30. Leonardo MR, Hernandez ME, Silva LA, Tanomaru-Filho M. Effect of a calcium hydroxide-based root canal dressing on periapical repair in dogs: A histological study. *Oral Surg Oral Med Oral Pathol Oral Radiol Endod* 2006;102:680-685.

## SCIENTIFIC INTERNATIONAL MEETINGS 2013

### CONGRÉS SCIENTIFIQUES INTERNATIONAUX 2013

- Africa countries
- Australia
- Europe countries
- Far East countries
- Middle East & Arab countries
- North America countries
- South America countries

Event	Date	Location	Website
63 <sup>rd</sup> Alpine Dental Conference	13-20 January	Courchevel, France	<a href="http://www.idfdentalconference.com">www.idfdentalconference.com</a>
Dallas County Dental Society - Southwest Dental Conference	17-19 January	Dallas, TX, USA	<a href="http://www.swdentalconf.org">www.swdentalconf.org</a>
Hawaii Dental Convention	24-25 January	Honolulu, Hawaii, USA	<a href="http://www.hawaiidentalassociation.net">www.hawaiidentalassociation.net</a>
Rocky Mountain Dental Convention 2013	24–26 January	Colorado, USA	<a href="http://www.rmdconline.com">www.rmdconline.com</a>
Manitoba Dental Association - Annual Meeting & Convention	25-26 January	Winnipeg, MB, Canada	<a href="http://www.manitobadentist.ca">www.manitobadentist.ca</a>
24 <sup>th</sup> Saudi Dental Society International Dental Conference	28-30 January	KSA	<a href="http://www.sds.org.sa">www.sds.org.sa</a>
38 <sup>th</sup> Yankee Dental Congress 2013	30 January – 03 February	Boston, USA	<a href="http://www.yankeedental.com">www.yankeedental.com</a>
CIOSP 31 <sup>st</sup> Sao Paulo International Dental Meeting	31 January – 03 February	Sao Paulo, Brazil	<a href="http://www.ciosp.com.br">www.ciosp.com.br</a>
AEEDC Dubai 2013- The 17 <sup>th</sup> edition of the UAE International Dental Conference & Arab Dental Exhibition	05–07 February	Dubai, UAE	<a href="http://www.index.ae">www.index.ae</a>
American Academy of Dental Group Practice – 41 <sup>st</sup> Annual Conference & Exhibition	06-09 February	New Orleans, USA	<a href="http://www.aadgp.org">www.aadgp.org</a>
ITI Congress - France	07-09 February	Val d'Isère, France	<a href="http://www.iti.org">www.iti.org</a>
Academy of Laser Dentistry 2013 – 20 <sup>th</sup> Annual Meeting	07-09 February	Palm Springs, USA	<a href="http://www.laserdentistry.org">www.laserdentistry.org</a>
66 <sup>th</sup> Indian Dental Conference	10-13 February	Kolkata, India	<a href="http://www.ida.org.in">www.ida.org.in</a>
Imagina Dental 2013	21-23 February	Monaco	<a href="http://www.monacochannel.mc">www.monacochannel.mc</a>
Chicago Dental Society - Midwinter Meeting	21-23 February	Chicago, USA	<a href="http://www.cds.org">www.cds.org</a>