

April 2021

## Blunt trauma of the extracranial carotid arteries and its operative management

Amr Mohamed Salem

*Experimental and Clinical Surgery Department , Medical Research Institute , Alexandria University , Alexandria, Egypt, amr.salem1@yahoo.com*

Mohamed Salem

*Vascular Surgery Unit, Department of Surgery, Faculty of Medicine, Alexandria University, Egypt, mohamed\_e\_salem@hotmail.com*

Sherif Mohamed Salem

*Department of Neurosurgery, Faculty of Medicine, Alexandria University, Egypt, sherif1salem@yahoo.com*

Sameh Moustafe

*Vascular Surgery Unit, Department of Surgery, Faculty of Medicine, Alexandria University, Egypt, mostsam73@hotmail.com*

Follow this and additional works at: <https://digitalcommons.aaru.edu.jo/zumj>

---

### Recommended Citation

Salem, Amr Mohamed; Salem, Mohamed; Salem, Sherif Mohamed; and Moustafe, Sameh (2021) "Blunt trauma of the extracranial carotid arteries and its operative management," *Zagazig University Medical Journal*: Vol. 27 : Iss. 2 , Article 20.

Available at: <https://digitalcommons.aaru.edu.jo/zumj/vol27/iss2/20>

This Original Article is brought to you for free and open access by Arab Journals Platform. It has been accepted for inclusion in Zagazig University Medical Journal by an authorized editor. The journal is hosted on [Digital Commons](#), an Elsevier platform. For more information, please contact [rakan@aarj.edu.jo](mailto:rakan@aarj.edu.jo), [marah@aarj.edu.jo](mailto:marah@aarj.edu.jo), [dr\\_ahmad@aarj.edu.jo](mailto:dr_ahmad@aarj.edu.jo).



Manuscript ID ZUMJ-2011-2006 (R1)

DOI 10.21608/zumj.2020.49335.2006

**ORIGINAL ARTICLE.****Blunt trauma of the extracranial carotid arteries and its operative management**Amr Salem,<sup>1</sup> Mohamed Salem,<sup>2</sup> Sherif M. Salem,<sup>3</sup> Sameh Moustafa<sup>4</sup><sup>1</sup>Assistant Prof. of Vascular Surgery, Department of Experimental and Clinical Surgery, Medical Research Institute, Alexandria University, Egypt<sup>2</sup>Prof. of Vascular Surgery, Vascular Surgery Unit, Department of Surgery, Faculty of Medicine, Alexandria University, Egypt<sup>3</sup>Lecturer of Neurosurgery, Department of Neurosurgery, Faculty of Medicine, Alexandria University, Egypt<sup>4</sup>Assistant Prof. of Vascular Surgery, Vascular Surgery Unit, Department of Surgery, Faculty of Medicine, Alexandria University, Egypt

**Corresponding author:** Amr Salem  
 Assistant Prof. of Vascular Surgery,  
 Medical Research Institute,  
 Alexandria University, Egypt.  
 E-mail address:  
[amr.salem1@yahoo.com](mailto:amr.salem1@yahoo.com)  
 Postal address: 3 Amir Omar Street,  
 Moharam Bek, Alexandria, Egypt

Submit Date 2020-11-09  
 Revise Date 2020-12-04  
 Accept Date 2020-12-10

**ABSTRACT**

**Background:** Blunt cerebrovascular injury (BCVI) describes a spectrum of carotid arterial intimal injuries. It may cause dissection of the common carotid artery, which may evolve into a pseudoaneurysm in up to 30% of patients. The aim of this work was to study blunt trauma of the extracranial carotid arteries and its operative management.

**Methods:** Twenty one patients with blunt trauma of the extracranial carotid arteries were included; 19 patients presented with pseudoaneurysms, one patient presented with grade I irregularity of the blood vessel and one patient presented with carotid internal jugular fistula. Types of surgery were: Direct excision of the pseudoaneurysm and lateral repair, or batch graft. Excision and primary end to end anastomosis or excision and interposition graft. Carotid internal jugular fistula was treated by separation of the fistula and lateral repair of the artery and vein.

**Results:** Twenty one patients with blunt trauma to the neck, 14 were males (66.67%) and 7 were females (33.33%). The main cause of injury was road motor vehicle in (57.14%) of cases. Surgical interventions were done in (95.24%) of cases. The main indication of surgery was pseudoaneurysms in (90.48%) of cases. Wound sepsis was the main complication of surgery in (14.28%) of cases.

**Conclusions:** Trauma to the neck may result in blood vessel injury, arterial pseudoaneurysms. It should be diagnosed and treated due to its high risk of morbidity and mortality. Open surgical reconstruction of the carotid artery after excision of the pseudoaneurysm was effective and safe with less major neurologic complications.

**Keywords:** Blunt cerebrovascular injury, Carotid pseudoaneurysm, transient ischemic attack, internal carotid artery.

**INTRODUCTION**

**B**lunt cerebrovascular injury (BCVI) describes a spectrum of carotid arterial intimal injuries. These may occur as the result

of direct trauma or intimal stress from neck rotation.<sup>[1]</sup>

It was found that blunt carotid artery injury (BCAI) occurred in 1- 2.6 % of all blunt trauma

cases.<sup>[2]</sup> While, blunt extracranial carotid artery injury (BECAI) presented in approximately 1% of all blunt trauma cases.<sup>[3]</sup> The mechanisms of (BECAI) include flexion, rotation or hyperextension of the neck leading to vessel stretch injury; vessel laceration from bony fracture and direct vessel impact.<sup>[4]</sup>

The blunt injury can lead to damage of the intima, pseudoaneurysm, dissection or intramural thrombosis. All of which can cause thromboembolic events or narrowing the vessel that affect the brain blood flow.<sup>[5]</sup>

The Glasgow Coma Scale and its derived Score have been adopted worldwide for assessing the degree of impaired responsiveness in traumatic brain injury and other kinds of acute brain damage.<sup>[6]</sup>

Although blunt carotid injury (BCI) was diagnosed clinically, investigations are used to improve the outcome of the management. Duplex ultrasound, Digital subtraction angiography, computed tomography angiography (CTA) and arch aortography & its branches. US: It visualizes the flow in the carotid artery. Also, it visualizes the pseudoaneurysm and the site of its communication with the artery and detects if there is any atherosclerotic plaques in the arterial wall.<sup>[7]</sup> CT angiography: It visualizes the carotid artery showing any stenosis and showing the site of pseudoaneurysm and its communication with the artery. It shows the external compression of the artery by the pseudoaneurysm and showing any compression of the surrounding structure such as internal jugular vein, trachea and esophagus. Also, it visualizes simultaneous venous filling of the carotid internal jugular fistula.<sup>[7]</sup>

Biffi et al<sup>[8]</sup> introduced the most widely accepted grading criteria (Denver criteria) for BCI based on imaging results in 5 grades as follows: grade I, irregularity within the lumen or dissection leading to less than 25% stenosis of the vessel lumen; grade II, dissection or intramural hematoma leading to arterial stenosis greater than 25%; grade III, Pseudoaneurysm; grade IV, Complete vessel

occlusion; grade V, Vessel transection and hemorrhage.

Clinical presentation of the BCI includes arterial hemorrhage and shock, expanding cervical hematoma, cervical thrill and bruit and focal neurologic deficit (TIA, hemiparesis, Horner Syndrome and stroke).<sup>[9-11]</sup>

Treatment of BCI is to decrease injury progression, minimizing the incidence of ischemic events and improving overall survival and neurological outcomes.<sup>[12,13]</sup>

In grade I & II injuries and inaccessible sites, anticoagulant or antiplatelet drugs (Heparin & Aspirin) are effective in the absence of contraindications of anticoagulant.<sup>[12,13]</sup> Both antiplatelet and heparin drugs are equally effective in decreasing the risk of stroke and improve neurological outcome.<sup>[14,15]</sup>

In grade III pseudoaneurysm or more (grade IV & grade V) and in the accessible arteries, open surgery is the treatment of choice. Surgical approaches include: lateral repair or venous patch; excision with primary end to end anastomosis or excision with interposition graft (Saphenous or artificial).<sup>[1,16-18]</sup>

#### **Aim of the work:**

The aim of this work was to study blunt trauma of the extracranial carotid arteries and its operative management.

### **PATIENTS AND METHODS**

#### **Patients**

This study occurred within 24 months period from January 2018 to December 2019. Twenty one patients with blunt trauma of the extracranial carotid arteries were included; 19 patients presented with pseudoaneurysms, one patient presented with grade I irregularity of the blood vessel and one patient presented with carotid internal jugular fistula. All cases were admitted to The Vascular Surgery Unit in Alexandria Main University Hospital, Faculty of Medicine and Department of Experimental and Clinical Surgery, Medical Research Institute, Alexandria University, Egypt. After approval of The Ethical Committee of the Faculty of Medicine, Alexandria University, an informed consent was taken from every patient.

The study was done according to The Code of Ethics of the World Medical Association (Declaration of Helsinki) for studies involving humans.

#### **Inclusion criteria**

Patients with confirmed injury (blunt trauma) to the common carotid artery and or extracranial internal carotid artery. Patients with pseudoaneurysm of the extracranial carotid artery proved by clinical examination or CT angiography. Patients with no previous Symptoms of transient ischemic attack (TIA) or stroke.

#### **Exclusion criteria**

Patients with external carotid artery injury were excluded because the artery would be ligated. Patients with a stenosis of extracranial internal carotid or common carotid artery due to atherosclerosis. Previous CEA (Carotid endarterectomy) or stenting in the artery.

#### **Methods**

- **All patients of this study were subjected to following:**

Full history taking, thorough clinical examination, routine laboratory investigations, duplex ultrasound examination, CT angiography, DSA and arch aortography & its branches.

- **Surgical treatment of the pseudoaneurysms:**
  - Direct excision of the pseudoaneurysm and lateral repair, or batch graft (venous or artificial).
  - Excision and primary end to end anastomosis or excision and interposition graft venous or artificial.
- **Treatment of carotid internal jugular fistula** surgically by separation of the fistula and lateral repair of the artery and vein.
- **One patient with grade I treated with anticoagulant drug.**
- **Follow up of the patients for 3 months after surgical interventions.**

#### **Statistical analysis of the data:**

Data were fed to the computer and analyzed using IBM SPSS software package version 20.0. (Armonk, NY: IBM Corp) Qualitative data were described using number

and percent. Quantitative data were described using range (minimum and maximum), mean and standard deviation.

#### **RESULTS**

Over the period of two years (from January 2018 to December 2019), a total of 21 patients diagnosed with BCI due to blunt trauma of the neck were admitted to The Vascular Surgery Unit in Alexandria Main University Hospital, Faculty of Medicine and Department of Experimental and Clinical Surgery, Medical Research Institute, Alexandria University, Egypt. Their age ranged from 12-55 years with a mean of 32.95years  $\pm$  20.10. Regarding gender, 14 were males (66.67%) and 7 were females (33.33%), (**Table 1**).

The main causes of BECAIs were: Road traffic accidents (motor vehicle) 12 patients (57.14%), motor cycle crush 6 patients (28.57%), fall from height 2 patients (9.52%) and one patient fell from a horse (4.76%), (**Table 1**).

Regarding the clinical presentation of the patients with BECAIs: The main symptoms and signs were cervical thrill & bruit in (19/21, 90.48%) of patients, expanding pulsating cervical hematoma in (18/21, 85.71%) of patients and hemorrhage & shock in (2/21, 9.52%) of patients, (**Table 2**).

According to the Glasco coma scale (GCS), 19 patients had normal GCS 15/15. It represented (90.48%). One patient (1/21, 4.76%) was confused with GCS 14/15 and the other patient (4.76%) said inappropriate words with GCS 13/15.

According to the Denver criteria, Grade I irregularity within the lumen was found in one patient (1/21, 4.76 %). While, grade III pseudoaneurysms were found in (19/21, 90.48%) of patients .One patient (1/21, 4.76%) had common carotid internal jugular fistula. The fistula diagnosed by simultaneous venous filling in arteriography. Being large extensive arterial venous fistula, it was classified as grade III.

**Treatment of BECAIs:** The patient with Denver criteria Grade I (1/21, 4.76%) was treated with anticoagulant drug (heparin) for 3

months. Patients with grade III pseudoaneurysms (19/21, 90.48%): Two of them (2/21, 9.52%) were associated with hemorrhage and shock. They were treated surgically in the day of trauma by excision and primary end to end anastomosis in one patient (1/21, 4.76%), and by excision with interposition saphenous vein graft in the other patient (1/21, 4.76%). The remaining patients with pseudoaneurysms (17/21, 80.95%) were treated within 30 days from the trauma. Patients with pseudoaneurysms in common carotid artery represented (8/21, 38.10%) of total patients. Six patients of them (6/21, 28.57%) were treated by lateral repair of the common carotid artery, two patients were repaired by venous batch graft (2/21, 9.52%), (Table 3). Case 1 (Figures 1A-D) & case 2 (Figures 2 A,B).

Patients with pseudoaneurysms of the internal carotid artery represented (9/21, 42.85%) of

total patients. Seven patients of them (7/21, 33.33%) were treated by lateral repair of the internal carotid arteries, the remaining two patients; one of them (1/21, 4.76%) was treated by excision and primary end to end anastomosis. The other one (1/21, 4.76%) was treated by excision and interposition graft using saphenous vein, (Table 3).

The patient with common carotid internal jugular fistula (1/21, 4.76%) was treated by separation of the fistula and lateral repair of the artery and vein with facial batch in between. The enlarged thyroid gland disappeared and the veins were collapsed, (Table 3). Case 3 (Figures 3 A-C).

Follow up for 3 months, there was no mortality. Wound infection was in 3 cases only (14.28%). The two cases of pseudoaneurysms with hemorrhage and shock were operated upon at the day of trauma. One of them developed hemiparesis, (Table 3).

**Table 1: Demographic data of the patients with BECAIs (total N0.=21)**

Variable	No.	%
	21	100
<b>Age:</b>		
<b>Mean± SD</b>	32.95±20.10	
<b>Range</b>	12-55 years	
<b>Sex :</b>		
<b>Males</b>	14	66.67
<b>Females</b>	7	33.33
<b>Causes of BECAIs:</b>		
<b>Road motor vehicle</b>	12	57.14
<b>Motor cycle crash</b>	6	28.57
<b>Fall from height</b>	2	9.52
<b>Fell from hours</b>	1	4.76

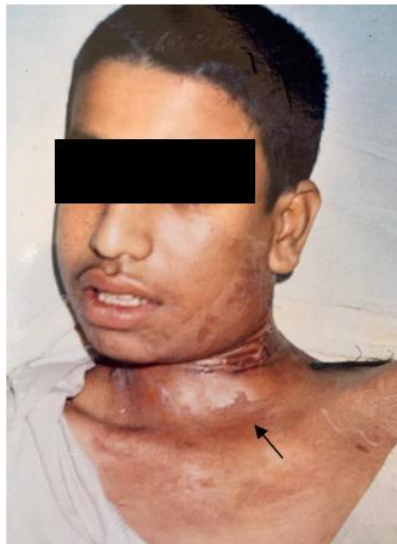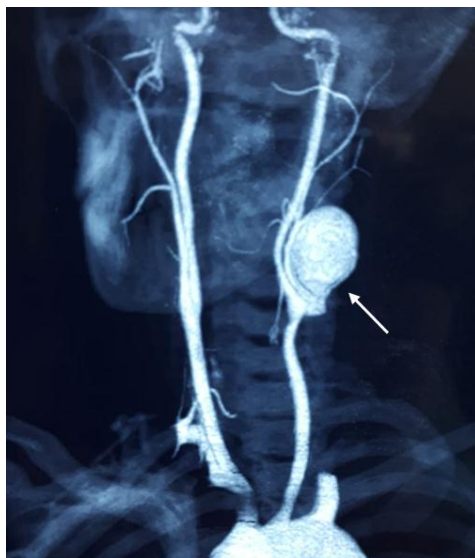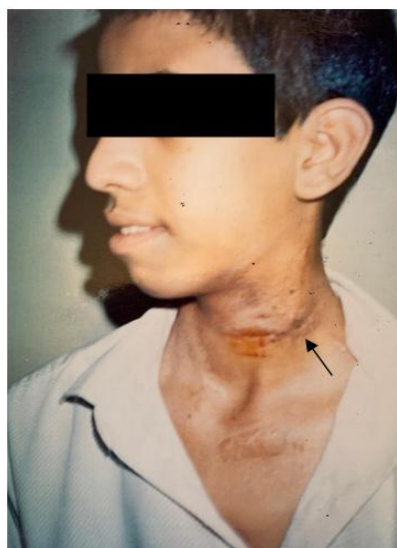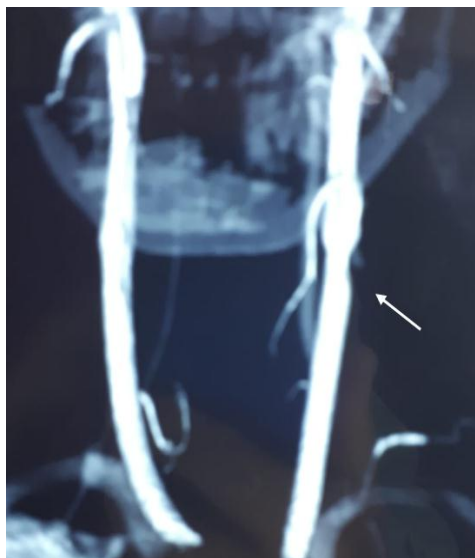
**Table 2: Clinical presentation of patients with BECAIs (total N0.=21)**

Signs & symptoms	No.	%
<b>Cervical thrill &amp; bruit</b>	19	90.48
<b>Expanding pulsating cervical hematoma</b>	18	85.71
<b>Hemorrhage &amp; shock</b>	2	9.52

**Table 3: The main indications, types of and complications of surgery in patients with BECAIs (total N0.=21)**

<b>Surgical reconstruction</b>	<b>No.</b>	<b>%</b>
<b>Operative cases</b>	<b>20</b>	<b>95.24</b>
<b>Non operative cases</b>	<b>1</b>	<b>4.76</b>
<b>Indications of surgery</b>		
Pseudoaneurysms	<b>19</b>	<b>90.48</b>
Common carotid internal jugular fistula	<b>1</b>	<b>4.76</b>
<b>Types of surgery</b>		
<b>Pseudoaneurysms without hemorrhage &amp; shock:</b>	<b>17</b>	<b>80.95</b>
<b>Common carotid artery :</b>	<b>8</b>	<b>38.10</b>
lateral repair	<b>6</b>	<b>28.57</b>
Venous batch graft	<b>2</b>	<b>9.52</b>
<b>Internal carotid artery</b>	<b>9</b>	<b>42.85</b>
lateral repair	<b>7</b>	<b>33.33</b>
Excision & primary end to end anastomosis	<b>1</b>	<b>4.76</b>
Excision and saphenous vein interposition graft	<b>1</b>	<b>4.76</b>
<b>Pseudoaneurysms with hemorrhage &amp; shock:</b>		
Excision & primary end to end anastomosis	<b>2</b>	<b>9.52</b>
Excision with interposition saphenous vein graft	<b>1</b>	<b>4.76</b>
	<b>1</b>	<b>4.76</b>
<b>common carotid internal jugular fistula:</b>		
Separation of fistula and lateral repair of the artery and vein	<b>1</b>	<b>4.76</b>
<b>Complications of surgery :</b>		
Wound sepsis	<b>3</b>	<b>14.28</b>
Hemiparesis	<b>1</b>	<b>4.76</b>



**Case 1:****Figure1A****Figure1B****Figure1 C****Figure1 D****Case 1**

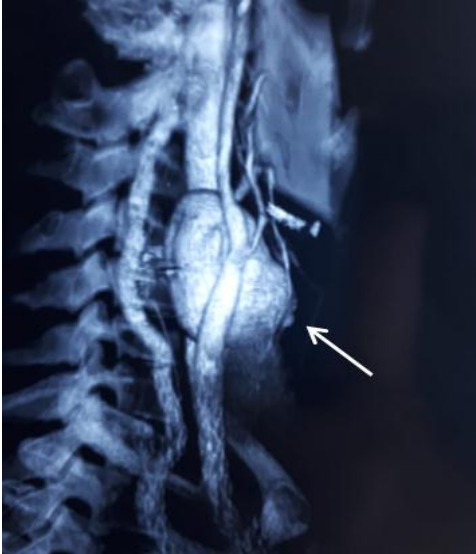
**Fig. 1A:** Pseudoaneurysm of the left common carotid artery just near to its bifurcation after blunt trauma of the left side of the neck (The arrow).

**Fig. 1B:** CTA showing pseudoaneurysm of the left common carotid artery just before its bifurcation (The arrow).

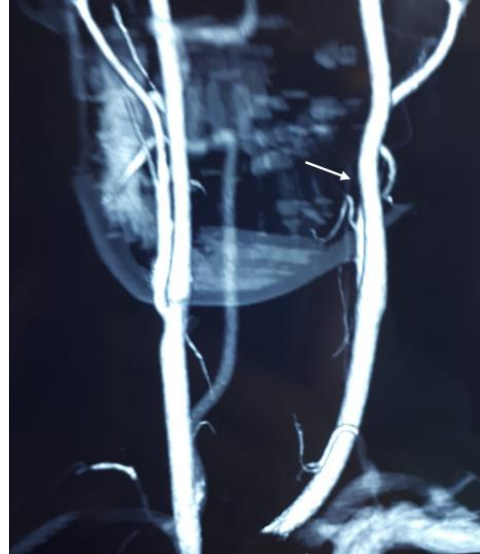
**Fig. 1C:** A scar in the left side of the neck after evacuation of the left pseudoaneurysm after lateral repair of the left common carotid artery (The arrow).

**Fig. 1D:** Postoperative CTA after one month of operation showing the left common carotid artery after lateral repair (The arrow).

**Case 2:**



**Figure 2 A**



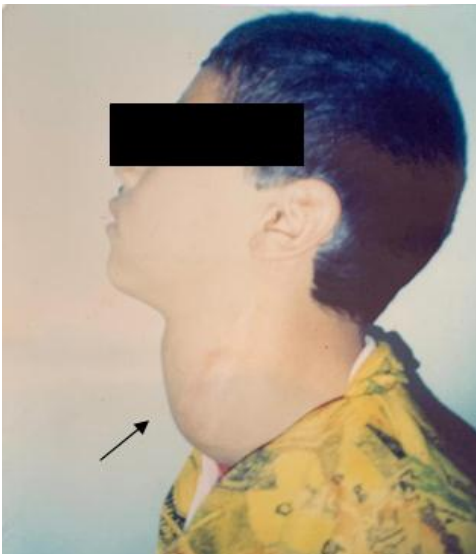**Figure 2 B**

**Case 2**

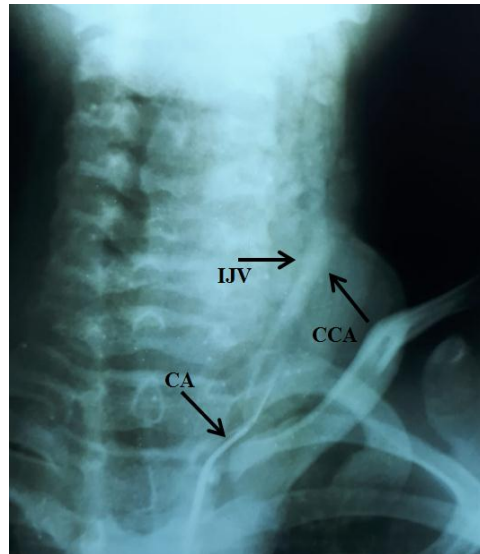
**Figure 2 A:** CT Arch aortography showing pseudoaneurysm of the left internal carotid artery at its beginning just above the bifurcation (The arrow).

**Figure 2 B:** Postoperative CTA of the left internal carotid artery after lateral repair of the artery (The arrow).

**Case 3:**

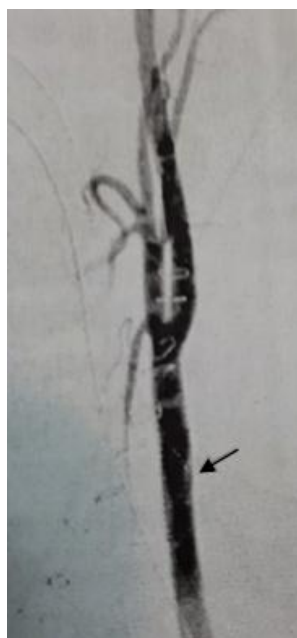

**Figure 3 A**



**Figure 3 B**





**Figure 3 C**

### Case 3

**Figure 3 A:** Blunt trauma of the left side of the neck showing enlargement of the thyroid gland due to venous congestion with thrill and bruit over the left common carotid artery due to carotid internal jugular fistula (The arrow).

**Figure 3B:** Selective left common carotid angiography showing simultaneous venous filling denoting carotid internal jugular fistula (The arrow).

CCA: Common carotid artery

IJV: Internal jugular vein

CA: Cather

**Figure 3 C:** Postoperative CTA of the left common carotid artery after separation of the fistula and lateral repair of both common carotid artery and internal jugular vein. The enlarged thyroid disappeared completely (The arrow).

### DISCUSSION

Managing BCI is an active area of investigation. Knowledge is limited to favor specific approaches to management, eg, antiplatelet against anticoagulation treatment, duration of therapy, indications for surgery, and surgical intervention. This is due to lack of researches that are able to evaluate and compare therapies while simultaneously controlling for the multitude of potentially confounding factors. For most of patients without contraindications, the corner stone of

management is antithrombotic therapy. Surgery has potential indications include failed or contraindication to medical therapy, progression of neurological symptoms and pseudoaneurysm. <sup>[5]</sup> Endovascular intervention is selectively pursued. <sup>[5,19]</sup> The endovascular intervention indications have led to mixed results and are less clear. Optimal management including timing and approach, still continues to be an active area for investigation. <sup>[5]</sup>

Blunt trauma Injuries to the carotid artery occur due to either a primary insult (eg, from

laceration or direct impact from the surrounding bony structures) or by shearing forces on the vessel that are the consequence of extension, rotation or hyperflexion of the neck<sup>[2,11,20]</sup> Initial researches on BCI revealed that prevalence was rare, occurring in only 0.1% of all blunt trauma. As radiological investigations improved, the incidence was found to be significantly higher.<sup>[7]</sup>

Several authors have commented on the limited data focused on the intervention timing. Crawford et al<sup>[21]</sup> evaluated the natural course of BCI and suggested that neurological complications would be expected within 10 to 72 hours of the trauma. In their studies, both Moulakakis et al<sup>[22]</sup> and Jacks et al<sup>[23]</sup> focused on the importance of timing as a balance of delaying intervention long enough to decrease the risk of embolization while cannulating the injured vessel, but within the time frame to prevent progression of injury. They suggested a potential benefit to delaying intervention.<sup>[5]</sup>

In the present study, regarding the degree of consciousness by GCS, 19 cases (90.48%) were normal (15/15) and one case (4.76%) was confused (14/15) and one case (4.76%) said inappropriate words (13/15). On the contrary, in Biffi et al,<sup>[12]</sup> the GCS scale was higher than in our cases. This was due to the small number of our cases, the type of trauma was not catastrophic and the associated injuries were moderate.

The demographic data in the present study; the age incidence was younger than in the literature.<sup>[5]</sup> The sex incidence in the present study; male represented 2/3 of cases ( 66.67%) which was more than in Blitzer et al. study.<sup>[5]</sup> This is because males in our country are more active and moving more in the outdoor.

Regarding the etiology of the blunt trauma of the carotid arteries in the present study, no severe trauma occurred so the complications became mild. The motor vehicle accident represented nearly ½ of the cases. The remaining cases were not severe and the associated injuries were minimal. On the contrary, in study done by Blitzer et al.,<sup>[5]</sup> the

number of cases was large, most of traumas were severe and associated with other injuries. As regard the clinical presentation in the present study, cervical thrill & bruit was the commonest presentation in more than 90.48% of cases. Only, 9.52% of patients had Hemorrhage & shock. On the contrary, in Blitzer et al.,<sup>[5]</sup> severe clinical presentation were presented. So complication of stroke, neurologic deficit were severe.

The treatment in the present study was to decrease injury progression, minimizing the incidence of ischemic events and optimizing overall survival and neurological outcomes. On the other hand, in study done by Ong and Jalaludin<sup>[24]</sup> reported that traumatic pseudoaneurysms occurred due to motor vehicle in 69% of cases and treated by excision of the pseudoaneurysm and end to end anastomosis, if there was a gap it could be interposed by graft ( synthetic or Venous ). The mortality rate was 10% and the stroke was 3% in their study.

In the present study, there was one case grade 1 treated by heparin only. Pseudoaneurysms represented the majority of our cases. 19 cases (90.48%): Two of them presented with hemorrhage, one of them treated with excision and end to end anastomosis, the second case treated by excision and interposition graft. The remaining 17 cases treated by lateral repair or venous patch or end to end anastomosis and interposition bypass graft. These results were similar to that in the study of Blitzer et al.<sup>[5]</sup> and Lauerman et al,<sup>[25]</sup>

In the present study, we faced one case of common carotid internal jugular fistula. It was treated by separation of the fistula and lateral repair of the artery and vein. Similar to the other study by Crilly et al.,<sup>[1]</sup> it was uncommon.

In the present study, no mortality was occurred. While in the study done by Blitzer et al.,<sup>[5]</sup> there were significant mortality, stroke and neurologic deficit.<sup>[5]</sup>

The complications in the present study were mild. Three cases only (14.28%) of wound

infection healed within two weeks and hemiparesis in one case (4.76%). While, in Blitzer et al.,<sup>[5]</sup> the complications were more severe including stroke, TIA, hemorrhage and wound infection. Also, Cogbill et al,<sup>[26]</sup> demonstrated mortality and stroke rates of 21% and 41% respectively in patients with internal carotid artery injuries and 11% stroke rate in those with common carotid arterial injuries.

### Conclusions

Trauma to the neck may result in blood vessel injury, arterial pseudoaneurysms and rarely carotid internal jugular fistula. It should be diagnosed and treated due to its high risk of morbidity and mortality. The present study has shown that open surgical reconstruction of the carotid artery after excision of the pseudoaneurysm was effective and safe with less major neurologic complications.

Open surgical approaches are still needed for the treatment of blunt extracranial carotid artery injuries and in patients with unfavorable lesions for endovascular intervention. Despite significant advancements in understanding carotid trauma, there is a clear need for prospective, randomized clinical studies, with large sample sizes, to address several controversies that exist in the treatment of carotid injuries.

It is necessary to provide individualized treatments to different patients according to the characteristics of the injuries.

### Declaration of interest and Funding information:

#### Conflict of interest statement:

The authors report no conflict of interest.

#### Funding source:

This research did not receive any specific grant from funding agencies in the public, commercial, or not-for-profit sectors.

### Contributors

All authors have approved the final article.

### Authorship

All authors have made equal contributions to all of the following: (1) the conception and design of the study, or acquisition of data, or analysis and interpretation of data, (2) drafting the article or revising it critically for important

intellectual content, (3) final approval of the version to be submitted.

### REFERENCES

1. Crilly S M , McElroy E, Ryan J, O'Donohue M, Lawler L P. "Mixed" trauma to the carotid artery in a mixed martial arts injury – A case report and review of the literature. *J Radiol Case Rep* 2018;12(5):1-11. doi: 10.3941/jrcr.v12i5.3234.
2. Lee TS, Ducic Y , Gordin E, Stroman D. Management of Carotid Artery Trauma Craniomaxillofac Trauma Reconstr 2014;7:175–189.
3. Schneidereit NP, Simons R, Nicolaou S, Graeb D, Brown DR, Kirkpatrick A, et al. Utility of screening for blunt vascular neck injuries with computed tomographic angiography. *J Trauma* 2006;60(1):209–215, discussion 215–216.
4. Crissey MM, Bernstein EF. Delayed presentation of carotid intimal tear following blunt craniocervical trauma. *Surgery* 1974;75(4): 543–549.
5. Blitzer DN, Ottochian M, O'Connor JV, Feliciano DV, Morrison JJ, DuBose JJ, et al. Timing of intervention may influence outcomes in blunt injury to the carotid artery. *J Vasc Surg* 2020; 71 (4):1323-1332.
6. Mattei TA, Teasdale GM. The Story of the Development and Adoption of the Glasgow Coma Scale: Part I, the Early Years. *World Neurosurg* 2020;134:311-322.
7. Tso MK, Lee MM, Ball CG, Morrish WF, Mitha AP, Kirkpatrick AW, et al. Clinical utility of a screening protocol for blunt cerebrovascular injury using computed tomography angiography. *J Neurosurg* 2017;126:1033-1041.
8. Biffi W, Moore E, Offner P, Breg K, Franciose R, Burch J. Blunt carotid arterial injuries: implications of a new grading scale. *J Trauma* 1999;47:845-853.
9. Burlew CC, Biffi WL, Moore EE, Barnett CC, Johnson JL, Bensard DD. Blunt cerebrovascular injuries: redefining screening

- criteria in the era of noninvasive diagnosis. *J Trauma Acute Care Surg* 2012;72(2):330–335, discussion 336–337, quiz 539.
10. Scheid R, Zimmer C, Schroeter ML, Ballaschke O, von Cramon DY. The clinical spectrum of blunt cerebrovascular injury. *Neurologist* 2006;12(5):255–262.
  11. Nagpal P, Policeni B, Bathla G, Khandelwal A, Derdeyn C, Skeete D. Blunt cerebrovascular injuries: advances in screening, imaging, and management trends. *Am J Neuroradiol* 2018;39:406–414.
  12. Biffi WL, Cothren CC, Moore EE, Kozar R, Cocanour C, Davis JW, et al. WesternTrauma Association critical decisions in trauma: screening for and treatment of blunt cerebrovascular injuries. *J Trauma* 2009;67(6):1150–1153.
  13. Bromberg WJ, Collier BC, Diebel LN, Dwyer KM, Holevar MR, Jacobs DG, et al. Blunt cerebrovascular injury practice management guidelines: the Eastern Association for the Surgery of Trauma. *J Trauma* 2010;68(2):471–477.
  14. Cothren CC, Moore EE, Biffi WL, Ciesla DJ, Ray CE Jr, Johnson JL, et al. Anticoagulation is the gold standard therapy for blunt carotid injuries to reduce stroke rate. *Arch Surg* 2004;139 (5):540–545, discussion 545–546.
  15. Wahl WL, Brandt MM, Thompson BG, Taheri PA, Greenfield LJ. Antiplatelet therapy: an alternative to heparin for blunt carotid injury. *J Trauma* 2002;52(5):896–901.
  16. Garg K, Rockman CB, Lee V, Maldonado TS, Jacobowitz GR, Adelman MA, et al. Presentation and management of carotid artery aneurysms and pseudoaneurysms. *J Vasc Surg* 2012;55 (6): 1618–1622. doi: 10.1016/j.jvs.2011.12.054.
  17. Abudula M, Axier A, Kadeer K, Cheng X, Dou T, Tuersun A, et al. Operative managements of extracranial carotid artery aneurysms: a report of three cases and literature review. *Chin Neurosurg J* 2018; 4:35. doi.org/10.1186/s41016-018-0143-6.
  18. Attigah N, Kulkens S, Zausig N, Hansmann J, Ringleb P, Hakimi M, et al. Surgical therapy of extracranial carotid artery aneurysms: long-term results over a 24-year period. *Eur J Vasc Endovasc Surg* 2009;37:127–133.
  19. Brommeland T, Helseth E, Aarhus M, Moen KG, Dyrskog S, Bergholt B, et al. Best practice guidelines for blunt cerebrovascular injury (BCVI). *Scand J Trauma Resusc Emerg Med* 2018;26:90. doi: 10.1186/s13049-018-0559-1.
  20. Karaolani G, Moris D, McCoy CC, Tsilimigras DI, Georgopoulos S, Bakoyiannis C. Contemporary strategies in the management of civilian abdominal vascular trauma. *Front Surg* 2018;5:7. doi: 10.3389/fsurg.2018.00007.
  21. Crawford JD, Allan KM, Patel KU, Hart KD, Schreiber MA, Azarbal AF, et al. The natural history of indeterminate blunt cerebrovascular injury. *JAMA Surg* 2015;150:841–847.
  22. Moulakakis KG, Mylonas S, Avgerinos E, Kotsis T, Liapis CD. An update of the role of endovascular repair in blunt carotid artery trauma. *Eur J Vasc Endovasc Surg* 2010;40:312–319.
  23. Jacks R, Degiannis E. Endovascular therapy and controversies in the management of vascular trauma. *Scand J Surg* 2014;103:149–155.
  24. Joo Lian Julian Ong, Salmah Jalaludin. Traumatic Pseudoaneurysm of Right Extracranial Internal Carotid Artery: A Rare Entity and Recent Advancement of Treatment with Minimally Invasive Technique. *Malays J Med Sci* 2016; 23(2): 78–81.
  25. Lauerma M, Irizarry K, Sliker C, Bruns B, Tesoriero R, Scalea T, et al. Influence of luminal stenosis in aneurismal and non-aneurysmal blunt cerebrovascular injury. *Injury* 2019;50:131–136.

26. Cogbill TH, Moore EE, Meissner M, Fischer RP, Hoyt DB, Morris JA, et al. The spectrum of blunt injury to the carotid artery: a multicenter perspective. *J Trauma* 1994;37:473-479.

**HOW TO CITE**

Salem, A., Salem, M., Salem, S., Moustafa, S. Blunt trauma of the extracranial carotid arteries and its operative management. *Zagazig University Medical Journal*, 2021; 2(364-375): -. doi: 10.21608/zumj.2020.49335.2006