

10-25-2013

Improving facial esthetics using miniscrews: a case report

Elie KHOURY

Follow this and additional works at: <https://digitalcommons.aaru.edu.jo/iajd>

Recommended Citation

KHOURY, Elie (2013) "Improving facial esthetics using miniscrews: a case report," *International Arab Journal of Dentistry*. Vol. 4: Iss. 3, Article 4.

Available at: <https://digitalcommons.aaru.edu.jo/iajd/vol4/iss3/4>

This Original Article is brought to you for free and open access by Arab Journals Platform. It has been accepted for inclusion in International Arab Journal of Dentistry by an authorized editor. The journal is hosted on [Digital Commons](#), an Elsevier platform. For more information, please contact rakan@aarj.edu.jo, marah@aarj.edu.jo, u.murad@aarj.edu.jo.

IMPROVING FACIAL ESTHETICS USING MINISCREWS: A CASE REPORT

Elie Khoury*

Abstract

The number of patients seeking treatment to improve their facial attractiveness is increasing. Nowadays orthodontic patients are requiring solutions to problems such as a minor gummy smile, a protruded lip, a posterior rotated mandible or even an open naso-labial angle. These problems are rarely all combined in one case, as biprotrusive lips are opposed to an open naso-labial angle, and solving one problem could aggravate the other.

In this case report we describe the treatment of a hyperdivergent pattern patient resulting in a posterior positioning of the mandible with lack of chin. The patient had also a dental biprotrusion creating protruded lips combined to an open naso-labial angle and a minor gummy smile. The treatment consisted in correcting the protruded lips with concern not to widen the naso-labial angle. The vertical control for the anterior chin rotation and the gummy smile correction were done using miniscrews.

Keywords : Miniscrews - naso-labial angle – gummy smile.

IAJD 2013;4(3):109-118.

AMÉLIORATION DE L'ESTHÉTIQUE FACIALE À L'AIDE DE MINIVIS: À PROPOS D'UN CAS CLINIQUE

Résumé

Le nombre de patients voulant améliorer l'esthétique du visage ne cesse d'augmenter. Les patients consultant pour un traitement orthodontique exigent, de nos jours, des solutions à des problèmes comme le sourire gingival, la biproalvéolie, un manque de menton par rotation postérieure mandibulaire ou même un angle naso-labial ouvert. Ces problèmes coexistent rarement chez un même patient puisque des lèvres protrusives vont à l'encontre d'un angle naso-labial ouvert, et la solution d'un problème pourrait aggraver l'autre.

Ce cas clinique décrit le traitement d'une patiente hyperdivergente avec une rotation postérieure de la mandibule et un manque de menton. La patiente présente aussi une biproalvéolie créant des lèvres protrusives, un angle naso-labial ouvert et un sourire gingival. Le traitement a consisté à corriger la biproalvéolie avec le souci de ne pas aggraver l'angle naso-labial. Le control vertical nécessaire pour avancer le menton et éliminer le sourire gingival a été effectué à l'aide de minivis.

Mots-clés : minivis – angle naso-labial – sourire gingival.

IAJD 2013;4(3):109-118.

* PhD,
Senior lecturer,
Dpt of Orthodontics and Dentofacial Orthopedics
Faculty of Dentistry,
Saint Joseph University of Beirut, Lebanon
khoury.es@gmail.com

Introduction

Besides aligning the teeth in order to get a beautiful smile, facial esthetics is becoming a major concern for many orthodontic patients. As a matter of fact, patients are much more aware and requiring solutions to problems such as a minor gummy smile, protrusive lips, a posterior rotated mandible or even an open naso-labial angle.

In the presence of exaggerated protrusive lips, premolars extraction is usually recommended followed by the retraction of the anterior teeth, with maximum anchorage, to prevent a forward movement of the molars [1, 2].

In contrast, for posteriorly rotated mandible cases, molar drifting is regarded as very important to obtain a control of the vertical dimension during orthodontic treatment, and therefore a forward movement of the chin [3-5].

However, many authors consider this procedure alone to be insufficient for vertical control, as all orthodontic mechanics are extrusive to some degree, which also increases the vertical dimension [6]. That is why several strategies concerning treatment mechanics have been proposed to control vertical dimensions, such as a high-pull head gear, a low palatal bar, posterior bite-blocks or even posterior magnets [5, 7, 8]. All these appliances need patient compliance in a way, and some are considered too demanding for most patients, resulting in a vertical control loss [1].

The introduction of skeletal anchorage as a source of fixed anchorage to orthodontic treatment has solved many problems including patient cooperation. Nowadays, miniscrews have become a chosen appliance for securing anchorage in clinical orthodontics [9, 10]. Because of their small dimensions, miniscrews offer many advantages such as immediate loading, multiple placement sites including interdental areas, relatively simple placement and removal, and minimal patient expenses [10]. Miniscrews are used mainly for maximum anchorage

by stabilizing the posterior teeth and pulling the anterior bloc backwards. They are also implemented for vertical control or dental intrusion especially in the presence of a gummy smile [11-13].

This case report describes the treatment of a hyperdivergent pattern patient with protruded upper and lower incisors creating a convex profile combined to a contrasted open naso-labial angle and a minor gummy smile.

Case presentation

The patient is a Lebanese girl aged 15 years 2 months. She came with her mother seeking orthodontic treatment to improve her facial esthetics. They were both aware of the protrusion of the patient's upper and lower incisors, and were bothered by her lips' protrusion and as well as her lack of chin. They also had concerns about her open naso-labial angle and her gummy smile. They confirmed that these problems were hereditary, as most of the women in the family had the same familiar characteristics.

The patient's extraoral examination showed a small deviation of the nose to the right, with a tendency towards a long face syndrome. She presented a minor gummy smile posteriorly and anteriorly. Her profile was convex, with a retrusive chin and an open naso-labial angle [Fig. 1].

Intraorally, the upper midline was deviated 0.5 mm to the right while the lower midline was on. She had class I molars and class II canines on both sides with biprotrusive incisors, no crowding on both arches, and a curve of Spee of 1.5 mm on each side of the lower arch [Fig. 2].

The lateral cephalometric analysis confirmed the hyperdivergent growth pattern (FMA= 31°), as well as the lower incisor important proclination (FMIA= 47°; IMPA= 102°), and the upper incisor significant proclination (IFPA= 118°). It also indicated a skeletal class II relation (ANB= 6.5°) due to a retrognathic mandible (SNB= 76°), while the Z angle (58.5°) conveyed

a convex profile due predominantly to the proclined lower lip combined to the retrusive chin. The panoramic radiograph showed the presence of the wisdom teeth at the crown formation stage [Figs. 3, 4].

Treatment objectives

- Correct the biprotrusive incisors and lips to get a more harmonious profile.
- Maintain the naso-labial angle since it is already wide open and the retraction of the upper lip will aggravate it.
- Improve the gummy smile.
- Control the vertical dimension and achieve a counterclockwise rotation of the mandible and the chin to ameliorate the profile and the skeletal class II.

Treatment alternatives

Three treatment options were considered:

1: Extraction of the four first premolars with maximum anchorage to correct the biprotrusion with posterior miniscrews for vertical control and anchorage control with the risk of widening the naso-labial angle.

2: Extraction of the upper first premolars and lower second premolars, with a reciprocal space closure, inducing a molar mesial drifting and an incisor rabbiting. Miniscrews will be used for vertical control and gummy smile correction.

3: Extraction of the maxillary second premolars in order to get molar drifting combined to incisor retraction, and extraction of the mandibular first premolar for incisor repositioning. An orthognathic surgery for maxillary impaction and maybe protrusion, as well as a counterclockwise rotation of the mandible, will complete the orthodontic treatment. This will correct the lips protrusion, the open naso-labial angle, the gummy smile, the chin retrusion and the vertical problem.

Option 2 was selected as it presented the best and less invasive mean for achieving our treatment objectives.




Fig. 1: Pre-treatment facial photographs.

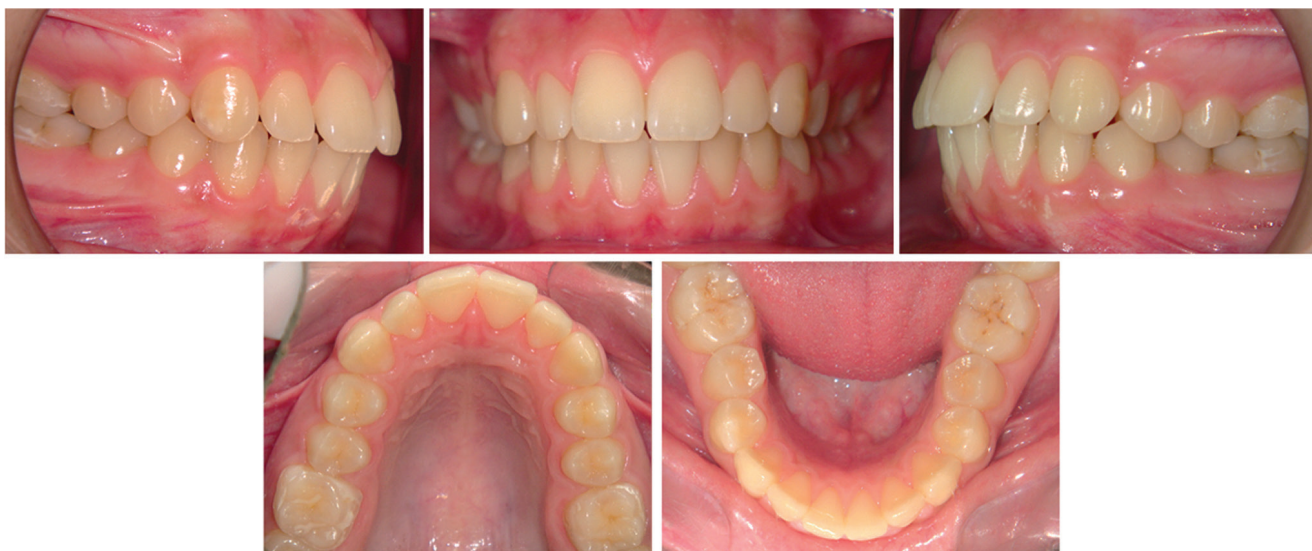

Fig. 2: Pre-treatment intra-oral photographs.

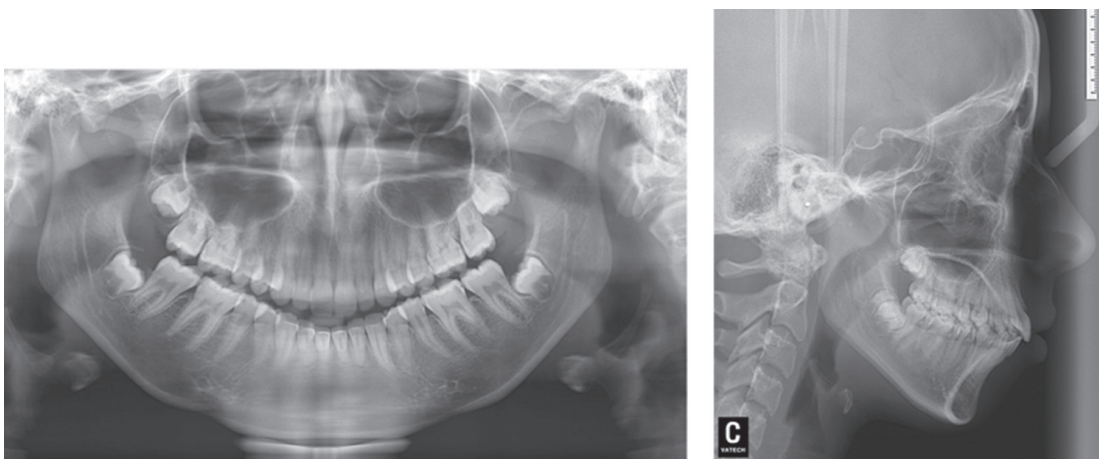


Fig. 3: Pre-treatment panoramic and lateral cephalometric radiographs.

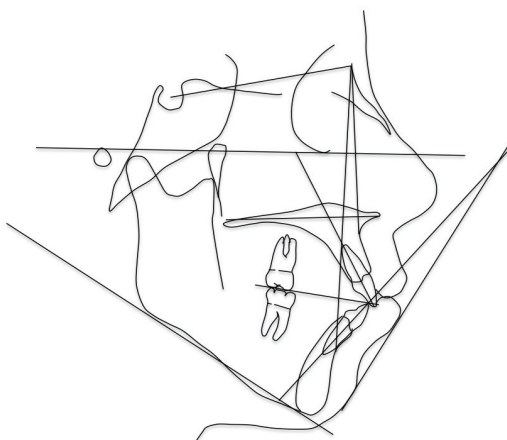


Fig. 4: Pre-treatment cephalometric analysis.

Date: 02-06-11		
NORMAL		PRE-TX
FMIA	67	47
FMA	25	31
IMPA	88	102
IFPA	107	118
SNA	82	82.5
SNB	80	76
ANB	2	6.5
AOBO	0	2
Occ. P	10	7
Z angle	75	58.5
PHF	45	39.5
AFH	65	67
Index	0.70	0.59

Treatment progress

After extracting the four premolars, both arches were bonded using .022"x.028" Roth information brackets, with bands placed on the first and second molars. The arches were leveled using .016 Nickel-Titanium (NiTi) wires then .017x.025 NiTi, followed by .019x.025 Stainless Steel (SS) wires.

In the maxillary arch, retraction of the cuspids was initiated at this stage, using power chain elastics from the second molars to the canines, then from the first molars to the canines to allow some molar mesialisation.

In the mandibular arch, retraction of the cuspids and the first premolars was also initiated on the .019x.025 SS wire, using power chain elastics from the second molars to the canines.

In the middle of the cuspids and premolars retraction, a .019x.025 SS closing wire was placed to obtain a reciprocal space closure. This closing wire helps protract the molars, while the incisors undergo a posterior rab-

biting. In the Roth brackets, the lower incisor torque is null, and the play existing between the 0.22x.028 bracket and the 0.19x.025 wire is sufficient to get a good rabbiting without torque control. Furthermore, the significant protrusion of the incisors contributes to creating a negative torque when the straight wire is introduced in the bracket slot, which helps the rabbiting procedure needed in this case [Fig. 5].

In the maxillary arch, when the cuspids were fully retracted, a .019x.025 closing loop wire was used to retract the upper incisors while creating rabbiting during space closure.

Before the end of the anterior space closure, two miniscrews (Absoanchor, Dentos, Korea) were placed between the central and the lateral incisors in the maxillary arch. The miniscrews had a diameter of 1.3 mm and a length of 8 mm; they were placed in the alveolar bone as high as possible in the attached gingiva. The miniscrews were used to intrude the anterior incisors

while retracting them, for gummy smile correction. An intrusive step was placed in the arch between the laterals incisors and the canines in order to intrude the posterior segment for better vertical control and posterior gummy smile correction [Figs. 6, 7].

At the end of space closure, vertical elastics were used in the presence of miniscrews, for a very short period of time, to seat the occlusion.

After 23 months of active treatment, fixed appliances and miniscrews were removed. Canine-to-canine lingual retainers were bonded to the maxillary and mandibular arches, and a removable retainer was placed on the upper arch as well. The patient was asked to wear her removable retainer full-time for one year and at night for as long as possible. She must consult a speech therapist to ascertain the stability of the final result. The patient was advised to come back for follow-ups every 3 months to control wisdom teeth eruption.

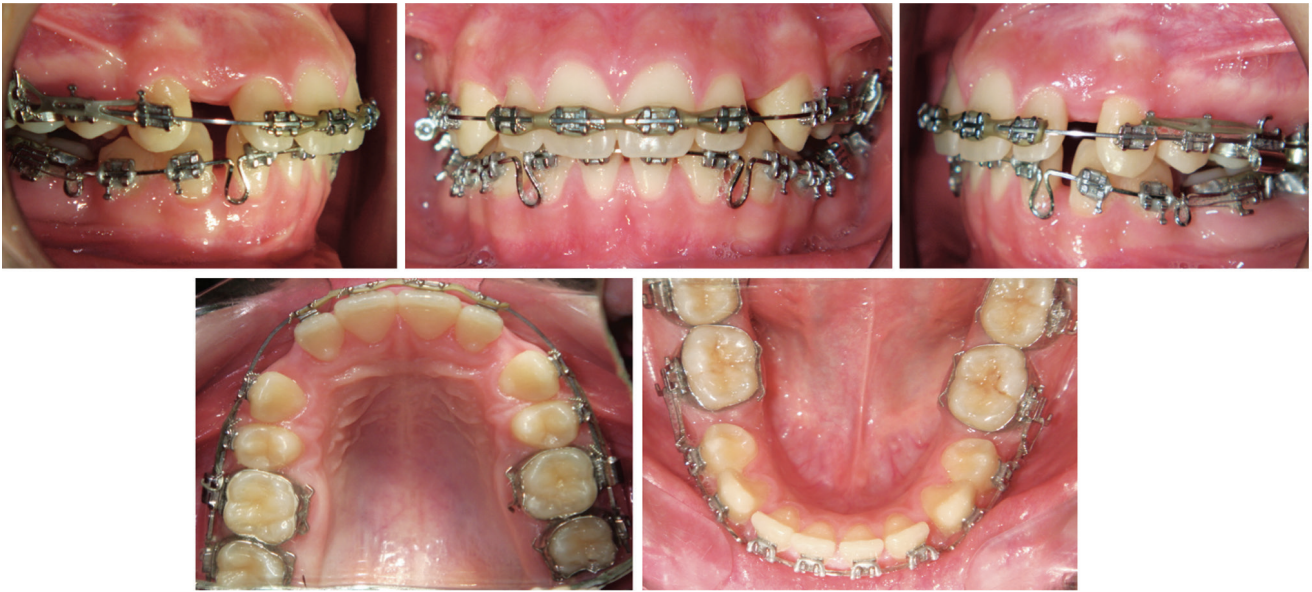

Fig. 5: Treatment progress with lower space closure and upper retraction of the cuspids.

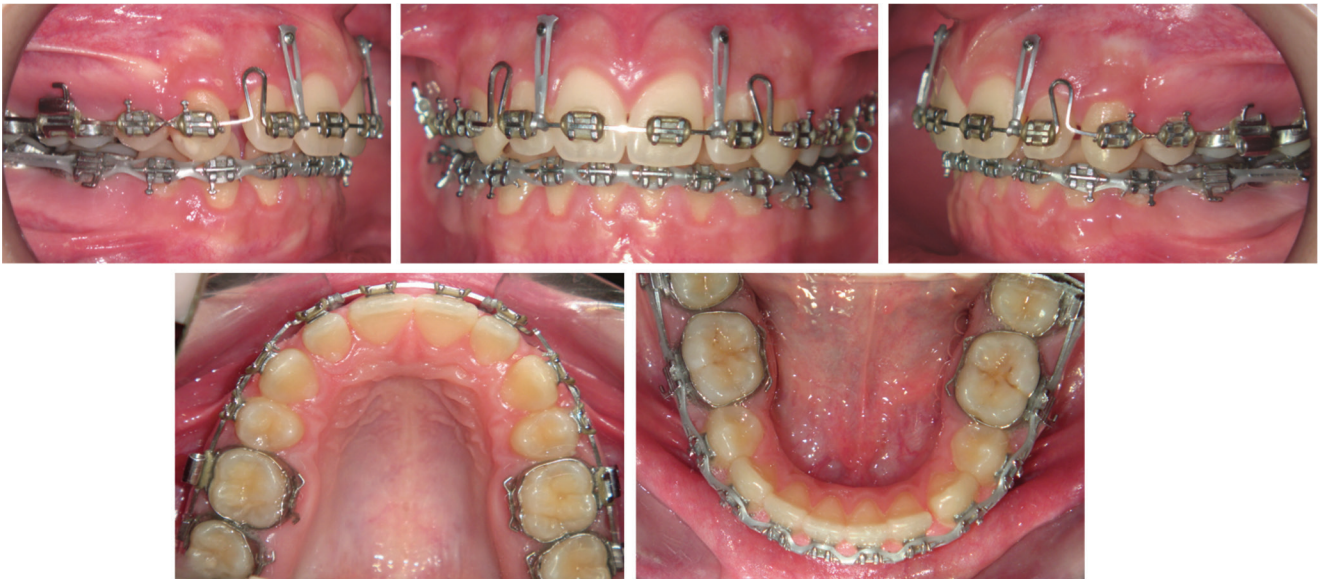

Fig. 6: Treatment progress with upper space closure, upper intrusion using miniscrews and an upper intrusive posterior step between laterals and cuspids.

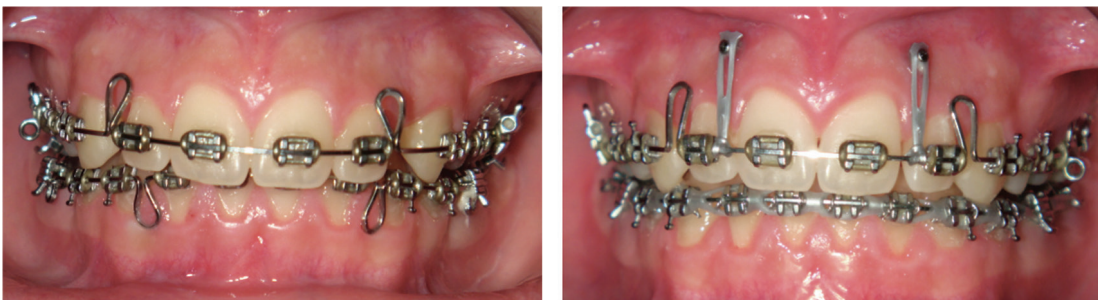

Fig. 7: Amount of intrusion using miniscrews with the upper intrusive posterior step.



Fig. 8: Post-treatment facial photographs.

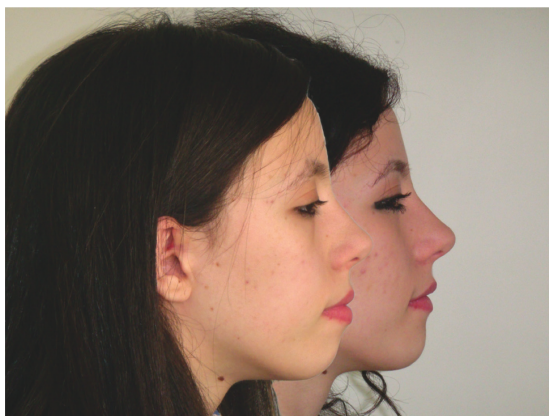

Fig. 9: Facial lateral profile composite.

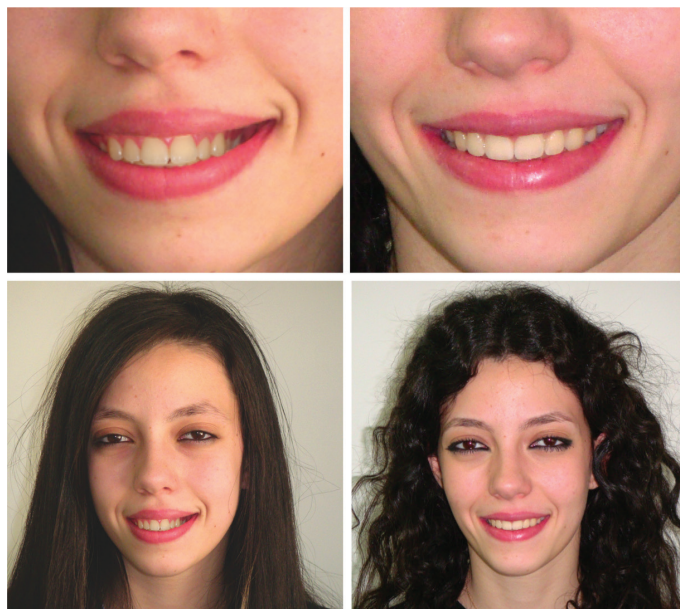

Fig. 10: Smile changes before and after treatment. The patient is smiling and not laughing to the maximum.

Treatment result

Treatment resulted in a facial esthetic improvement. The lips were retracted leading to a better harmonious profile. The patient did not show any significant mandibular growth; however, a forward and anterior movement of the chin was observed due to the vertical control. The minor gummy smile was also corrected using miniscrews and the teeth became more consonant with the smile line. Finally, the naso-labial angle was not altered, but was retained in its original dimen-

sion, in respect to the treatment objectives [Figs. 8, 9 and 10].

Intraorally, both upper and lower incisors were retracted and tipped backward while the molars on both arches encountered a mesial movement. Upper central incisors were intruded. Class I canine was achieved with normal overjet and overbite and good interdigitation between the dental arches. No interference was noted in the protrusion and laterality [Fig. 11].

The lateral cephalometric radiograph analysis confirmed the upper

incisor retraction as IFPA was reduced from 118° to 106° mainly by backward tipping, as well as the uprighting of the lower incisors (IMPA decreased from 102° to 92°). The skeletal Class II was improved mainly by a mandibular forward repositioning (ANB changed from 6.5° to 5°). While the maxillary position did not change (SNA = 82.5° before and after treatment) the mandible encountered a forward movement (SNB changed from 76° to 77.5°). The vertical dimension was controlled with a counterclockwise rotation of the mandible as FMA was reduced from

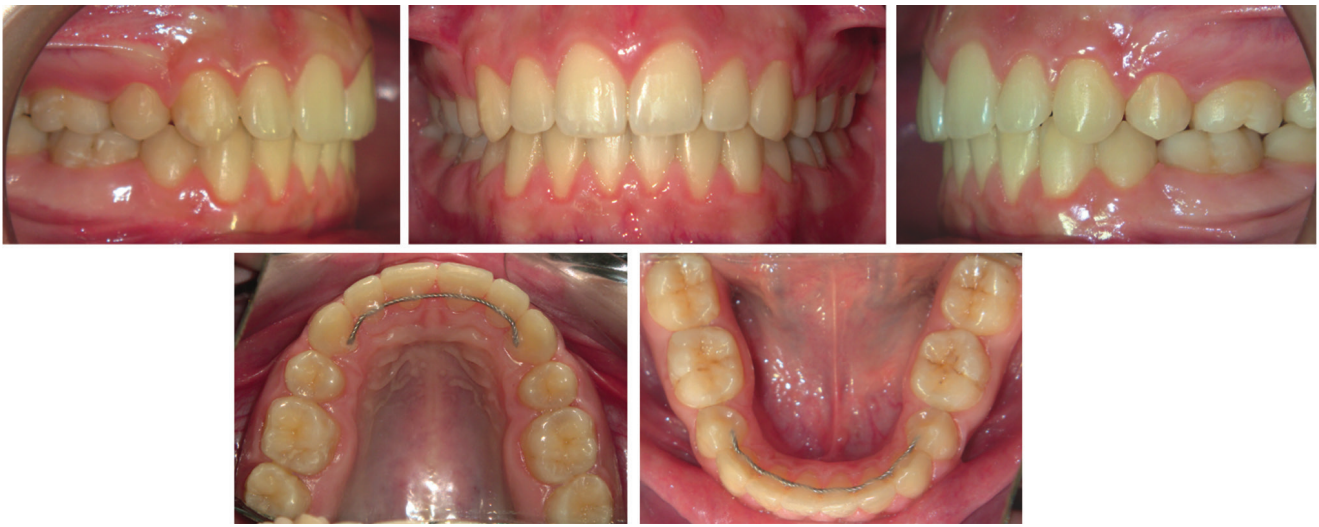

Fig. 11: Post-treatment intra-oral photographs.

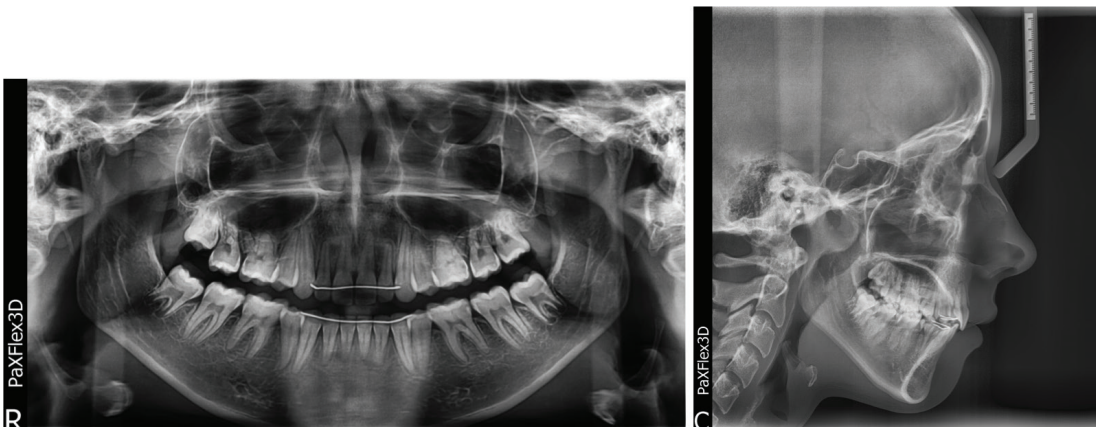


Fig. 12: Post-treatment panoramic and lateral cephalometric radiographs.

31° to 29°, while the Z angle changed from 58.5° to 68° due to the counter-clockwise rotation of the chin and to the retraction of the lips. The final panoramic radiograph showed the eruption of the third molars, an acceptable root parallelism and no root resorption [Figs. 12, 13].

The superimposed cephalometric tracings affirmed that the molars moved mesially while the upper incisors were uprighted and slightly intruded and the lower incisors were uprighted. Moreover, a forward and

upward movement of the chin was registered [Figs. 14, 15].

Discussion

A successful orthodontic treatment relies on both the antero-posterior and the vertical positions of the maxillary incisors that are crucial for facial esthetics. In existing gummy smile cases, extractions for incisor retraction are not recommended since previous experiments have demonstrated that incisor retraction might lead to the

extrusion of the anterior segment, thus increasing the gummy smile [9].

In these cases, an intrusive force is usually applied in the anterior segment; however, this will create an extrusive force in the posterior segment during retraction of the incisors [13, 14].

Extrusive forces on the posterior segment can be detrimental, especially in hyperdivergent cases. Hence, reliable retraction mechanics that induce controlled intrusion and retraction in the anterior segment, without significant extrusion of the poste-

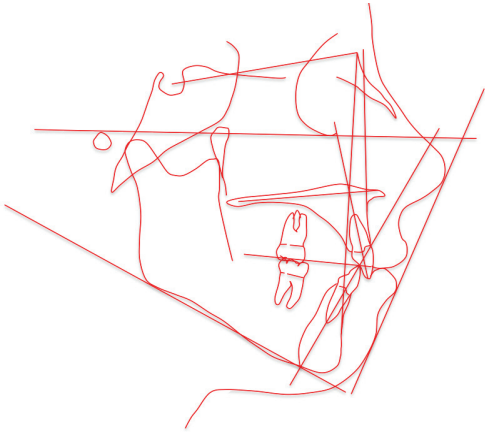


Fig. 13: Post-treatment cephalometric analysis.

Date: 16-05-13		
NORMAL		POST-TX
FMIA	67	59
FMA	25	29
IMPA	88	92
IFPA	107	106
SNA	82	82.5
SNB	80	77.5
ANB	2	5
AOBO	0	5
Occ. P	10	5
Z angle	75	68
PHF	45	40
AFH	65	66
Index	0.70	0.61

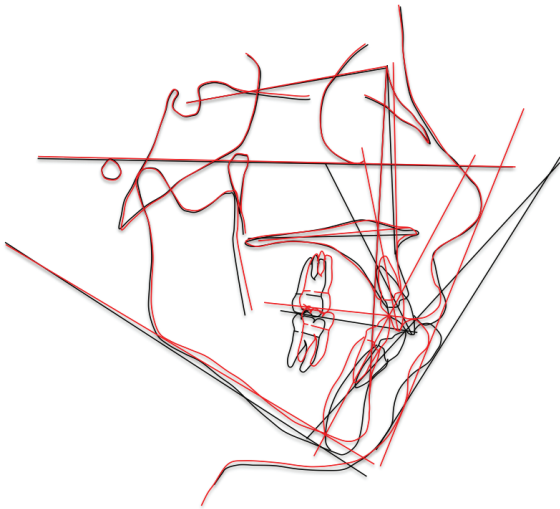

Fig. 14: Cephalometric tracing superimposition on SN at S.

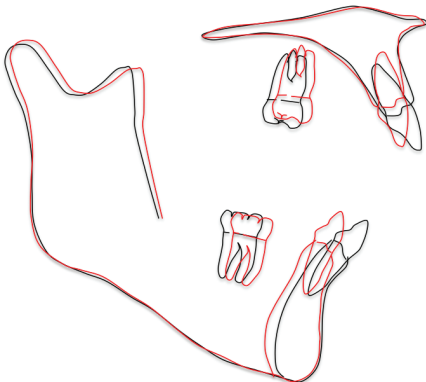
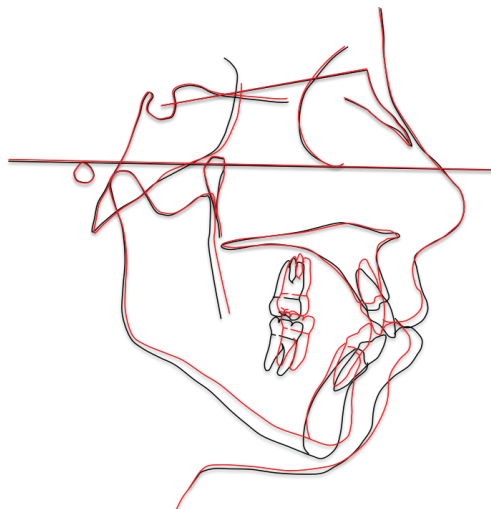


Fig. 15: Maxillary superimposition on ENA-ENP at ENP and mandibular superimposition on MP at Me.

rior segment, might be favored when dealing with vertical problems, such as a hyperdivergent face combined with a gummy smile. These mechanics include miniscrews anteriorly or posteriorly, or even both.

In our case, we decided to use miniscrews anteriorly only, with intrusive steps posteriorly to counteract any extrusive movement that might occur in order to get a good vertical control.

In the presence of a gummy smile, such the one presented, anterior titanium screws are usually placed in the dento-alveolar region between the central and lateral incisors, not only to control the extrusion movement, but also to intrude incisors and to correct the gummy smile.

To achieve intrusion, the miniscrews should be placed as high as possible where the inter-root distance becomes wider, otherwise the screws might touch the roots during the intrusion and cause undesirable root resorption or screw failure [15-17]. However, the miniscrews should not be placed higher than the attached gingiva, as the success rate of miniscrews implanted in the mucosa is lower than what it would have been if the miniscrews were implanted in the attached gingiva [17, 18]. Additionally, when placed in the oral mucosa, the miniscrews could be easily covered by this mucosa, causing inflammation [15].

In this hyperdivergent pattern, skeletal class II and dental biprotrusion case, extraction of the upper first premolars was considered in order to correct the incisors upper protrusion without anchorage control. In turn, the molars were supposed to have a mesial movement to help in closing the bite, and the incisors were supposed to have a controlled backward tipping in order not to have any changes in point A of the maxilla. We were very vigilant in trying to retract the upper incisors without torque control. This will correct the protrusion without retracting the alveolar bone that supports the upper lip, to insure, as much as pos-

sible, the stability of the naso-labial angle. As a matter of fact, the presence of biprotrusive lips that were bothering the patient, in combination with an open naso-labial angle, complicated the treatment.

The key to the success in this case was the ability to correct the profile without altering the naso-labial angle, in addition to having a good vertical control. That is why the decision of low anchorage control was taken in the upper and lower arches; for this purpose, the miniscrews were placed in the anterior segment to intrude the incisor while retracting. The intrusive step placed between the anterior and the posterior segment provided a sufficient posterior vertical control while moving the molars forward. This vertical control led to a counterclockwise rotation of the mandible bringing the chin to a much better position. Moreover, the anterior positioned miniscrews helped in correcting the gummy smile and in achieving a more harmonious smile.

It would have been desirable, in this case, to upright more the lower incisors, to align them more with the criteria of facial balance and harmony in high-angle patients established by Klontz [19]. Nevertheless, this uprighting would have been at the expense of the molar mesialisation. This molar mesialisation, along with the good vertical control, have helped in closing the bite, in addition to creating a posterior space for the third molars, consequently contributing to the achievement of a much less aggressive treatment of eight teeth extractions.

Conclusion

Before the invention of miniscrews, the success rate of complicated clinical cases was mostly related to patient cooperation, and the treatment plans were sometimes very aggressive in terms of extractions or combined orthognathic surgery. Nowadays, with the use of miniscrews, the cases are becoming much more controllable. Nevertheless, a good diagnosis and

treatment planning should be established and followed in order to obtain a good balance between the different solutions, since sometimes solving a certain problem can aggravate another existing situation.

References

1. Yao C, Lai E, Chang J, Chen I, Chena Y. Comparison of treatment outcomes between skeletal anchorage and extraoral anchorage in adults with maxillary dentoalveolar protrusion. *Am J Orthod Dentofacial Orthop* 2008;134:615-24.
2. Chae JM. A new protocol of Tweed-Merrifield directional force technology with microimplant anchorage. *Am J Orthod Dentofacial Orthop* 2006;130:100-9.
3. Haralabakis NB, Sifakakis IB. The effect of cervical headgear on patients with high or low mandibular plane angles and the "myth" of posterior mandibular rotation. *Am J Orthod Dentofacial Orthop* 2004;126:310-7.
4. Kim TK, Kim JT, Mah J, Yang WS, Baek SH. First or second premolar extraction effects on facial vertical dimension. *Angle Orthod* 2005;75:177-82.
5. Gkantidis N, Halazonetis D, Alexandropoulos E, Haralabakis N. Treatment strategies for patients with hyperdivergent Class II Division 1 malocclusion: Is vertical dimension affected? *Am J Orthod Dentofacial Orthop* 2011;140:346-55.
6. McLaughlin RP and Bennett JC. The extraction -non extraction dilemma as it relates to TMD. *Angle Orthod* 1995;65:175-86.
7. Deguchi T, Kurosaka H, Oikawa H, Kuroda S, Takahashi I, Yamashiro T, Takano-Yamamoto T. Comparison of orthodontic treatment outcomes in adults with skeletal open bite between conventional edgewise treatment and implant-anchored orthodontics. *Am J Orthod Dentofacial Orthop* 2011;139:S60-8.
8. Heravi F, Bayani S, Madani AS, Radvar M, Anbiaee N. Intrusion of supra-erupted molars using miniscrews: Clinical success and root resorption. *Am J Orthod Dentofacial Orthop* 2011;139:S170-5.
9. Lee KJ, Park YC, Hwang CJ, Kim YJ, Choi TH, Yoo HM, Kyunge SH. Displacement pattern of the maxillary arch depending on miniscrew position in sliding mechanics. *Am J Orthod Dentofacial Orthop* 2011;140:224-32.
10. Polat-Ozsoy O, Arman-Ozcirpici A, Veziroglu F, Cetinsahin A. Comparison of the intrusive effects of miniscrews and utility arches. *Am J Orthod Dentofacial Orthop* 2011;139:526-32.
11. Polat-Ozsoy O, Arman-Ozcirpici A, Veziroglu F. Miniscrews for upper incisor intrusion. *Eur J of Orthod* 2009;31:412-416.
12. Deguchi T, Murakami T, Kuroda S, Yabuuchi T, Kamioka H, Takano-Yamamoto T. Comparison of the intrusion effects on the maxillary incisors between implant anchorage and J-hook headgear. *Am J Orthod Dentofacial Orthop* 2008;133:654-60.
13. Davoody AR, Posada L, Utreja A, Janakiraman N, Neace W, Uribe F, Nanda R. A prospective comparative study between differential moments and miniscrews in anchorage control. *Eur J Orthod* 2012;16:1-9.
14. Melsen B, Fotis V, Burstone CJ. Vertical force considerations in differential space closure. *J Clin Orthod* 1990;24:678-83.
15. Ishahara Y, Kurado S, Sugawara Y, Balam T, Tekano-Yamamoto T, Yamashiro T. Indirect usage of miniscrews anchorage to intrude overerupted mandibular incisors in a Class II patient with deep overbite. *Am J Orthod Dentofacial Orthop* 2013;143(4):S113-24.
16. Kravitz ND, Kusnoto B. Risks and complications of orthodontic miniscrews. *Am J Orthod Dentofacial Orthop* 2007;131:S43-51.
17. Kuroda S, Yamada K, Deguchi T, Hachimoto T, Kyung HM, Takano-Yamamoto T. Root proximity is a major factor for screw failure in orthodontic anchorage. *Am J Orthod Dentofacial Orthop* 2007;131:S68-73.
18. Cheng SJ, Tseng IY, Lee JJ, Kok SH. A prospective study of the risk factors associated with failure of mini-implants used for orthodontic anchorage. *Int J Oral Maxillofac Implants* 2004;19:100-6.
19. Klontz HA. Facial Balance and Harmony: An attainable objective for the patient with a high mandibular plane angle. *Am J Orthod Dentofacial Orthop* 1998;114:176-88.