

10-14-2014

## Comparison between conventional and nano-composite veneered stainless steel crowns: a pilot study

Nabih RASLAN

Abdul Wahab Wahab NOURALLAH

Hiba MAROOF

Follow this and additional works at: <https://digitalcommons.aaru.edu.jo/iajd>

---

### Recommended Citation

RASLAN, Nabih; Wahab NOURALLAH, Abdul Wahab; and MAROOF, Hiba (2014) "Comparison between conventional and nano-composite veneered stainless steel crowns: a pilot study," *International Arab Journal of Dentistry*. Vol. 5: Iss. 3, Article 3.

Available at: <https://digitalcommons.aaru.edu.jo/iajd/vol5/iss3/3>

This Original Article is brought to you for free and open access by Arab Journals Platform. It has been accepted for inclusion in International Arab Journal of Dentistry by an authorized editor. The journal is hosted on [Digital Commons](#), an Elsevier platform. For more information, please contact [rakan@aar.edu.jo](mailto:rakan@aar.edu.jo), [marah@aar.edu.jo](mailto:marah@aar.edu.jo), [u.murad@aar.edu.jo](mailto:u.murad@aar.edu.jo).

# COMPARISON BETWEEN CONVENTIONAL AND NANO-COMPOSITE VENEERED STAINLESS STEEL CROWNS: A PILOT STUDY

Nabih Raslan \* | Abdul Wahab Nourallah \*\* | Hiba Maroof \*\*\*

## Abstract

The aims of this pilot study were to evaluate the gingival health and the alveolar bone resorption around stainless steel crowns veneered with nano-composite as compared to conventional stainless steel crowns, in addition to evaluating parental satisfaction with the veneered crowns.

The sample studied was comprised of 10 patients who received 32 stainless steel crowns: 16 conventional crowns and 16 crowns that have been veneered with the nano-composite (Tetric EvoCeram®) using the ceramic repair system (Ceramic Repair, Intro Pack, Ivoclar Vivadent). The split-mouth design was used in this study. Each patient randomly received both types of crowns on two or four contralateral lower molars. A clinical and radiographic evaluation of the crowns was carried out after 1, 3 and 6 months and the following parameters were evaluated: simplified oral hygiene index, gingival index, crown marginal extension, crown marginal adaptation - both clinical and radiographic -, contact areas, alveolar bone resorption, as well as the level of parental satisfaction using the Likert type scale.

All the crowns were intact after six months; no statistically significant differences were noticed between the conventional crowns and the esthetic crowns for all the parameters examined. A statistically significant correlation was found between oral hygiene and gingivitis in all observations; also, a statistically significant correlation was found between the radiographic marginal adaptation and gingivitis at the third follow-up only ( $p=0.034$ ). Overall parental satisfaction with the esthetic stainless steel crowns was high. Veneering the posterior stainless steel crowns with a nano-composite could be regarded as a good technique for improving the esthetic aspects of stainless steel crowns with a high rate of parental satisfaction and without any negative effects on the gingival tissue.

**Keywords:** Conventional stainless steel crowns - esthetic stainless steel crowns – veneering – nano-composite.

IAJD 2014;5(3):108-116.

# COMPARISON BETWEEN CONVENTIONAL AND NANO-COMPOSITE VENEERED STAINLESS STEEL CROWNS: A PILOT STUDY

## Résumé

Les objectifs de cette étude pilote étaient d'évaluer la santé gingivale et la résorption de l'os alvéolaire autour des coiffes pédodontiques esthétiques par rapport aux coiffes pédodontiques conventionnelles en acier inoxydable, en plus d'évaluer la satisfaction des parents avec les couronnes esthétiques.

L'échantillon étudié était composé de 10 patients qui ont reçu 32 couronnes en acier inoxydable: 16 coiffes conventionnelles et 16 coiffes recouvertes par le nano-composite (Tetric EvoCeram®) en utilisant le système de réparation de la céramique (Ceramic Repair, Intro Pack, Ivoclar Vivadent). Chaque patient a reçu de manière aléatoire les deux types de coiffes sur deux ou quatre molaires inférieures controlatérales. Une évaluation clinique et radiographique des coiffes a été réalisée après 1, 3 et 6 mois et les paramètres suivants ont été observés: l'indice simplifié de l'hygiène orale, l'indice gingival, l'extension et l'adaptation marginale des coiffes - à la fois clinique et radiologique -, les zones de contact, la résorption alvéolaire osseuse, ainsi que le niveau de satisfaction des parents. Toutes les coiffes étaient intactes après six mois; aucune différence statistiquement significative n'a été retrouvée entre coiffes conventionnelles et esthétiques pour tous les paramètres examinés. Une corrélation statistiquement significative a été observée entre l'hygiène bucco-dentaire et la gingivite; aussi, une corrélation statistiquement significative a été retrouvée entre l'adaptation marginale évaluée radiologiquement et la gingivite lors du troisième suivi uniquement ( $p = 0,034$ ). La satisfaction des parents ayant reçu les couronnes esthétiques était élevée.

**Mots-clés:** coiffes pédodontiques en acier inoxydable – coiffes pédodontiques esthétiques - nano composite.

IAJD 2014;5(3):108-116.

\* Instructor,  
Dpt of Pedodontics,  
Faculty of Dentistry, Tishreen  
University, Lattakia, Syria

\*\* Instructor,  
Dpt of Pedodontics,  
Faculty of Dentistry, Tishreen  
University, Lattakia, Syria

\*\*\* Postgraduate student,  
Dpt of Pedodontics,  
Faculty of Dentistry, Tishreen  
University, Lattakia, Syria  
seadaughterr@hotmail.com

## Introduction

Preformed stainless steel crowns were first introduced in 1947 by the Rocky Mountain Company and became common by Humphrey in 1950 [1]. Since then, stainless steel crowns have become an invaluable restorative technique for badly decayed and deteriorated deciduous teeth [2].

Although the readily available stainless steel crowns are the most durable form of restoration for primary teeth when complete coverage is required, they are the least attractive in terms of appearance [3]. Jacob Lee has pointed out that the main drawback of using the stainless steel crowns is their unsightly metallic appearance [4]. In fact, the esthetic aspects of these metallic crowns are a major source of concern for most of the patients' parents [5].

The esthetic stainless steel crowns represent a successful remedial approximation for the purpose of improving the esthetic aspects of the conventional stainless steel crowns and in turn parental satisfaction while preserving their benefits, such as the ease of fitting them, their stability and longevity [6].

Currently, several types of esthetic stainless steel crowns are commercially available for restoring temporary molars: Nu Smile® crowns, Dura Crowns, Cheng Crowns and Kinder Crowns. Yet all of these types have many disadvantages that limit their widespread use such as the need of an extensive occlusal reduction to accommodate the thicker esthetic crowns [7] and the difficulty to crimp the buccal margins to avoid fracturing the esthetic veneer, thus the appropriate contouring of the margins cannot be achieved [3, 4, 6, 8-10]. They can also lead to poor gingival health [8], the end cosmetic result is not always pleasing for the parents [8] and the dentist does not have much choice regarding the shade of the crowns [3]. Moreover, the impact of heat sterilization on the shear bond strength of these materials is unknown and there is a risk of chipping or complete loss of the esthetic

facing with the passing of time [3]. In addition to all of the above, they are highly costly [6, 9, 11].

Methods of bonding the composite to the stainless steel crowns within the dental clinic in order to obtain a veneer similar to that of the teeth have been described [3]. Mechanical and chemical bonding of restorative materials to the stainless steel crowns (SSC) as a chair-side technique can present many advantages: ease of preparation, variety of shade selection, ease of contouring and finishing the crown margins before bonding to avoid veneering fracture and heat sterilization after unsuccessful try-ins [12]. In addition, the development of modern nanomaterials and ceramic repair materials provides a greater esthetic aspect as well as enhanced strength and longevity [13, 14].

No previous clinical studies have tested veneering stainless steel crowns for primary molars with a nanocomposite. Several earlier published laboratory studies have recommended conducting clinical studies on the subject, and herein is the importance of our study. Thus, the aims of our study were to:

- Clinically evaluate the gingival health around the crowns with esthetic veneers as compared to its status around the conventional crowns in follow-ups after 1, 3 and 6 months.
- Radiographically evaluate the resorption of the alveolar bone after 1, 3 and 6 months.
- Evaluate the parental satisfaction with the esthetic stainless steel crowns.

## Materials and methods

Our study used the split-mouth design; the sample comprised 10 children (5 boys and 5 girls) who visited the Pedodontics Department in Tishreen University, Syria. The patients had primary, mandibular molars in need of restoration using at least two stainless steel crowns on both sides of the mouth. The number of treated molars in the sample was 32 molars. The clinical

follow-up for the treated molars was carried out after one, three and six months. An evaluation of parental satisfaction with the treatment was carried out after eight months.

The molars had to meet the following clinical and radiographic criteria:

- 1- The need for restorative treatment using stainless steel crowns.
- 2- They were not mobile, submerged and no fistulae were present.
- 3- The upper opposing tooth to the included molar was either caries free or has been appropriately restored.
- 4- The molars were in contact with at least one molar either mesially in the case of the second primary molar or distally in the case of the first primary molar [8].
- 5- There was no periapical or intraradicular radiographic transparency.
- 6- Type of occlusion: Angle Class I for mixed dentition, and Flush or mesial step for primary dentition.

Conventional examination and clinical instruments were used: dental syringe, long and short needle heads, rubber dam pack, high speed turbine, spiral shaped burs, candle flamed burs in appropriate sizes, thickness meter, gingival probe, carbon biting paper self developing radiographic films, air prophy unit, aluminum oxide (Al<sub>2</sub>O<sub>3</sub>) sand (Sablare, sandblasting material, Astar, 60µ), halogen light curing device (Cromalux 75), soft material filling device, diamond composite finishing burs, rubber finishing heads, glass polishing discs.

The materials comprised:

Analgesic ampules, articaine hydrochloride 4% with 1:100,000 epinephrine.

Stainless steel crowns (3M Crowns, Stainless Steel Primary Molar, 3M Dental products, St. Paul, USA).

Luting cement (Vivaglass, Ivoclar Vivadent, Germany).

Ceramic repair system (Ceramic Repair, Intro Pack, Ivoclar Vivadent, Liechtenstein). It is a relatively new repair system and is specially designed for cosmetic repair of composite veneers, ceramic and all ceramic restorations. It can be used directly within

the oral cavity [15]. The packet is composed of:

Tetric EcoCeram®-light-curing nano-hybrid composite.

Monopaque® light -curing opaque to mask exposed metal surfaces.

Monobond® Plus primer promoting an adhesive bond between luting composites and all indirect restorative materials.

Heliobond light-curing bonding agent.

### Research methodology

A clinical and radiographic examination was conducted on the molars to ensure their compliance with the study's criteria. A separate form was filled for every tooth that is being treated with a stainless steel crown. In addition to personal information, the following details were recorded: date of the first clinical examination, occlusion type, condition of the opposing teeth, incidence of bruxism or lack thereof, simplified oral hygiene index (OHIs) according to Green and Vermillion (1964), gingival index (GI) for the teeth being treated.

The simplified oral hygiene index (OHIs) was measured for the following six teeth (51, 55, 65, 71, 75 and 85) for primal occlusion. As for mixed occlusion, the following teeth were examined (54, 61, 26, 75, 82 and 46) [15] by probing the buccal surfaces of the examined teeth and recording the results:

0= no debris,

1= soft debris covering less than a third of the tooth are present,

2= soft debris covering more than a third but less than two thirds of the tooth are present, 3= soft debris covering more than two thirds of the tooth are present.

Oral health was classified as good if the evaluation was 0 to <1, fair for values 1 to <2 and poor for values 2-3.

The gingival index (GI) according to Robinson (1980) [16] was used to evaluate the gingival health around the stainless steel crowns in a study by Sharaf and Farsi [17]. The GI values

were reported for every crowned tooth depending on the following scores:

0= no bleeding,

1= only one bleeding point appearing some seconds after probing,

2=bleeding points appearing immediately after probing,

3= profuse bleeding appearing immediately after probing, spreading towards the marginal gingiva.

The split-mouth design was used as all the conventional and the esthetic crowns would be subjected to similar oral environment and health habits. Moreover, the type of crown to be placed on the tooth was randomly allocated so that one of the molars received a conventional crown while the other contralateral received an esthetic crown. Teeth on the same side were crowned in the same session. The contralateral teeth were prepared in another session with no more than a week between the sessions in order to minimize the child's discomfort.

After applying a local analgesic, fitting a rubber dam and performing the necessary dental treatment, the molars were prepared to receive the conventional and esthetic stainless steel crowns using the same procedure according to 3M ESPE instructions (occlusal reduction of approximately 1.5 mm, mesial and distal contact points cleared, no preparation on the buccal or lingual surfaces, feather edge gingival finishing line with no ledges or steps). A spiral shape bur was used in the preparation and a proximal reduction was performed to separate the teeth after which an occlusal reduction was performed using a candle flame bur in accordance with the circumference of the tooth so as to obtain an approximate reduction of 1.5mm [18]. In addition, the edges were rounded off to obtain a preparation margin in the shape of a feather edge around all of the preparation, while paying attention not to harm the neighboring teeth.

The teeth that received the esthetic crowns were in occlusal contact with the upper opposing teeth without raising the occlusion when tried in. After

the crowns were contoured, they were sandblasted using an air prophylaxis unit attached to the dental unit after raising the pressure in the dental unit to 42 psi, 3 bar, using aluminum oxide as a sandblasting agent with granule size of 60µ and sandblasting for about 20 seconds until the dull appearance of the stainless steel was attained.

The composite veneering was done on the buccal and the occlusal surfaces and a part of the lingual surface. The bonding system (Ceramic Repair, Intro Pack, Ivoclar Vivadent, Germany) was applied in accordance with the manufacturer's instructions, immediately after sandblasting [19].

After sandblasting, the crowns were rinsed with a stream of water and dried by a stream of air. Then, the Monobond® Plus was applied using a brush and was left for 60 seconds to evaporate and then air-dried. After that, an opaque layer was applied to the working surface to hide the metallic color and cured for 40 seconds. A thin layer of Heliobond was applied on the entire opaque surface; any excess was removed with an air stream, followed by curing for 20 seconds. Multiple layers of composite were applied using a soft material filling device; the least thickness was applied at each stage, then the composite was cured for 20 seconds. Finally, the veneer was finished and polished using soft composite finishing burs, rubber finishing burs and finishing discs. The thickness of the surfaces upon complete veneering with composite was ≤1mm, which was verified using a thickness meter.

The crowns were luted using an ionomer glass cement (Vivaglass®) and the excess of cement was removed using the probe and a dental floss. The occlusion was checked using carbon biting paper and the high points of contact were reduced, taking care not to cause the metal to become transparent from underneath the composite. In all cases, a slight occlusal height remained, not exceeding 1mm.

When the treatment was completed, the stainless steel crowns were clinically examined [17]:

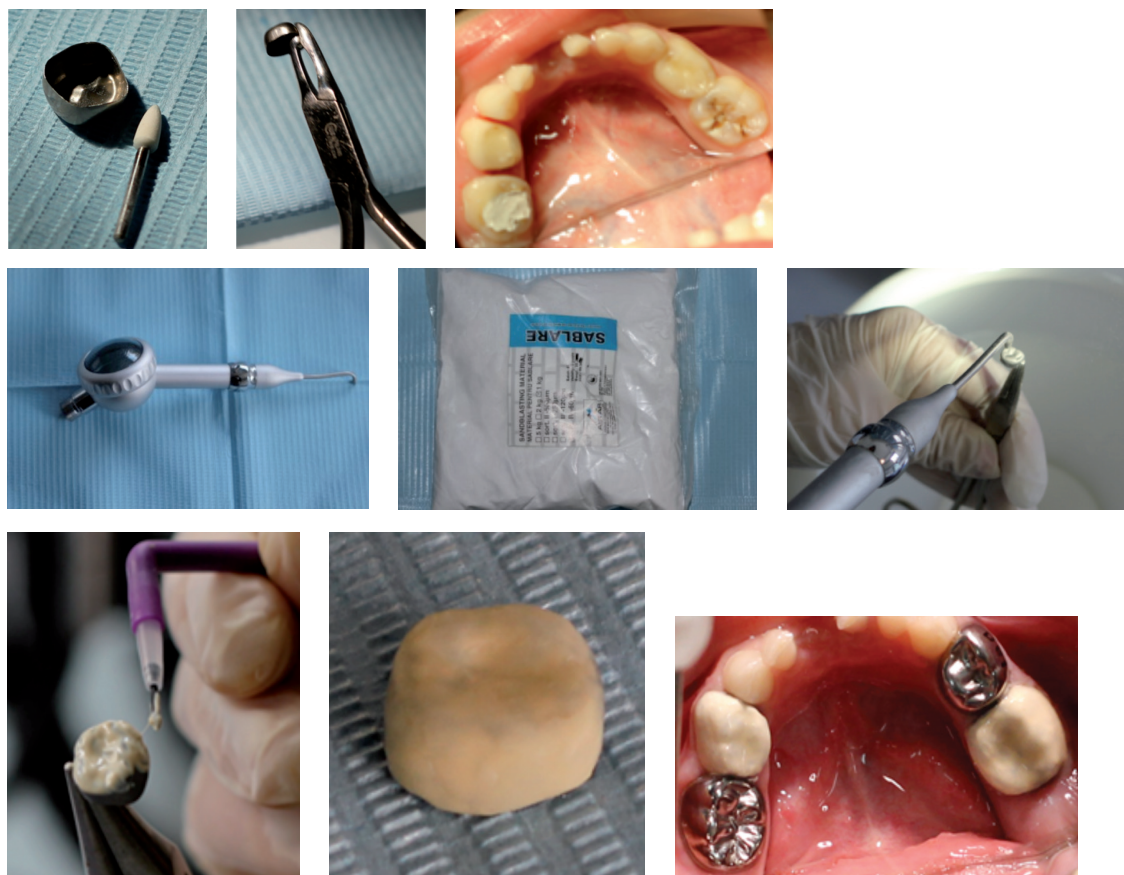


Fig. 1: The stages of deciduous molar preparation, adaptation and veneering of stainless steel crowns with nano-composite.

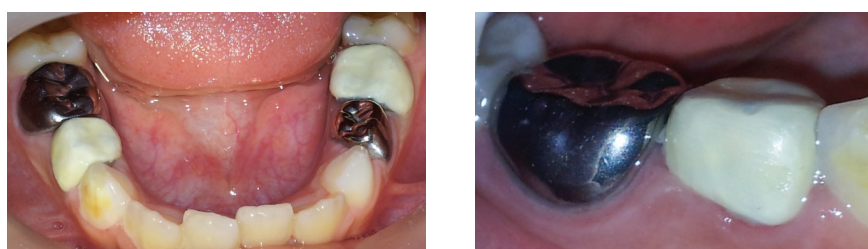

Fig. 2: The clinical marginal adaptation of both conventional and esthetic crowns.

Proximal contact areas between the first and second primary molars were recorded as either intact or open, by passing a dental floss.

Buccal and lingual marginal adaptation was recorded as either good with closed margins or poor when an open margin was detected upon probing.

Marginal extension was either below the gingival line (apical to the gingival margin) or above the gingival line (occlusal to gingival margin) or on the gingival margin (Fig. 2).

In addition, a bite-wing radiographic examination was done and an evaluation based on the blind testing method was completed by a pedodontic examiner. The evaluation included:

- The alveolar bone level: the level was considered normal when the distance between the crest of interdental bone and the cement-enamel junction was 2 mm or less. The bone was considered resorbed when this distance was greater than 2 mm [17].

- The quality of the crowns: it was considered inadequate when the margins of the crown appeared too short, below the cemento-enamel junction, away from the tooth surface by more than 1 mm or when any definitive flaws were noticed within the crown. The crown was regarded as good enough when all the margins were smooth and sufficiently contoured to cover all the dentin [17].

The crowns were re-examined after 1, 3 and 6 months, with every follow-

up involving clinical and radiographic examination as well as a recording of the level of oral hygiene and gingival index around the crowned teeth.

In order to investigate the parental satisfaction with the restoration using the composite veneered crowns, a five-point evaluation scheme was devised according to the Likert type scale [20]. Parental satisfaction was recorded after eight months based on the following aspects: 1- shape, 2- size, 3- color, 4- durability, 5- resurfacing of the metal. Each factor was assigned a value using the following scale:

- 1=highly dissatisfied,
- 2=dissatisfied,
- 3=indifferent,
- 4=satisfied,
- 5=highly satisfied.

Thus the result of the evaluation was out of 25 points.

**Statistical analysis**

The statistical analysis was done using the statistical software Stata (version 6.0). The Fisher's exact test was applied to study the relation between the treatment technique and the variables used to measure the outcome of the treatment, in addition to studying the factors related to gingivitis. The level of significance was set for a p-value of 0.05.

**Results**

The study sample consisted of 32 stainless steel crowns (16 conventional stainless steel crowns and 16 with esthetic veneers) placed in 10 children at the early school years. The average age of the children was 7 years with a standard deviation of 2.

The four mandibular molars were crowned interchangeably for six patients, whereas for the remaining four patients, two molars were crowned (60% of the patients had 4 crowned molars and 40% had 2 crowned molars). The statistical analysis didn't reveal any statistically significant differences between the two groups at the beginning of this study pertaining to all the crowning-related variables.

	GI scores			
	0	1	2	3
Conventional stainless steel crowns	9 (56.25%)	5 (31.25%)	1 (6.25%)	1 (6.25%)
Esthetic stainless steel crowns	10 (62.5%)	3 (18.75%)	3 (18.75%)	0%

Table 1: Distribution of the values of the GI for conventional and esthetic crowns at the first follow-up visit.

	GI scores		
	0	1	2
Conventional stainless steel crowns	12 (75%)	3(18.75%)	1 (6.25%)
Esthetic stainless steel crowns	11 (68.75%)	4(25%)	1 (6.25%)

Table 2: Distribution of the values of the GI for conventional and esthetic crowns at the second follow-up visit.

	GI scores	
	0	1
Conventional stainless steel crowns	13(81.25%)	3(18.75%)
Esthetic stainless steel crowns	14 (87.5%)	2(12.5%)

Table 3: Distribution of the values of the GI for conventional and esthetic crowns at the third follow-up visit.

**The gingival index**

The value of the gingival index was 0 for all the molars before they were prepared to receive the crowns, with the exception of a girl who had an index reading of 1 for two mandibular molars.

Table 1 illustrates the distribution of the GI values for both the conventional and the esthetic crowns at the first follow-up visit. The gingival index values were 0 and 1 in this observation for most cases and no statistically significant differences were noticed between the two groups (p=0.53).

Table 2 illustrates the distribution of the GI values for both the conventional and the esthetic crowns as obtained at the second follow-up visit. As in the prior observation, the index values were 0 and 1 for most cases and no statistically significant differences were noticed between the two groups (p=1).

At the third follow-up visit, the GI index values were 0 and 1; no statistically significant differences were noticed between the two groups (p=0.5) (table 3).

**Gingivitis-related factors**

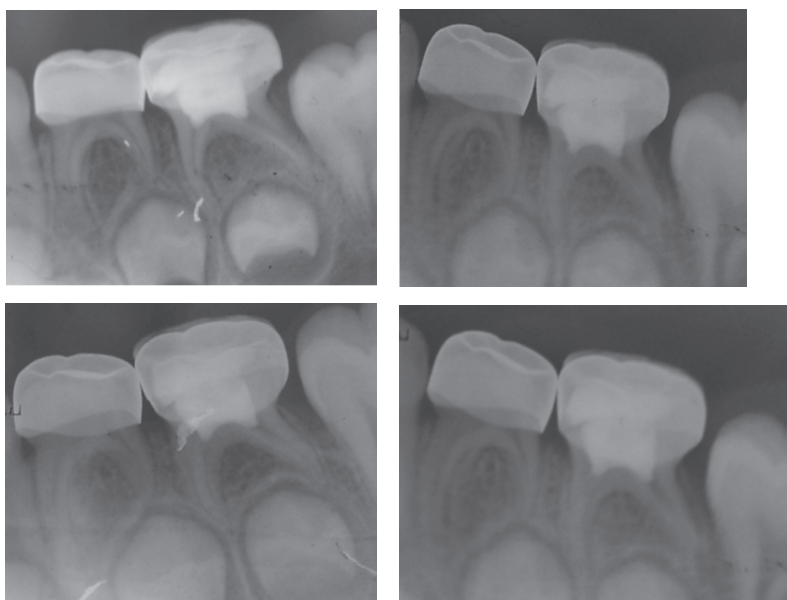


Fig. 3: Alveolar bone level at the three follow-up visits.

Aspect	Mean $\pm$ SD
Shape	4.5 $\pm$ 0.7
Size	4.1 $\pm$ 0.6
Color	4.4 $\pm$ 0.8
Durability	4.1 $\pm$ 0.7
Resurfacing of the metal	3.9 $\pm$ 1.2
Total	21 $\pm$ 3.2

Table 7: Mean degrees of parental satisfaction with the esthetic stainless steel crowns.

The impact of the following factors on gingivitis was studied: contact areas, marginal adaptation, marginal extension, radiographic marginal adaptation, type of crowns and oral hygiene.

In the first follow-up visit, no statistically significant relation was noted between all of the examined factors and gingivitis. The oral hygiene was poor for two girls with 6 crowned molars; GI values were between 2 and 3 for the second molars. However, the gingiva around their first two molars was not affected. An overall statistically significant relation was found

between the oral hygiene index and the GI ( $p=0.004$ ).

During the second follow-up visit, no statistically significant relation was noticed between all of the examined factors and gingivitis. The alveolar bone was normal for all crowns. No signs of gingivitis were present in cases of good and fair oral health except for one patient with good oral hygiene and another patient with fair oral hygiene. Signs of gingivitis were observed around all crowns in patients with poor oral hygiene ( $n=6$ ). A strong and statistically significant relation was found between the oral health index and GI ( $p<0.001$ ).

At the third follow-up visit, no statistically significant relation was noticed between all of the examined factors. A statistically significant relation was found between the radiographic marginal adaptation and the GI ( $p=0.034$ ). Likewise, a statistically significant relation was observed between oral hygiene and the GI ( $p<0.001$ ). An improvement in the gingival health was observed around the crowns with sufficient radiographic marginal adaptation (24 out of 26, i.e. 92.31%); these were exempt of any signs of gingivitis. Similarly, the good and fair oral hygiene cases were gingivitis free.

### Evaluation of the alveolar bone resorption

The resorption of the alveolar bone was evaluated after 1, 3 and 6 months based on apical radiographs. No resorption was noticed in the alveolar bone in any of the examined cases (Fig. 3)

- a) Immediately after fitting the crowns.
- b) After one month.
- c) After three months.
- d) After six months.

### Evaluation of parental satisfaction

The mean for overall parental satisfaction with the esthetic stainless steel crowns was 21. The degrees awarded by the parents for 9 out of 10 patients varied between 20 -25. The degree of satisfaction for one mother was 13 out of 25 as resurfacing of the metal received the lowest scores in this evaluation (table 7).

## Discussion

The ideal restoration should guarantee strength, durability and esthetic satisfaction. Many of the currently available restorations fail to achieve all the aforementioned goals [8]. Ram has stated that esthetic stainless steel crowns will play a greater role in pedodontics if certain improvements are made to reduce the bulkiness of the esthetic veneer thereby reducing its size and giving it a more natural appearance [8].

Composite bonding to stainless steel in the clinic was mentioned in medical literature. Several studies were conducted on the composite bonding of stainless steel as a chair-side technique [12, 13, 21, 22].

In the present study, the statistical analysis showed no significant differences between the conventional and the esthetic crowns at the beginning of the study, with respect to proximal contact areas, marginal extension and clinical and radiographic marginal adaptation.

The marginal adaptation of the esthetic stainless steel crowns was similar to that of the conventional

stainless steel crowns; in fact, the contouring and the crimping of the margins before bonding the esthetic veneer enhance the marginal adaptation of the crowns to the preparation margins. The ability to crimp the margins is considered a feature of this method, given that crimping and contouring the margins of the preformed esthetic crowns is considered a major obstacle as mentioned by many researchers [3, 4, 6, 8-10, 23, 24].

Esthetic crowns have shown excellent results in terms of durability as reported by many studies [6, 21, 23]. In our study, esthetic and conventional crowns remained intact at a rate of 100%. However, our observation period was relatively short.

Radiographic marginal adaptation had a statistically significant correlation with gingivitis only in the last follow-up visit performed six months after crowns placement. The number of crowns with insufficient radiographic marginal adaptation was six and gingivitis was present around three of them. Nevertheless, it can not be concluded that the radiographic marginal adaptation was the cause of the gingivitis around these crowns because oral hygiene was poor around three infected crowns, whereas the oral hygiene was fair or good around the three remaining gingivitis-free crowns.

A study by Sharaf and Farsi [17] found that crowns with insufficient clinical marginal adaptation had an impact on gingivitis, whereas the radiographic marginal adaptation did not have a similar impact.

In her comparative study between conventional and commercially available esthetic stainless steel crowns, Ram [8] found no differences in contact areas, radiographic adaptation of the crown and marginal extension, except for gingival health. She observed that gingival health around the conventional crowns was better than that around the esthetic crowns. This difference was attributed to the bulbosity of the veneer on the commercial esthetic crowns that formed a thicker gingival margin by 1.5mm compared to

the conventional crowns; this resulted in greater plaque accumulation in this region [8].

However, this was not found in our study where the thickness was 1mm or less in the margin region, not to mention that the composite was reduced and well finished after the margins were contoured outside the mouth. Thus, no noticeable difference was found between the two types of crowns whether in size or surface smoothness which explains the lack of differences in gingival health at all the stages of the study.

After six months, the overall incidence of gingivitis observed in the present study was 15.62% (12.5% around the esthetic crowns and 18.75% around the conventional crowns). These percentages highlighted a significant statistical correlation between poor oral health and insufficient radiographic marginal adaptation. This mild gingivitis (GI=1) is highly reversible and can be treated by instauring good oral hygiene habits [25].

The prevalence of gingivitis in the study of Leith et al. [23] was 17% for posterior esthetic crowns (Kinder Krowns, Nu Smile®) after 12 months. The study of Shah et al. [6] evaluated the degree of clinical success and oral hygiene around anterior esthetic stainless steel crowns (Kinder Krowns); they found that gingivitis was present around 39% of the teeth while a slight inflammation was observed around 24% of the teeth [6].

As for the alveolar bone resorption, no resorption was noticed at any stage of the present study. This agrees with the findings of Ram et al. [8], who reported dentoalveolar bone resorption around only one esthetic crown from a sample of 22 crowns, after a six months follow-up period. After four years, the same crowns showed no alveolar bone resorption [10]. Conversely, Bimstein et al. [25] found evidence of an abnormal resorption in the alveolar bone next to the conventional stainless steel crowns in 1.4% of the patients. The alveolar resorption increased in adjacent caries and areas



where food debris accumulated [25, 28].

In their study that evaluated stainless steel crowns clinically and radiographically, Sharaf and Farsi [17] showed that there was significant bone resorption when the crown was judged radiographically as non-satisfactory particularly for crowns observed over an average period of 17 months [17]. This was not noticed in our study, perhaps due to its short duration.

We used the 5-point Likert type scale to evaluate parental satisfaction with the esthetic stainless steel crowns. The Likert scale has been in use for decades; it was developed by Rensis Likert in 1932. This scale provides a very useful and relatively uncomplicated tool to obtain information regarding people's attitudes or opinions [20, 26].

In our study, parental satisfaction was high which agrees with several studies, such as the clinical study of Leith et al. [23], where parental satisfaction was found to be excellent with an average of 9.3 out of 10 on visual analogue scale (VAS).

In a study by Roberts et al. [27], parental satisfaction with the Whiter Biter II anterior crowns after 20.7 months was excellent (overall 8.9 out of 10). However, the high failure rate of the composite veneers was problematic. In a study by Shah et al. [6], parental satisfaction with anterior crowns by Kinder Crowns after 17.5 months was high, with an average satisfaction rate of 19-25. A study by Champangen et al. [28] revealed that overall parental acceptance of the Nu Smile® crowns was very high at 93%.

## Conclusion

The results obtained in the present study showed that veneering the posterior stainless steel crowns with nano-composite using the ceramic repair system (Ceramic Repair, Intro Pack, Ivoclar Vivadent) could be an effective procedure that improves esthetic appearance, preserves most of the dental structure, requires minimal

preparation and has a lower cost than the preformed esthetic crowns.

However, further clinical studies on larger samples and for longer duration are still needed to investigate the effect of these chairside veneered crowns on gingival tissue and alveolar bone health.

## References

- Salama FS, Myers DR. Stainless steel crown in clinical pedodontics: A review. *Saudi Dent J* 1992;4(2):70-74.
- Menek N, Başaran S, Karaman Y, Ceylan G, Tunc ES. Investigation of nickel iron release from stainless steel crowns by square wave voltammetry. *Int J Electrochem Sci* 2012;7(2):6465-6471.
- Croll TP and Helpin ML. Preformed resin-veneered stainless steel crowns for restoration of primary incisors. *Quintessence Int* 1996;27(5):309-313.
- Lee JK. Restoration of primary anterior teeth: review of the literature. *Pediatr Dent* 2002;24(5):506-510.
- Waggoner WF and Cohen H. Failure strength of four veneered primary stainless steel crowns. *Pediatr Dent* 1995;17(1):36-40.
- Shah PV, Lee JY, Wright JT. Clinical success and parental satisfaction with anterior veneered primary stainless steel crowns. *Pediatr Dent* 2004;26(5):391-395.
- Veerabhadran MM, Reddy V, Nayak UA, Rao AP, Sundarm MA. The effect of retentive groove, sandblasting and cement type on the retentive strength of stainless steel crowns in primary second molars: An in vitro comparative study. *J Ind Soc Pedodont Prev Dent* 2012;30(1):19-26.
- Fuks AB, Ram D, Eidelman E. Clinical performance of esthetic posterior crowns in primary molars: a pilot study. *Pediatr Dent* 1999;21(7):445-448.
- Kindelan SA, Day P, Nichol R, Willmot N, Fayle SA. UK national clinical guidelines in paediatric dentistry: stainless steel performed crowns for primary molars. *Int J Paediatr Dent* 2008;18(Suppl 1):20-28.
- Ram D, Fuks AB, Eidelman E. Long-term clinical performance of esthetic primary molar crowns. *Pediatr Dent* 2003;25(6):582-584.
- Waggoner WF. Restoring primary anterior teeth. *Pediatr Dent* 2002;24:511-516.
- Salama FS, el-Mallakh BF. An in vitro comparison of four surface preparation techniques for veneering a compomer to stainless steel. *Pediatr Dent* 1997;19(4):267-272.
- Khatri A, Nandlal B, Srilatha. Comparative evaluation of shear bond strength of conventional composite resin and nanocomposite resin to sandblasted primary anterior stainless steel crown. *J Ind Soc Pedodont Prevent Dent* 2007;25(2):82-85.
- Mitra SB, WU D, Holmes B. An application of nano technology in advanced dental material. *JADA* 2003;134(11):1382-1390.
- Chadha GM, Kakodkar P. Dental survey of institutionalized children with autistic disorder. *Int J Clin Pediatr Dent* 2012;5(1):29-32.
- Robinson PJ, Vitek RM. Periodontal examination. *Dent Clin North Am* 1980;24(5):597-611.
- Sharaf AA, Farsi NM. A clinical and radiographic evaluation of stainless steel crowns for primary molars. *J Dent* 2004;32(1):27-33.
- Cameron AC, Widmer RP. *Handbook of Pediatric Dentistry*. 4th ed., Mosby, USA, 2013.
- [www.ivoclarvivadent.com/en/competences/tout-ceramique/collage/monobond-plus](http://www.ivoclarvivadent.com/en/competences/tout-ceramique/collage/monobond-plus).
- Wuensch, Karl L. "What is a Likert Scale? and How Do You Pronounce 'Likert?'" . East Carolina University. (October 4, 2005). Retrieved April 30, 2009.
- Hattan MA, Pani SC, Alomai M. Composite bonding to stainless steel crowns using a new universal bonding and single-bottle systems. *Int J Dent* 2013;10:1-5.
- Yilmaz Y, Gurbuz T, Eyuboglu O, Belduz N. The repair of veneered posterior stainless steel crowns. *Pediatr Dent* 2008;30(5):429-435.
- Leith R and O'Connell AC. A clinical study evaluating success of 2 commercially available veneered primary molar stainless steel crowns. *Pediatr Dent* 2011;33:300-306.
- McDonald RE, Avery DR, Dean JA. *Dentistry for the child and adolescent*. 9th ed. St Louis: Mosby;2010.
- Bimstein E, Delaney JE, Sweeney EA. Radiographic assessment of the alveolar bone in children and adolescents. *Pediatr Dent* 1988;10(3):199-204.
- Janice R. *Essential elements of questionnaire design and development*: Blackwell Publishing Ltd. *J Clin Nursing* 2007;16(7):234-243.
- Roberts C, Lee JY, Wright JT. Clinical evaluation of and parental satisfaction with resin-faced stainless steel crowns. *Pediatr Dent* 2001;23(1):28-31.
- Champagne C, Waggoner W, Ditmyer M, Casamassimo PS, MacLean J. Parental satisfaction with veneered stainless steel crowns for primary anterior teeth. *Pediatr Dent* 2007;29(6):465-469.