

1-22-2020

## Virtual prosthetic try in using Photoshop: Method of transferring veneers from the cast to the patient's mouth digitally

Ahmed ABYAD

Ghida LAWAND

Follow this and additional works at: <https://digitalcommons.aaru.edu.jo/iajd>

---

### Recommended Citation

ABYAD, Ahmed and LAWAND, Ghida (2020) "Virtual prosthetic try in using Photoshop: Method of transferring veneers from the cast to the patient's mouth digitally," *International Arab Journal of Dentistry*. Vol. 9: Iss. 2, Article 4.

Available at: <https://digitalcommons.aaru.edu.jo/iajd/vol9/iss2/4>

This Original Article is brought to you for free and open access by Arab Journals Platform. It has been accepted for inclusion in International Arab Journal of Dentistry by an authorized editor. The journal is hosted on [Digital Commons](#), an Elsevier platform. For more information, please contact [rakan@aarj.edu.jo](mailto:rakan@aarj.edu.jo), [marah@aarj.edu.jo](mailto:marah@aarj.edu.jo), [u.murad@aarj.edu.jo](mailto:u.murad@aarj.edu.jo).

## VIRTUAL PROSTHETIC TRY IN USING PHOTOSHOP: METHOD OF TRANSFERRING VENEERS FROM THE CAST TO THE PATIENT'S MOUTH DIGITALLY

Ahmed Abyad\* | Ghida Lawand\*\*

### Abstract

Utilizing software to transfer photographic templates of teeth to the patient's mouth before the treatment is a common practice in esthetically demanding cases; this is termed as a digital smile design. However, transferring the actual restorations from the finalized cast to the patient's mouth digitally using software before the try-in session is not reported in the literature. The steps and benefits of performing a virtual try-in (VTI) before the fitting try-in session are demonstrated in this article.

**Keywords:** Esthetics – digital smile design – virtual try-in – restorations – fixed prosthesis.

IAJD 2018;9(2):65-70.

## ESSAIS VIRTUELS DES PROTHÈSES EN UTILISANT LE PHOTOSHOPE : MÉTHODE DE TRANSFERT DES VENEERS DE L'EMPREINTE À LA BOUCHE DU PATIENT NUMÉRIQUEMENT

### Résumé

L'utilisation d'un logiciel pour transférer des modèles photographiques de dents à la bouche du patient avant le traitement est une pratique courante dans les cas exigeants sur le plan esthétique. Cela s'appelle un « design » de sourire numérique. Cependant, le transfert des restaurations réelles à la bouche du patient en utilisant le logiciel avant la séance d'essai en bouche n'est pas indiqué dans la littérature. Les étapes et les avantages de l'exécution d'un essai virtuel (VTI) avant la séance d'essayage sont illustrés dans cet article.

**Mots-clés :** Esthétique - conception numérique du sourire - essai virtuel - restaurations – prothèses fixées.

IAJD 2018;9(2):65-70.

---

\* BDS, MSc,  
Senior Lecturer of Dental Biomaterials,  
Dpt of Oral Rehabilitation Sciences,  
Beirut Arab University, Beirut, Lebanon  
a.abiyad@bau.edu.lb

\*\* Dpt of Oral Rehabilitation Sciences  
Beirut Arab University, Beirut, Lebanon

## Introduction

Advancements in fabrication technology and material sciences in ceramics allowed an increase in the use of ceramic restorations in esthetically demanding cases. The fit and esthetics of restorations fabricated utilizing these advanced processes are superior to those fabricated using conventional techniques [1, 2].

Processes such as scanning and computer-aided milling helped decrease patient's chair time. However, despite the high level of technology available to facilitate all stages of the treatment, a try-in session is still necessary prior to cementation [3]. The primary objective of try-in sessions is to assess two main criteria in any case requiring esthetic rehabilitation: 1) The fit of the restorations, and 2) The assessment of their relationship with facial landmarks [4]. Assessing the fit always requires a thorough try-in procedure to assure proper adaptation of the margins of the restoration [5]. However, concerning the relationship with facial landmarks, it is arguable that a real try-in session is not required and the initial assessment of the esthetics of restorations could be attempted in a virtual try-in (VTI) through software manipulation without the presence of the patient on the dental chair.

A real try-in session requires a lot of fiddling with the restorations especially with thin veneers that don't provide enough mechanical retention [6]. Keeping the veneers in place for the patient to visualize and provide feedback is usually problematic. Even with try-in paste, veneers keep falling off when the patient smiles and moves his lips.

The major limitation of an initial try-in session however is the loss of time. If there are adjustments to be made regarding the esthetics, the restorations must be sent back to the lab and a new try-in session is rescheduled for reassessment.

The goal of the try-in session should be assessing the fit and marginal adaptation of the restorations without was-

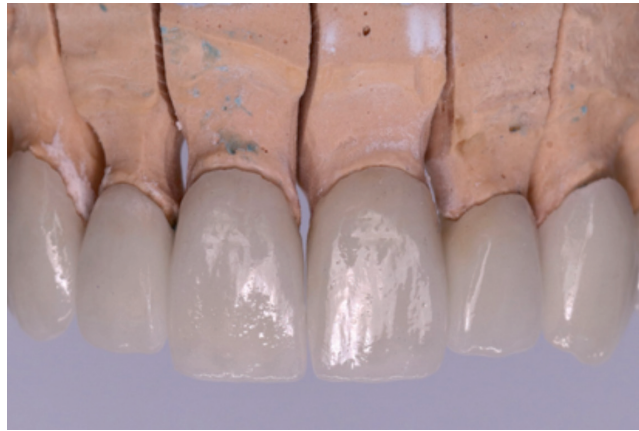

Fig. 1 : Photograph of the cast against a plain background (CL).

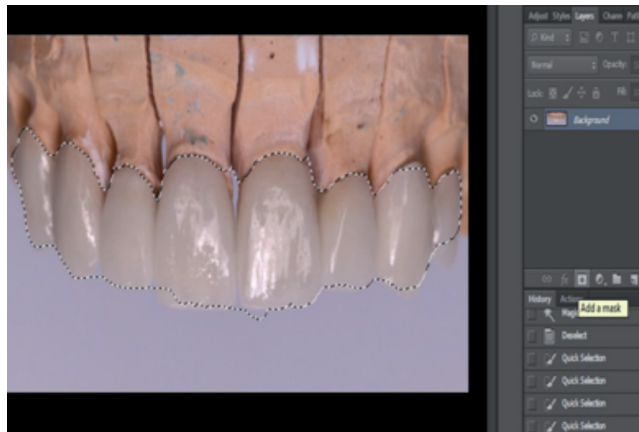


Fig. 2: Photoshop using quick selection tool in Adobe Photoshop to mark the restoration margins.

ting time assessing the shape of the restorations and their relationship with the facial landmarks. Several try-in sessions due to an unsatisfied patient is a waste of time and resources. Before the actual try-in, an initial VTI should be performed to show the patient what the real restorations would look like. This allows the lab technician to perform primary adjustments related to the length and proportions of teeth before the fitting try-in session. VTI is performed using Photoshop (Adobe Systems Inc., CA, USA) by manipulating different layers using only 3 photographs, one photograph of the restorations on the cast, and two full face front photographs of the patient one

in retracted position and another in the smiling position. This is different than Photoshop Smile Design (PSD) proposed by McLaren et al. who utilize ready-made templates with the objective of treatment planning similar to the approach of Coachman et al. in smile design [7-10]. VTI utilizes a photograph of the actual finalized restorations.

## Materials and Methods

Materials utilized in this case could be divided into two parts, the hardware and the software. The hardware consisted of a DSLR camera model 80D with a 100mm Canon Macro lens and a

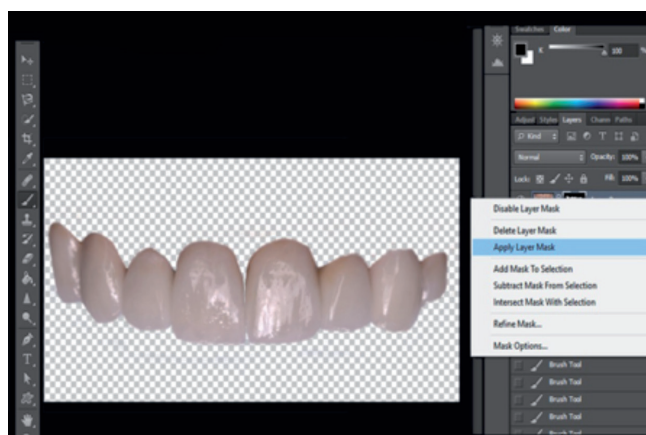
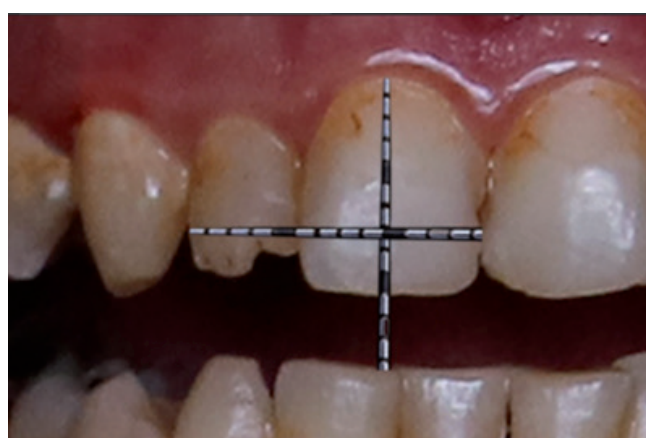
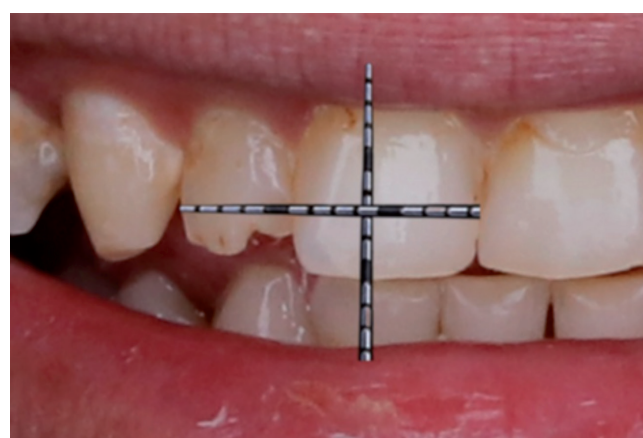

Fig. 3 : (Photoshop) using the masking tool to erase the background and create a transparent layer containing restorations (TCL).



a



b

Fig. 4: a) (Photoshop) Calibration of the teeth with real size measurements using virtual probe; b) (Photoshop) Applying the calibration on the non-retracted image to allow placement of the TCL.

twin flash (Canon, Tokyo, Japan). The software utilized was Photoshop CS6.

The parameters to be assessed after finalizing the treatment were the accuracy of the VTI and its resemblance to reality in addition to its effectiveness in enhancing communication between the patient, clinician and technician.

Starting with preliminary photography, the lab technician was asked to take a photograph of the restorations placed on the cast while positioning the lens of the camera on a flat plane perpendicular to the cast against a plain background. This will be called the cast layer (CL) (Fig. 1)

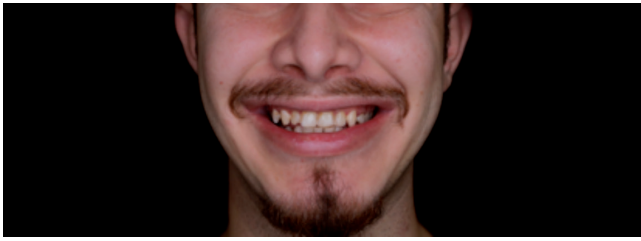Using Adobe Photoshop, the restorations were selected from the CL using the quick select tool (Fig. 2).

The background was then erased using the masking tool (Fig. 3). A layer containing the restorations without any background was obtained; this layer was called the transparent cast layer (TCL) since it contained the restorations against a transparent background.

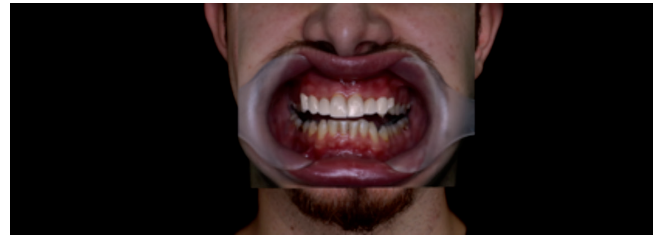The preoperative photographs with retractors were then calibrated using the real measurements of the teeth with a virtual probe or ruler on the software. This was done by placing the tip of the ruler on clear reproducible reference points. In this case the

mesial line angle of the central incisor tooth # 11 and the distal surface of the lateral incisor tooth # 12 were chosen as a reference. The vertical reference points are the zenith of the gingival margin and the midpoint of the incisal edge of tooth # 11. Since the measurements of the teeth intraorally are now known the size of the probe in Photoshop could be increased and decreased to fit the real size, the virtual probe is now calibrated and should not be resized during the following steps (Fig. 4).

The smiling image (layer) (Fig. 5a) was then overlayed with the retracted image (layer) (Fig. 5b) in order to position the TCL on top of the teeth. This

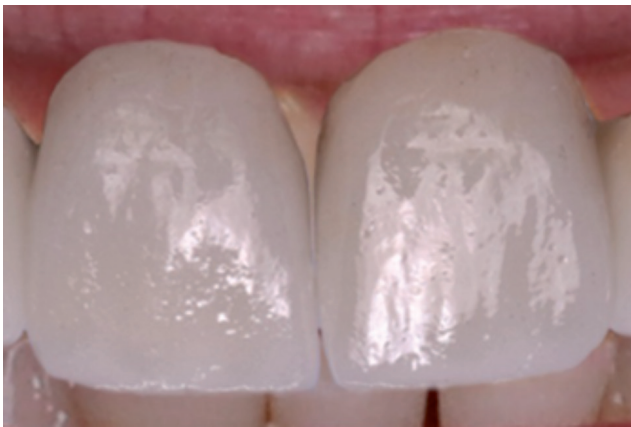

a

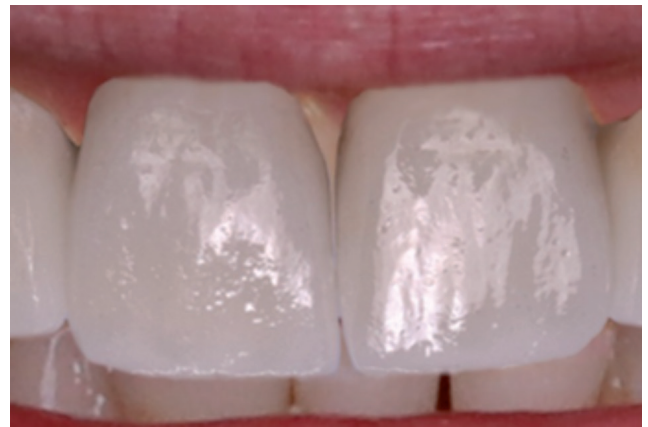

b

Fig. 5: (a) Before image; (b) (Photoshop) Retracted layer overlaying the smiling image utilizing the calibration step in figure 4 with the TCL layer in place.

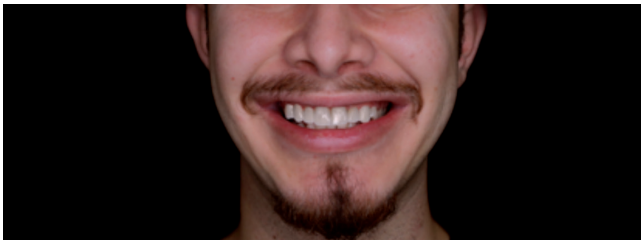

a



b

Fig. 6: (a) (Photoshop) TCL obtained in figure 3 is placed aligning the restoration margins with the gingival margins; (b) (Photoshop manipulated). Extruding edges are erased to provide a natural life resembling look.



a



b

Fig. 7: a) (Photoshop) Retracted layer was removed leaving the TCL (Fig. 3) on top of the original image. This was termed as the virtual try-in layer (VTI); b) Real results of the restorations after cementation. Notice the real resemblance between the VTI and the real results.



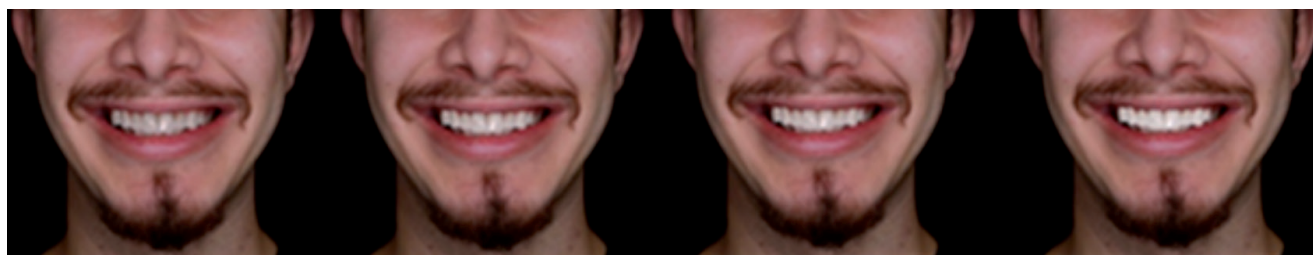


Fig. 8: (Photoshop) VTI showing increasing the value in restorations using the brightness tool in Adobe Photoshop allowing better understanding of the patient's expectations. Note how brighter shades give the illusion of more prominent and larger teeth.

was performed by aligning the margins of the restorations with the gingival margin of the teeth.

The impinging margins were then erased after positioning the TCL using the eraser tool (Fig. 6).

The retracted layer that was placed on top of the smiling layer was then hidden from the layers tab to obtain the smiling layer alone. Because the calibration was done before, the TCL should be well aligned with the patient's smiling photograph. After this the VTI was obtained (Fig. 7a), and was then compared to the real results after cementation (Fig. 7b).

The VTI images were then presented to the patient asking for any adjustments in the shape and position of the teeth. The patient was asked about the embrasures and interincisal angles in addition to the color. The comments were sent back to the lab technician with the VTI photographs for adjustments. After this the VTI was completed and the fitting was checked with a real try-in session. The TCL was bleached as well using the brightness tool in Photoshop and the images were duplicated and stacked next to each other for the patient to view varying degrees of value in the restorations (Fig. 8).

## Results

### Resemblance of the VTI to real results

The VTI and the real cemented restoration images showed great degree

of resemblance. The restorations showed no difference in angulation or tipping in the VTI. The occlusal plane also showed no difference between the two images and no canting was detected (Fig. 7).

### Establishing enhanced communication

The VTI concept established good communication between the patient and the clinician on one hand, and the clinician and the dental technician on the other hand. Discussing the case prior to the try in session was beneficial to all parties and was well appreciated by the patient.

When using the VTI, only one real try-in session was necessary prior to cementation and changes were made to the restorations except for bite adjustments.

## Discussion

The VTI concept is a highly accurate representation of the finalized restorations intraorally. In this case, comparing the VTI image (Fig. 7a) to the non-manipulated image after cementation (Fig. 7b) shows that the canine was long and impinging on the lower lip on the VTI for example. This was reflected in the final results and the canine also appeared to be impinging on the upper border of the lower lips confirming the precession of the VTI.

The process was successful due to two main factors: 1) During the photography, the perpendicular alignment

of the DSLR to the occlusal plane of the CL prevented tipping or canting of the TCL and replicated the real results; and 2) the calibration step performed in the software prevented wrong sizing of the TCL on top of the original images assuring correct sizing of the restorations in the VTI.

Stacking the finalized restorations with brighter shades was also beneficial (Fig. 8). It could be noticed that in this case as the brightness increased the restorations looked larger and more protrusive. This allows the patient to understand the impact of his decision regarding the shade of the restorations especially in patients with high esthetic demands asking for a "Hollywood bright smile". If that is the case the restorations can be slightly stained prior to glazing and before the real try-in session.

The VTI concept allows practitioners to transfer the restorations on the cast to the patient's mouth digitally. This concept is highly advantageous because it saves time, effort in creating temporaries for each try-in, and is an excellent lab communication tool.

A limitation of this technique however would be that many practitioners lack of photo-editing skills. With basic knowledge of Photoshop tools, which could be acquired through tutorials or mini-courses, dentists will be able to perform the VTI quickly and implement it in their daily practice.

Regarding the level of evidence presented in this study it should be noted

that the effectiveness of the technique in mention is still subjective and an original study should be performed to objectify the results in the future.

## Conclusion

A try-in session for assessing the fit of the restorations in addition to their shape and color is always necessary. VTI however allows the patient to express his comments before the fitting try-in session saving one additional appointment in case there is a need for adjustments. This saves time and resources and provides the patient with more satisfaction.

Patients appreciate the utilization of digital dentistry to enhance the quality of the treatment. With increasing number of clinicians utilizing Adobe Photoshop as a tool to arrange photographic records and to perform smile design, this technique may become more accessible in the future to a wider range of general practitioners.

### Acknowledgment

The authors would like to thank Graphic Designer Mrs. Aya Joune for her helpful insights on the Photoshop software. Dr Abyad is a receiving a CNRS-L grant from the National Council of Scientific Research.

## References

1. Wiedhahn K, Kerschbaum T, Fasbinder DF. Clinical long-term results with 617 Cerec veneers: a nine-year report. *Int J Comput Dent* 2005;8:233–246.
2. Wittneben JG, Wright RF, Weber HP, Gallucci GO. A systematic review of the clinical performance of CAD/CAM single-tooth restorations. *Int J Prosthodont* 2009;22:446–471.
3. McLean, John W. Evolution of dental ceramics in the twentieth century. *J Prosthet Dent* 2001;85:61-66.
4. Ahmad I. Anterior dental aesthetics: Facial perspective. *Br Dent J* 2005;199:1521.
5. Wassell R, Barker D, Steele J. Crowns and other extra-coronal restorations: try-in and cementation of crowns. *Br Dent J* 2002;193:17-28.
6. Oberoi G, Chaudhry S, Yadav S, Talwar S, Verma M. Correction of gummy smile using digital smile designing in conjugation with crown lengthening by soft-tissue diode laser. *J Dent Lasers*. 2017;11:14.
7. Pini N, Aguiar FH, Lima D, Lovadino J, Terada R, Pascotto R. Advances in dental veneers: materials, applications, and techniques. *Clin Cosmet Investig Dent* 2012;4:9.
8. McLaren E, Garber D, Figueira J. The Photoshop Smile Design technique (part 1): digital dental photography. *Compend Contin Educ Dent* 2013;34:772-4.
9. Coachman C, Van Dooren E, Gürel G, Landsberg CJ, Calamita MA, Bichacho N. Smile design: From digital treatment planning to clinical reality. *Interdisciplinary Treatment planning* 2012;2:119-74.
10. Erdemir U, Yildiz E, Yucel T. Esthetic Parameters/Smile Design. In *Esthetic and Functional Management of Diastema* 2016 (pp. 53-64). Springer, Cham.