

2021

## Color Doppler Ultrasonographic Evaluation of Varicocele: Best Position and Site for Improving Maximal Vein Diameter Measurement

Jamal Omer Bahabara

*College of Medicine and Health Sciences, Hadhramout University*

Wadea Saeed Bin Ghouth

*College of Medicine and Health Sciences, Hadhramout University.*

Follow this and additional works at: [https://digitalcommons.aaru.edu.jo/huj\\_nas](https://digitalcommons.aaru.edu.jo/huj_nas)



Part of the [Medicine and Health Sciences Commons](#)

---

### Recommended Citation

Bahabara, Jamal Omer and Bin Ghouth, Wadea Saeed (2021) "Color Doppler Ultrasonographic Evaluation of Varicocele: Best Position and Site for Improving Maximal Vein Diameter Measurement," *Hadhramout University Journal of Natural & Applied Sciences*: Vol. 15 : Iss. 1 , Article 2.

Available at: [https://digitalcommons.aaru.edu.jo/huj\\_nas/vol15/iss1/2](https://digitalcommons.aaru.edu.jo/huj_nas/vol15/iss1/2)

This Article is brought to you for free and open access by Arab Journals Platform. It has been accepted for inclusion in Hadhramout University Journal of Natural & Applied Sciences by an authorized editor. The journal is hosted on [Digital Commons](#), an Elsevier platform. For more information, please contact [rakan@aar.edu.jo](mailto:rakan@aar.edu.jo), [marah@aar.edu.jo](mailto:marah@aar.edu.jo), [u.murad@aar.edu.jo](mailto:u.murad@aar.edu.jo).

## Color Doppler Ultrasonographic Evaluation of Varicocele: Best Position and Site for Improving Maximal Vein Diameter Measurement

Jamal Omer Bahabara\*

Wadea Saeed Bin Ghouth\*

### Abstract

The purpose of this study is to identify the best position and site for color Doppler ultrasonography evaluation of testicular vein to obtain optimal diameter measurement. Over the first six months of year 2017, eighty nine patients aged 22-48 years who proved to have varicocele were included in the study. Color Doppler sonography was performed using a 7.5 MHz linear-array transducer, and the diameter of largest testicular vein at three different sites was measured in both supine and standing positions with and without Valsalva maneuver. Patients' varicoceles were graded according to the supine-rest maximum vein diameter into: Grade 0: less than 2 mm, Grade I: 2-3 mm, Grade II: more than 3 mm, and the changes in caliber in those grades were compared. Posterlateral scrotal edge was the best site for maximal vein diameter measurement followed by epididymal head, and the maximum vein diameter is obtained at the standing position with the use of Valsalva maneuver. So, the best position and site was the upright position with Valsalva maneuver at the posterolateral scrotal edge followed by epididymal head level.

**Key words:** Color Doppler ultrasonography, Valsalva maneuver, Varicocele.

### Introduction:

Varicocele is a collection of abnormally dilated, tortuous spermatic veins [3,8]. They occur with an incidence of 15% in adolescent males and 10–15% in adult men [21]. The clinical relevance of varicocele is based on its symptoms being related to scrotal venous stasis and the potential association with male infertility.

Varicocele is recognized as the most common surgically correctable cause of male infertility (30), but the exact mechanism of varicocele-induced impairment of spermatogenesis remains a matter of debate [23]. The exact association between reduced male fertility and varicocele is unknown, but studies showed that semen improvement is usually observed after surgical correction [6,7,24, 27,34].

Varicoceles are often classified as clinical or subclinical. Clinical varicoceles are diagnosed by physical examination and are graded based on physical findings according to Dubin and Amelar (1970) into three grades [1], while subclinical varicoceles are those that are not palpable on physical examination and require imaging for diagnosis by the presence of US findings of venous dilation and/or reflux flow in the pampiniform plexus [20,29]. So, physical examination is an essential diagnostic tool, but alone is not a highly reliable tool, and is affected by low sensitivity and specificity, especially in cases of low grade or subclinical varicocele [4,13,17], although current evidence indicates

that treatment of subclinical varicocele is not warranted, as it does not seem to improve fertility [32].

Color Doppler ultrasonography (CDUS) is the most sensitive, non-invasive and world-wide diagnostic method for varicocele, and has a sensitivity of approximately 95% in the diagnosis of varicocele [19]. In addition, CDUS may be a part of early postoperative follow-up as well as preoperative examination for predicting varicolectomy outcome, especially for macroscopic surgeries [2,9,11,12].

In the other hand, color Doppler is the method of choice for detecting spermatic vein reflux and for classifying the grade of varicocele, regarding World Health Organization (WHO) 2000 guidelines on male infertility which state that a varicocele diagnosis should be confirmed by color Doppler [15].

Although the maximal vein diameter and the presence, velocity, and duration of reflux are the currently used criteria for diagnosis of varicocele, but the quantitative measures of scrotal vein diameters and scrotal reflux obtained in healthy subjects showed a wide overlap with the values reported in the literature as a CDUS diagnostic values. Cina et al. [10] reported that a scrotal diameter of up to 3.7 mm and a reflux lasting up to 3 seconds with a velocity of 0.1 m/s can be observed in healthy subjects and should not be interpreted as a certain sign of scrotal varicocele.

So, there are no generally accepted criteria for the diagnosis of varicocele by this method, but studies were continued to improve the accuracy of diagnosis depending upon those parameters.

\* Department of surgery (radiology)- College of medicine and health sciences- Hadramout University - Mukalla-Yemen. Received on 20/11/2017 and Accepted for Publication on 17/4/2018

In this field, our study was a trial aimed to determine the best position and best site for color Doppler ultrasonography evaluation of the testicular veins which can obtains the best and optimal venous diameter measurement, that allows best differentiation of clinical varicocele from normal subjects.

#### Patients and methods:

The study was performed during a period of six months from first of January- end of June 2017. Eighty nine male patients from Hadramout, Almahra and Shabwa governorates, aged between 22-48 years were included in the study, who referred to Bahabara radiology center in Mukalla city with clinical diagnosis of varicocele by urologist physical examination, or suspicious of subclinical varicocele, and proved to have signs of varicocele according to accepted sonographic and color Doppler parameters, including maximal vein diameter during rest and Valsalva's maneuver, and the presence of reflux and flow reverse within pampiniform and spermatic veins.

Color Doppler sonographic (CDS) examinations were performed using a 7.5 MHz linear-array transducer (SonoAce 8000 SE; Medison, South Korea and SIUI; China) by one expert radiologist, with the subjects in supine position while the abdomen and chest elevated to about 15°, followed by the same examination with the patients in a standing position.

Examinations were centered at the level of the inguinal canal and just over the superolateral edge of the testis and posterolateral edge. The maximum venous diameters in the testicular

veins were measured both during rest and Valsalva's maneuver (maximal abdominal strain against a closed epiglottis just after a deep inspiration) in the supine position, followed by same measurements in standing position. Veins that were larger than 2 mm in diameter at rest were considered to be a varicocele.

Patients' varicoceles were graded according to the maximum vein diameter found during supine examination at rest into three grades: Grade 0: less than 2 mm but had reflux during Valsalva Maneuver, Grade I: 2-3 mm, and Grade II: more than 3 mm. We compared the changes in the caliper of veins on these grades of each varicocele unit in the supine position during rest and during the Valsalva maneuver, followed by the same comparisons in the standing position. Also, at site-wise part of the study (determine the best position to define the clinical grades of varicocele ultrasonographically), the diameter of the testicular vein was measured at the level of three sites including: at posterolateral scrotal aspect (corresponding to the body of epididymis)), at the head of the epididymis (upper testicular pole), and at lower pole of testis (or tail of epididymis).

The data were analyzed by using the Statistical Package for the Social Sciences (SPSS) version 20.

#### Results:

Out of the 89 patients included in this study, 9 were in grade 0 (10.1%), 71 were in grade 1 (79.8%), and 9 were in grade II (10.1%) according to the maximum vein diameter at rest (Fig. 1).

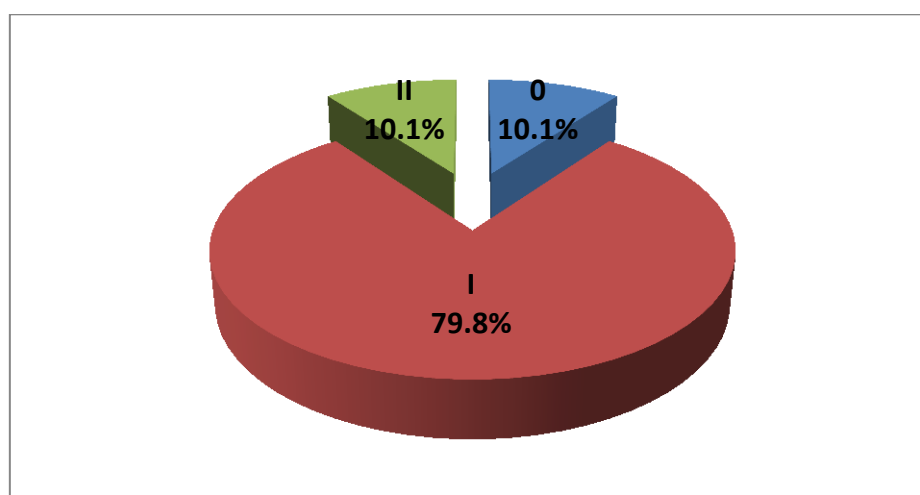


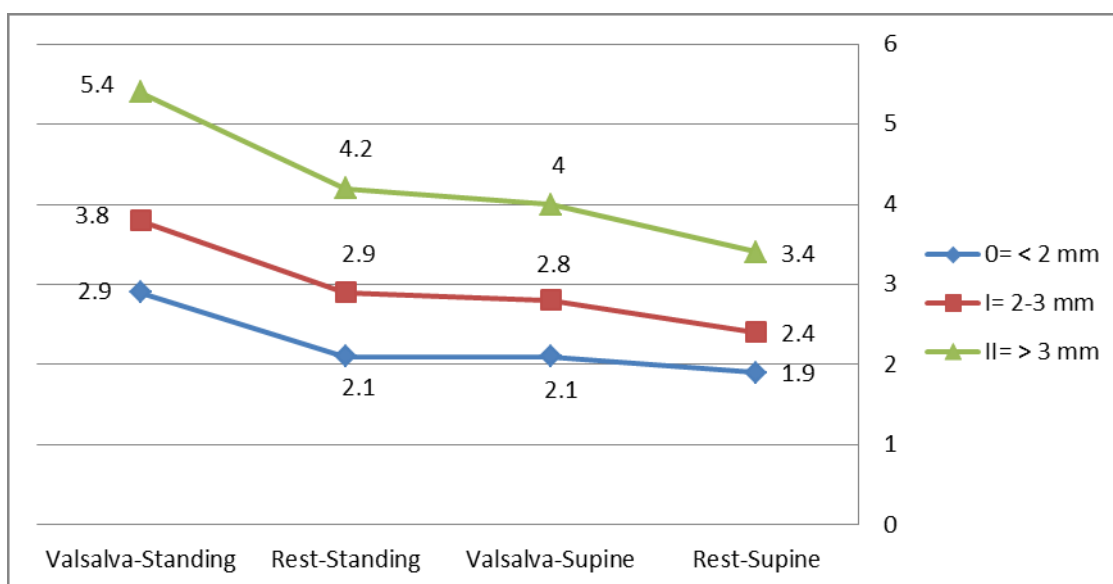
Fig. 1: Distribution of the 89 patients according to their varicocele grade

By the use of scrotal color Doppler sonography (CDS) in the supine position at rest, the mean of maximal vein diameter (mMVD) of varicocele was 1.9 mm (range: 1.8-2mm), 2.4 mm (2.1-2.9mm), and 3.4 mm (3.1-4.1mm), for grades 0, I, and II respectively. In the supine position during the Valsalva maneuver, the mMVD was 2.1 mm (range: 1.8-2.3mm), 2.8 mm (2.3-3.6mm), and 4 mm (3.4-4.7mm) for grades 0, I, and II respectively.

In the standing position at rest, the mMVD was 2.1 mm (range: 1.8-2.8mm), 2.9 mm (2.2-4.3mm), and 4.2 mm (3-5.6mm) for grades 0, I, and II respectively. In the standing position during a Valsalva maneuver, the mMVD was 2.9 mm (range: 2.2-3.8mm), 3.8 mm (2.6-5.3mm), and 5.4 mm (4.3-6.7mm) for grades 0, I, and II respectively (table 1, Fig. 2).

**Table 1: The mMVD in supine and standing positions at rest and during Valsalva Maneuver**

Grade	Rest-Supine	Valsalva-Supine	Rest-Standing	Valsalva-Standing
0= < 2 mm	1.9	2.1	2.1	2.9
I= 2-3 mm	2.4	2.8	2.9	3.8
II= > 3 mm	3.4	4	4.2	5.4



**Fig. 2: Shows the degree of increasing mean venous diameter during Valsalva-standing position at different grades**

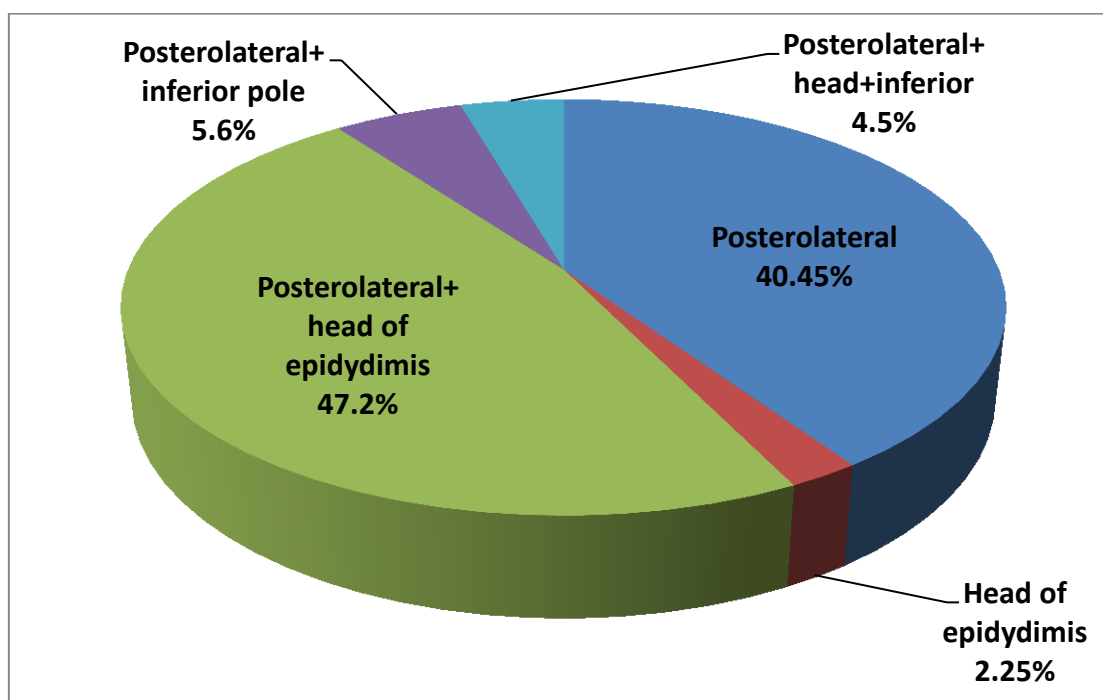
In general, the best site for determination of the maximal venous diameter in all grades was at the posterolateral scrotal aspect, which achieved in 87 patients (97.75%); alone in 36 patients (40.45%), and combined with other sites- mainly head of epididymis- in the rest: posterolateral with head of epididymis in 42 cases (47.2%), posterolateral with head of epididymis with

inferior pole in 4 cases (4.5%), posterolateral with inferior pole in 5 cases (5.6%).

The head of epididymis was seen in 48 patients (53.93%) combined with other sites; but alone in two cases only (2.25%), while the lower pole of testis was the least position (9 cases, 10.1%) in which the measurement was also best at other sites, and not confined to it (table 2, Fig. 3).

**Table 2: Frequency of different sites for best vein diameter measurement**

Site	Number	Percent
Posterolateral	36	40.45%
Head of epidydimis	2	2.25%
Posterolateral+head of epidydimis	42	47.20%
Posterolateral+inferior pole	5	5.60%
Posterolateral+head+inferior	4	4.50%

**Fig. 3: Distribution of different sites for best measurement of maximal venous diameter in varicocele patients****Discussion:**

There is no standardized criteria for the ultrasonographic diagnosis of varicocele exist [22,28,31,33], thus, the reliability of this technique in detecting varicoceles was controversial, but its use has been widely evaluated in many studies in recent years [21].

The blood vessels of the pampiniform plexus are usually no more than 1.5 mm in diameter [25], and A widely accepted ultrasound criterion for diagnosis of varicocele is the existence of veins larger than 2 mm in diameter [18].

Gonda et al. [14] reported 95% sensitivity with a 2-mm cutoff for vein diameters. Pilatz et al. [26] reported a cut-off point of 2.95 mm.

Caskurlu et al. [5] reported that they did not find an exact relation between the highest venous diameter in the men who have and those who do not have subclinical varicocele with CDU.

Recently, Lee et al. [20] reviewed previous studies and insisted that multiple veins >3.0 to 3.5 mm with concomitant reversal of flow after Valsalva maneuver is the most widely used criteria for diagnosing a varicocele on CDU.

Our study findings showed that venous diameter measurement is varied according to the position of the patient during ultrasonic examination, and increased with Valsalva maneuver in both supine and standing positions, reached its maximum in the upright position with Valsalva maneuver. In

this position, even the vein diameter in grade 0 which is less than 2 mm at rest and could be considered normal in classical cut off values, showed considered increase with a mean of 2.9 mm, and a range reaching up to 3.8 mm.

This suggests that the detection of varicocele is more precise in the standing position, and the Valsalva maneuver has a greater role in dilation of the pampiniform plexus in the standing position than in the supine position. This finding was also studied and confirmed by Kim et al. [18] who concluded that the standing position and Valsalva maneuver during CDU could improve diagnostic ability for varicocele.

The mMVD values in supine position during Valsalva maneuver and mMVD values in the rest-standing position in this study were somewhat similar to each other. This finding supported the negligible effect of supine position for measurement of maximal venous diameter during sonographic evaluation of varicocele even with the use of Valsalva maneuver, except for those patients who can't tolerate standing position. In the other hand, the Valsalva-standing position gave the optimal dilatation of the veins in comparison with other conditions, that allow maximal venous diameter measurement and can be used for establishing an accepted cut off value for differentiating subclinical varicocele from normal subjects, as achieved by Karami et al. [16].

Our findings also showed that the best site for optimal measurement of maximal vein diameter was the posterolateral scrotal aspect (in 97.75%), followed by at the level of epididymal head. This is not matched with the results of Karami et al. [16] who concluded that the best site for venous diameter measurement was at the level of epididymal head. However, from the results of our study and Karami et al (16) study, we can say that both sites should be considered during sonographic evaluation of varicocele, searching for the widest veins to give an optimal vein diameter.

**Conclusion:**

As a component of sonographic diagnosis of varicocele, the widest venous diameter measurement should be achieved both for diagnosis and also for definition of different clinical grades of varicocele ultrasonographically. Our study showed that the standing position doing Valsalva maneuver could be the most accurate condition for scrotal CDUS examination, and the venous diameter at the level of posterolateral scrotal aspect followed by epididymal head is the best parameter that can be used to distinguish normal subjects from patients with clinical varicocele. However, further studies with larger sample size should be carried out in order to determine more accurate and agreed cut-off points.

**References:**

- 1- Alsaikhan B, Alrabeeh Kh, Delouya G, Armand A. (2016). Epidemiology of varicocele. *Asian J Androl.* 18 (2): 179-181.
- 2- Alshehri FM, Akbar MH, Altwairgi AK, Althagufi OJ. (2015). Preoperative duplex ultrasound parameters predicting male fertility after successful varicocelectomy. *Saudi Med J.* 36(12): 1439-1445.
- 3- Baazeem A, Belzile E, Ciampi A, Dohle G, Jarvi K, Salonia A, et al. (2011). Varicocele and male factor infertility treatment: a new meta-analysis and review of the role of varicocele repair. *Eur Urol.*60:796-808.
- 4- Belay RE, Huang GO, Shen JK, Ko EYK. (2016). Diagnosis of clinical and subclinical varicocele: how has it evolved?. *Asian J Androl.* 18 (2): 182-185.
- 5- Caskurlu T, Tasci AI, Resim S, Sahinkanat T, Ekerbicer H. (2003). Reliability of venous diameter in the diagnosis of subclinical varicocele. *Urol Int.*71:83-86.
- 6- Chiba K, Fujisawa M. (2016). Clinical Outcomes of Varicocele Repair in Infertile Men: A Review. *World J Mens Health.* 34 (2): 101-109.
- 7- Cho KS, Seo JT. (2014). Effect of Varicocelectomy on Male Infertility. *Korean J Urol.* 55(11): 703-709.
- 8- Choi WS, Kim SW. (2013). Current issues in varicocele management: a review. *World J Mens Health.* 31(1):12-20.
- 9- Cil AS, Bozkurt M, Bozkurt DK, Gok M. (2015). Investigating the relationship between persistent reflux flow on the first postoperative day and recurrent varicocele in varicocelectomy patients. *J Clin Med Res.* 7 (1): 29-32.
- 10- Cina A, Minnetti M, Pirronti T, Spampinato MV, Canade A, Oliva G. et al. (2006). Sonographic quantitative evaluation of scrotal veins in healthy subjects: normative values and implications for the diagnosis of varicocele. *Eur Urol.* 50:345-350.
- 11- Dawoud MA, Abo-Dewan Kh A, Hefeda MM. (2014). Preoperative sonographic and Doppler parameters predictors of semen analysis improvement after unilateral varicocelectomy. *The Egyptian Journal of Radiology and Nuclear Medicine.* 45 (2): 583-589.
- 12- El-Haggag S, Nassef S, Gadalla A, Latif A, Mostafa T. (2012). Ultrasonographic parameters of the spermatic veins at the inguinal and scrotal levels in varicocele diagnosis and post-operative repair. *Andrologia.* 44 (3): 210-213.
- 13- Gat Y, Bachar GN, Zukerman Z, Belenky A, Gorenish M. (2004). Physical examination may miss the diagnosis of bilateral varicocele: a comparative study of 4 diagnostic modalities. *J Urol.*172:1414-1417.
- 14- Gonda RL, Jr, Karo JJ, Forte RA, O'Donnell KT. (1987). Diagnosis of subclinical varicocele in infertility. *AJR.*148:71-75.
- 15- Jungwirth A, Giwercman A, Tournaye H, Diemer T, Kopa Z, Dohle G, et al. (2012). European Association of Urology guidelines on Male Infertility: the 2012 Update. *Eur Urol.* 62:324-332.
- 16- Karami M, Mazdak H, Khanbabapour S, Adibi A, Nasr N. (2014). Determination of the best position and site for color Doppler ultrasonographic evaluation of the testicular vein to define the clinical grades of varicocele ultrasonographically. *Adv Biomed Res.* 3: 17.
- 17- Kim TB, Chang JH, Yoon SJ, Kim SW. (2012). Hydrodynamic relationship between color doppler ultrasonography findings and the number of internal spermatic veins in varicoceles. *Yonsei Med J.* 53 (2): 386-392.
- 18- Kim YS, Kim SK, Cho IC, Min SK. (2015). Efficacy of scrotal Doppler ultrasonography with the Valsalva maneuver, standing position, and resting-Valsalva ratio for varicocele diagnosis. *Korean J Urol.* 56 (2): 144-149.
- 19- Kocakoc E, Serhatlioglu S, Kiris A, Bozgeyik Z, Ozdemir H, Bodakci N. (2003). Color doppler sonographic evaluation of inter-relations between diameter, reflux and flow volume of testicular veins in varicocele. *Eur J Radiol.* 47 (3): 251-256.
- 20- Lee J, Bin Saleh S, Lo K, Jarvi K. (2008). Varicoceles: The diagnostic dilemma. *Journal of Andrology.* 29 (2): 143-146.
- 21- Liguori G, Trombetta C, Garaffa G, Bucci S, Gattuccio I, Salamè L, et al. (2004). Color Doppler ultrasound investigation of varicocele. *World J Urol.* 22 (5): 378-381.
- 22- Lorenc T, Krupniewski L, Palczewski P, Gołębowski M. (2016). The value of ultrasonography in the diagnosis of varicocele. *J Ultrason.* 16 (67): 359-370.
- 23- Miyaoka R, Esteves SC. (2012). A Critical Appraisal on the Role of Varicocele in Male Infertility. *Adv Urol.* 2012: 1-9.
- 24- Pastuszak AW, Wang R. (2015). Varicocele and testicular function. *Asian J Androl.* 17 (4): 659-667.
- 25- Pauroso S, Di Leo N, Fulle I, Di Segni M, Alessi S, Maggini E. (2011). Varicocele: ultrasonographic assessment in daily clinical practice. *J Ultrasound.*14:199-204.
- 26- Pilatz A, Altinkilic B, Kohler E, Marconi M, Weidner W. (2011). Color Doppler ultrasound imaging in varicoceles: Is the venous diameter sufficient for predicting clinical and subclinical varicocele? *World J Urol.* 29: 645-650.
- 27- Prasivoravong J, Marcelli F, Lemaître L, Pigny P, Ramdane N, Peers MC, et al. (2014). Beneficial effects of varicocele embolization on semen parameters. *Basic Clin Androl.* 24: 9.
- 28- Roque M, Esteves SC. (2016). A systematic review of clinical practice guidelines and best practice statements for the diagnosis and management of varicocele in children and adolescents. *Asian Journal of Andrology.* 18: 1-7.
- 29- Sakamoto H, Saito K, Shichizyo T, Ishikawa K,

- Igarashi A, Yoshida H. (2006). Color Doppler ultrasonography as a routine clinical examination in male infertility. *Int J Urol.* 13 (8): 1073–1078.
- 30- Shridharani A, Owen RC, Elkelany O, Kim ED. (2016). The significance of clinical practice guidelines on adult varicocele detection and management. *Asian J Androl.* 18: 269–275.
- 31- Stahl P, Schlegel PN. (2011). Standardization and documentation of varicocele evaluation. *Curr Opin Urol.* 21(6): 500-505.
- 32- Tiseo BC, Esteves SC, Cocuzza SM. (2016). Summary evidence on the effects of varicocele treatment to improve natural fertility in subfertile men. *Asian J Androl.* 18 (2): 239–245.
- 33- Tsili AC, Xiropotamou ON, Sylakos A, Maliakas V, Sofikitis N, Argyropoulou MI. (2017). Potential role of imaging in assessing harmful effects on spermatogenesis in adult testes with varicocele. *World J Radiol.* 9 (2): 34-45.
- 34- Valentino M, Bertolotto M, Derchi L, Pavlica P. (2014). Children and adults varicocele: diagnostic issues and therapeutical strategies. *J Ultrasound.* 17 (3):185–193.



## تقويم دوالي الخصية باستخدام التصوير الدوبلر الملون بالموجات فوق الصوتية: الوضع والموقع الأفضل للحصول على أمثل قياس لقطر الوريد

وديع سعيد بن غوث

جمال عمر باحبارة

### الملخص

الغرض من هذه الدراسة هو تحديد أفضل وضع وموقع لفحص الوريد الخصوي بالدوبلر الملون بالموجات فوق الصوتية للحصول على القياس الأمثل لقطره. خلال الأشهر الستة الأولى من عام 2017، 89 مريضاً تتراوح أعمارهم بين 22-48 عاما ثبت أن لديهم دوالي الخصية شملوا في الدراسة. تم إجراء التصوير الدوبلر الملون باستخدام ترانزديوسر خطي 7.5 ميغا هرتز، وتم قياس قطر الوريد الخصوي الأكبر في ثلاثة مواقع مختلفة في وضعي الاستلقاء والوقوف بدون و مع إجراء فالسالفا. تم تصنيف دوالي الخصية للمرضى وفقا لقطر الوريد الأكبر في وضع الاستلقاء-الراحة إلى: درجة 0: أقل من 2 مم، درجة 1: 2-3 مم، درجة 2: أكثر من 3 مم، وتمت مقارنة التغيرات في قياس القطر في تلك الدرجات. كانت الحافة الجانبية-الخلفية لكيس الصفن أفضل موقع لقياس أقصى قطر للوريد تليها منطقة رأس البربخ، وكان أكبر قطر للوريد تم قياسه في وضع الوقوف مع استخدام إجراء فالسالفا. وهكذا فإن أفضل وضع وموقع لفحص الدوبلر الملون لمرضى دوالي الخصية هو وضعية الوقوف مع إجراء فالسالفا على الحافة الجانبية-الخلفية لكيس الصفن تليها منطقة رأس البربخ. **الكلمات المفتاحية:** فحص الدوبلر الملون بالموجات فوق الصوتية، إجراء فالسالفا، دوالي الخصية.