

10-10-2017

Regenerative treatment of an immature tooth with apical periodontitis using Platelet- Rich Fibrin and MM-MTA: a case report

Maria MOUKARZEL

Issam KHALIL

Follow this and additional works at: <https://digitalcommons.aaru.edu.jo/iajd>

Recommended Citation

MOUKARZEL, Maria and KHALIL, Issam (2017) "Regenerative treatment of an immature tooth with apical periodontitis using Platelet- Rich Fibrin and MM-MTA: a case report," *International Arab Journal of Dentistry*. Vol. 8: Iss. 3, Article 2.

Available at: <https://digitalcommons.aaru.edu.jo/iajd/vol8/iss3/2>

This Original Article is brought to you for free and open access by Arab Journals Platform. It has been accepted for inclusion in International Arab Journal of Dentistry by an authorized editor. The journal is hosted on [Digital Commons](#), an Elsevier platform. For more information, please contact rakan@aar.edu.jo, marah@aar.edu.jo, u.murad@aar.edu.jo.

REGENERATIVE TREATMENT OF AN IMMATURE TOOTH WITH APICAL PERIODONTITIS USING PLATELET-RICH FIBRIN AND MM-MTA: A CASE REPORT

Maria Moukarzel* | Issam Khalil**

Abstract

This case report describes the treatment of a necrotic immature permanent central incisor with symptomatic apical periodontitis, which was not treated with conventional apexification techniques. Instead, a regenerative approach based on the literature's methods for regeneration was provided. The root canal was gently debrided of necrotic tissue with a large diameter file, irrigated with 5,25% NaOCl and then medicated with 2% chlorhexidine. After 21 days, the tooth was asymptomatic. The canal was accessed and irrigated with saline solution and a tissue scaffold was created with PRF (Platelet-Rich Fibrin) prepared using centrifugation. The final restoration was completed immediately with MM-MTA and a composite resin. The tooth was controlled every three months over a period of 2 years and has remained symptom free. Radiographic examination shows healing of the apical radiolucency suggesting that appropriate biologic responses can occur with this type of treatment of the necrotic immature permanent tooth.

Keywords: Platelet-rich fibrin - regeneration - immature tooth - apical periodontitis.

IAJD 2017;8(3):87-93.

TRAITEMENT RÉGÉNÉRATIF D'UNE DENT IMMATURE AVEC PARODONTITE APICALE EN UTILISANT DE LA FIBRINE RICHE EN PLAQUETTES ET DU MM-MTA: A PROPOS D'UN CAS

Résumé

Ce rapport de cas décrit le traitement d'une incisive centrale permanente immature atteinte de nécrose pulpaire compliquée d'une parodontite apicale symptomatique non traitée par les techniques classiques d'apexification. Une approche régénératrice basée sur les méthodes de régénération décrites dans la littérature a été appliquée. Le canal radiculaire a été débridé du tissu nécrotique avec une lime de grand diamètre, irrigué avec 5,25% de NaOCl et ensuite rempli d'un produit antiseptique à base de chlorhexidine 2%. Vingt et un jours plus tard la dent était complètement asymptotique. L'accès au canal a donc été effectué ainsi qu'une irrigation avec une solution saline et la pose d'une matrice tissulaire de et la création d'une matrice tissulaire de FRP (fibrine riche en plaquettes) préparée par centrifugation. La restauration finale a été complétée immédiatement avec MM-MTA et une résine composite. La dent a été contrôlée tous les trois mois sur une période de 2 ans et est restée asymptotique. L'examen radiographique a montré la guérison de la radioclarité apicale suggérant que des réponses biologiques appropriées pouvaient se produire avec ce type de traitement au niveau d'une dent permanente immature nécrosée.

Mots clés : fibrine enrichie en plaquettes - régénération - dent immature - parodontite apicale.

IAJD 2017;8(3):87-93.

* DDS, Master in Endodontics,
Dpt of Endodontics, Faculty of Dental Medicine,
Saint-Joseph University, Beirut, Lebanon
moukarzelmaria@gmail.com

** PhD, WIPO, MMMTA,
Head of Endodontics Dpt,
Faculty of Dental Medicine,
Saint-Joseph University, Beirut, Lebanon

Introduction

Trauma and /or carious exposure in immature permanent teeth can lead to pulp necrosis and arrested root development [1]. The consequences of interrupted development include a poor crown/root ratio, very thin root canal walls, an increased risk of root fracture and an open apex [2]. It is reported in the literature that 25% of schoolchildren suffer dental trauma while 33% of adults have experienced trauma affecting the permanent dentition with a majority of accidents occurring before 19-years-old [3]. It is important to emphasize that these cases are often poorly managed and the pulp necrosis promotes the development of apical periodontitis. Traditionally, the open apex is managed by a root end closure technique using calcium hydroxide (apexification) [4, 5]. More recently, the placement of mineral trioxide aggregate as an apical barrier has been advocated [6, 7]. Whilst both of these techniques have been shown to have good long-term success [8, 9] in the absence of continued root development, they do not help strengthen the root, rendering it prone to fracture.

The ideal treatment of these immature teeth with necrotic pulps and apical periodontitis (symptomatic or not) would be to stimulate the regeneration of the pulp-dentin complex to obtain further root development [10, 11]. Regenerative endodontic procedures are defined as biologically based procedures designed to replace damaged cells and structures with live viable tissues, which restore the normal physiologic functions [12]. Regeneration can be achieved through the activity of cells from the pulp, periodontium, vascular or immune systems [12] or alternatively through stem cells therapies [13]. There are numerous case reports and series in the literature reporting the use of regeneration/revascularization procedures to treat immature permanent teeth with necrotic pulps with or without apical periodontitis [1, 2, 14 - 21]. These case reports and series have demonstrated radiographical evidence

of increased root length and thickening of the root walls with apical closure.

During the year 2001, Choukroun introduced the Platelet-Rich Fibrin (PRF) to be used for guided bone regeneration procedures around implants and sinus lifts [22 - 24]. This seemed interesting in surgery and attempts were made to regenerate the pulp of immature teeth using the PRF as a scaffold to provide a spatially correct position of stem cells with growth factors [16].

In this case report we describe and discuss the use of PRF covered with MM-MTA (Micro-Mega, Besançon, France) to stimulate the continuous root development of a necrotic immature tooth with symptomatic apical periodontitis.

Case report

A10-year-old girl was referred complaining of pain from the maxillary left central incisor [21]. The pain had been present for several days. There was a history of trauma some 3-4 months previously but the patient did not seek any treatment at the time. There was no relevant medical history. Clinical examination revealed redness of the gingival tissues. The tooth was tender to percussion. Thermal test was negative. Specifically, there was no response to Dry ice (CO₂ ICE / Odontest Pulp Thermal test; Miltex New York, NY, USA). Periodontal probing depths were within normal limits. Radiographic examination (digital x-ray, Digora Optime Soredex, Finland) revealed periapical disease with an incomplete root development and a very wide-open apex (Fig. 1). The tooth was diagnosed with a symptomatic apical periodontitis associated with a necrotic pulp. The treatment plan was to explore the possibility of carrying out a regeneration procedure in two visits using PRF and MM-MTA (Micro-Mega MTA, Besançon, France) after root canal disinfection with 5, 25% sodium hypochlorite and 2% chlorhexidine gluconate. The treatment plan was agreed and appropriate consent obtained.

Local anesthetic infiltration was given using 3% Scandicaine without epinephrine (Mepivacaine Septodont, Saint-Maur des Fosses, France) after the alveolar mucosa was smeared with a topical anesthetic gel (20% Benzocaine, Sultan) over tooth #21. Under rubber dam isolation (Hygenic Coltene/Whaledent, Germany) the pulp chamber was accessed using a round diamond bur and an Endo-Access bur (Dentsply Maillefer, Ballaigues, Switzerland) in an air turbine hand-piece with copious irrigation (NSK, PANA Air, Nakanishi Inc., Tochigi-Ken, Japan).

The canal was gently debrided using one manual shaping file (80 K-file, Dentsply Maillefer, Ballaigues, Switzerland) and irrigated with a solution of sodium hypochlorite 5,25% to flush out gross debris using a 3-mL Leuer Lock syringe with a 27-G irrigating needle tip (Monoject endodontic irrigating syringe Covidien, Henry Schein dental, USA). The canal length was measured using the same 80 K-file (Dentsply-Maillefer) and a Root ZX mini apex locator (J Morita, MFG Corp., Kyoto, Japan). Once the working length was established and confirmed by a radiograph, the canal was irrigated with 18 ml of NaOCl (Clorox 5,25%, Spartan, Egypt) and dried with sterile absorbent paper points (Coarse, Dentsply Maillefer). It was then filled with 2% Chlorhexidine (Calaplast) for three weeks. A sterile cotton pellet was covered with 4 mm of Cavit G (Espe, Seefeld, Germany) to provisionally seal the access cavity.

A second appointment was set 3 weeks later. During this session, preparation of PRF was performed. Venous blood (10 mL) was transferred to the tubes, which were centrifuged at 2700 rpm for 12 minutes. Initial centrifugation produced 3 distinct layers, namely a layer of red blood corpuscles and leukocytes at the bottom, a layer of platelet concentrate, fibrin clot and a top layer, the supernatant, which is the cell-free plasma, acellular plasma or platelet-poor plasma. The absence of anticoagulant allows massive and

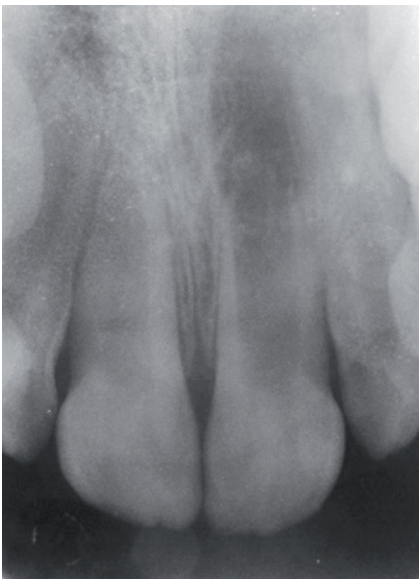

Fig. 1: Pre-operative x-ray (February 2014).

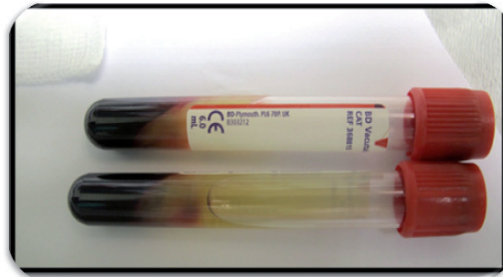

Fig. 2a: PRF in the tubes after centrifugation.

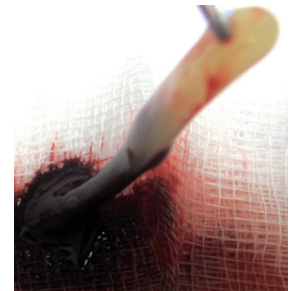


Fig. 2b: PRF extracted with the tweezers.

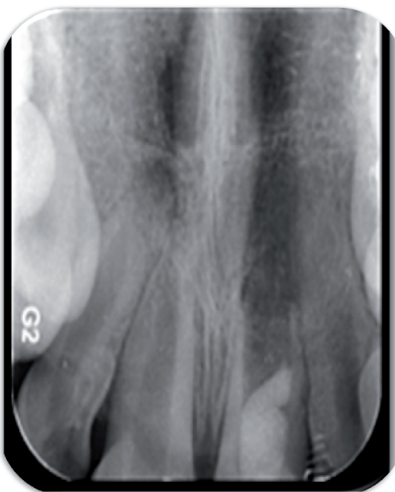

Fig. 3: X-ray taken after second session and setting of the PRF and MM-MTA.

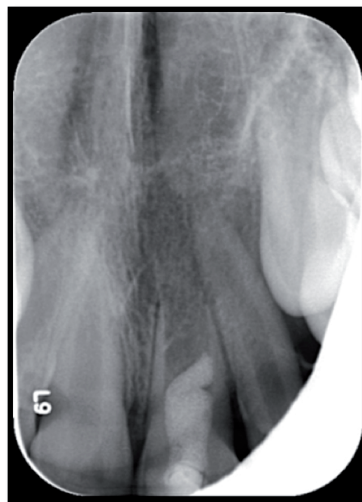


Fig. 4: X-ray taken after 3 months.

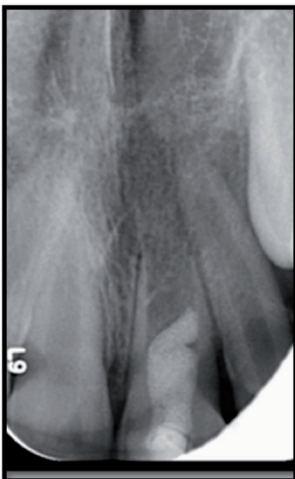


Fig. 5: X-ray taken after 6 months.

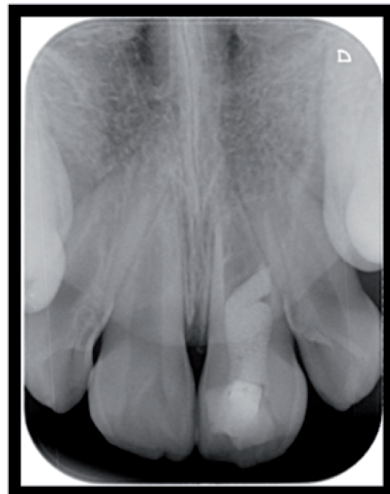

Fig. 6: After 18 months.

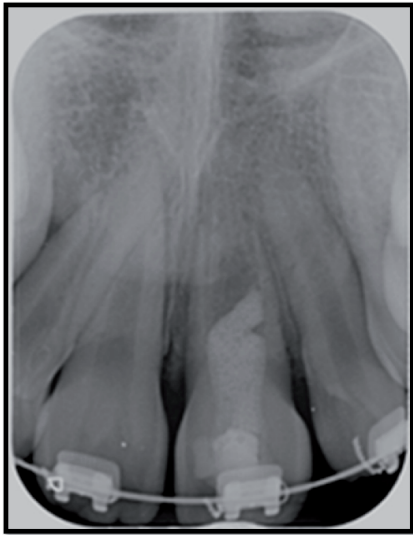


Fig. 7: 2 years later: Healing of the periapical periodontitis.

rapid platelet activation and initiation of coagulation. Once separated from the red cells, the clot has to be removed and the operation must be fast, otherwise, coagulation begins resulting in an unstable polymerization of fibrin (Fig. 2).

After irrigating the canal with 9 mL of sterile saline to remove the Chlorhexidine, the canal was dried with sterile paper points and the PRF was introduced in the canal. A layer of MM-MTA (4 mm) covered the PRF and a wet cotton pellet placed over for 15 minutes to allow the initial setting of the material. The tooth was then restored with a composite (3M ESPE Filtek Z250 XT, 2510 Conway Avenue St. Paul, MN 55144-1000 USA) during the same session.

Radiographic controls were taken on a 3months basis (3 months / 6 months, until 2 years), to assess apical closure and continuous root edification, decrease of the periapical radiolucency, and thickening of the root canal walls.

Discussion

Tissue regeneration using revascularization to induce apexogenesis rather than tissue replacement using artificial substitutes is a relatively

new treatment modality for infected, immature teeth with necrotic pulps [16].

According to some authors [19, 25, 26], there are three key steps to revascularization /regeneration procedures (i) disinfecting the canal system, [ii] inducing bleeding to form a blood clot or placement of a suitable matrix into which new tissue can grow and (iii) a bacteria-resistant coronal seal [1].

A necrotic immature tooth has an infected canal space with very thin and divergent canal walls. Mechanical instrumentation is not indicated in these cases because of this fragile and delicate structure, which might lead to fracture and jeopardize the future of the tooth [27].

However, controlling infection in the canal space is an important initial step in the revascularization/regeneration process [1]. It is also suggested that a higher level of disinfection is required for pulp regeneration. Two in vitro studies conducted by Hoshino et al. and Sato et al. [28, 29] showed that the mixture of ciprofloxacin, metronidazole and minocycline was effective against endodontic pathogens and was able to disinfect into the dentine tubules. This antibiotic mixture has become known as Hoshino's paste.

Both Windley et al. and Cohenca et al. [30, 31] have shown that irrigation with sodium hypochlorite followed by triple antibiotic paste renders 70-78% of the canals culture negative. This protocol has become the basis for disinfection in revascularization cases. Most of the studies used Hoshino's triantibiotic paste as the intracanal medicament of choice in the disinfection process for the treatment of nonvital immature teeth undergoing revascularization treatment [2, 10, 17, 21, 25, 32]. However, there are issues regarding possible sensitivity and bacterial resistance to some of the used medicaments [31, 33], and staining or possible discoloration of the tooth has been reported [19], so others have used calcium hydroxide [25] and one study used formocresol [16].

Calcium hydroxide, which has been extensively used in apexification procedures [34], has antibacterial properties due among others to its high pH, but the proteolytic action of calcium hydroxide tends to reduce the organic support due to disruption of links between collagen fibers and hydroxyapatite crystals. This reduction in microhardness of dentine may impact adversely on dentine fracture resistance [5, 35].

2% chlorhexidine (CHX) was used as a temporary medication in the present case. Chlorhexidine is an antibacterial

agent with a broad spectrum, effective against both *E. faecalis* and *Candida albicans* like 5,25% sodium hypochlorite solution [36]. Its antibacterial properties are due to an alkaline pH and a continuous release of OH⁻ ions [37]. In addition, chlorhexidine is adsorbed and released by dental tissues, this long-term antibacterial activity is known as “substantivity” and has been demonstrated in vitro when chlorhexidine has been used in association with different vehicles i.e. liquids, gels, or devices for controlled release [38].

One of the mechanisms that may explain its effectiveness is based on the interaction between the positive charge of the molecule and the negative charged phosphate groups present on the bacterial cell wall, which allows CHX molecule to penetrate inside the bacteria [39, 40].

Paquette (2007) [41] showed that 2% chlorhexidine gluconate solution used as intracanal medication for 7 to 15 days reduced bacterial concentration and Gomes (2009) [42] added that CHX was able to diffuse into the dentine tubules and reach the outer surface of the root, exerting its antimicrobial activity.

Subsequent to disinfection, an appropriate scaffold is needed to promote cell growth and differentiation [15]. Thibodeau et al. [14] showed that roots containing a blood clot after disinfection had better treatment outcomes in a dog model than those that did not have a blood clot in the apical part of the canal. It is considered that the presence of blood clot in canal space provides a fibrin scaffold that would promote the regeneration of tissue in root canal space [10, 14]. However, the induction and maintenance of a blood clot is extremely difficult in revascularization procedures and appears to be its limitation [17].

Platelet-rich fibrin, a second-generation platelet concentrate can be considered as an autologous healing biomaterial incorporating leucocytes, platelets and wide range of key healing proteins in a dense fibrin matrix [43]. Unlike platelet-rich plasma, PRF pre-

paration eliminates the redundant process of adding anticoagulants or bovine thrombin making it similar to centrifuged natural blood. Furthermore, a highly resistant and elastic membrane of fibrin is obtained [44], which allows a slow continuous release of cytokines such as platelet-derived growth factor (PDGF), transforming growth factor β 1 (TGF β 1) and vascular endothelial growth factor (VEGF) achieving peak level at 14th day coinciding with cell ingrowth. PRF enhances the proliferation of various cell types, stimulates cellular differentiation and supplements the angiogenesis. Lastly, the presence of leucocytes and cytokines along with small amounts of lymphocytes in PRF can play a significant role in the self-regulation of inflammatory and infectious phenomenon [45].

In the present case, freshly prepared PRF fragments were placed inside the canal space without inducing bleeding as a part of the planned revascularization procedure. There is a lack of evidence regarding handling and placement of PRF in the root canal space. From clinical experience, placement of PRF fragments incrementally is more convenient than placing the membrane as a whole [20]. Another benefit of using a different scaffold than the blood clot would be the placement of MTA that could be more idealized. MM-MTA (Micro-Mega, Besançon, France) that has been shown to have excellent sealing properties [46] was placed directly over PRF to obtain a coronal seal.

Most of the case reports/series have shown an increase in root length and dentinal wall thickening with a reduction in the volume of the canal space radiographically [1, 2, 14 - 21]. Clinically the teeth were symptom free. This case report showed a similar clinic and radiographic outcome. However, where histological analysis of teeth, which had undergone revascularization treatment, was possible, the mineralized layer on the walls, which was observed, appeared to be of periodontal origin rather than pulpal origin. This histological outcome was obser-

ved in two case reports one of which had been revascularized by simple blood clot [47] and the other had used platelet-rich plasma [48]. This suggests that the new tissue was not of dentinogenic origin and highlights the shortcomings of dental radiography for characterizing new mineralized tissue in endodontics [49].

From a clinical perspective, the true origin of this tissue may not matter [49]. If the objective is to induce healing of the periapical tissues, stimulate bone regeneration and render the patient free from signs and symptoms, then this current case report can be deemed a clinical success. However, it may not exhibit “true” biological pulp regeneration but the filling of the root canal space with a vital biological tissue, which has further repair and defense capabilities. This represents a step forward when compared to gutta-percha or MTA [49]. Whether this revascularization process improves the root strength remains to be seen.

Conclusion

Platelet-rich fibrin is a potential scaffold in pulp revascularization procedures, as it is rich in growth factors, enhances cellular proliferation and differentiation, augments angiogenesis, acts as a matrix for tissue ingrowth, regulates inflammation reactions and has anti-infective properties. Additionally, it acts as an excellent matrix to support MTA placement. The disadvantages of using PRF include the requirement of special equipment, the invasive procedure of drawing blood in young patients, difficulty in handling and placing inside the canal space and increased cost of treatment. However, long-term clinical trials and histological studies are required to analyze the benefits of using PRF in revascularization/regeneration procedures.

References

- McCabe P. Revascularization of an immature tooth with apical periodontitis using a single visit protocol: a case report. *Int Endod J* 2005;48:484-97.
- Cotti E, Mereu M, Lusso D. Regenerative treatment of an immature, traumatized tooth with apical periodontitis: report of a case. *J Endod* 2008;34:611-6.
- Glender U. Epidemiology of traumatic dental injuries: a 12 year review of the literature. *Dent Traumatol* 2008;24:603-11.
- Cvek M. Prognosis of luxated non-vital maxillary incisors treated with calcium hydroxide and filled with gutta-percha. A retrospective clinical study. *Endod and Dental Traumatol* 1992;8:45-55.
- Andreasen JO, Farik B, Munksgaard EC. Long-term calcium hydroxide as a root canal dressing may increase risk of root fracture. *Dental Traumatol* 2002;18:134-7.
- Shabahang S, Torabinejad M. Treatment of teeth with open apices with mineral trioxide aggregate. *Pract Periodontics Aesth Dent* 2000;12:315-20.
- Steinig TH, Regan JD, Gutmann JL. The use and predictable placement of mineral trioxide aggregate in one visit apexification cases. *Aust Endod J* 2003;29: 34-42.
- Ghose LJ, Baghdady VS, Hikmat YM. Apexification of immature apices of pulpless permanent anterior teeth with calcium hydroxide. *J Endod* 1987;13:285-90.
- Felippe WT, Felippe MC, Rocha MJ. The effect of mineral trioxide aggregate on the apexification and periapical healing of teeth with incomplete root formation. *Int Endod J* 2008;39:2-9.
- Banchs F, Trope M. Revascularisation of immature permanent teeth with apical periodontitis; new treatment protocol? *J Endod* 2004;30:196-200.
- Cheuh L-H, Huang GT-J. Immature teeth with periradicular periodontitis or abscess undergoing apexogenesis: a paradigm shift. *J Endod* 2006;32:1205-13.
- Garcia-Godoy F, Murray PE. Recommendations for using regenerative endodontic procedures in permanent immature traumatized teeth. *Dent Traumatol* 2012;28:33-41.
- Srisuwan T, Tikorn DJ, Al-Benna S, Abberton K, Messer HH, Thompson EW. Revascularisation and tissue regeneration of an empty root canal space is enhanced by a direct blood supply and stem cells. *Dent Traumatol* 2013;29:84-91.
- Thibodeau B, Teixeira F, Yamauchi M, Caplan DJ, Trope M. Pulp revascularization of immature dog teeth with apical periodontitis. *J Endod* 2007;33:680-689.
- Jung IY, Lee SJ, Hargreaves KM. Biologically based treatment of immature permanent teeth with pulpal necrosis: a case series. *J Endod* 2008;34:876-87.
- Shah N, Logani A, Bhaskar U, Aggarwal V. Efficacy of revascularization to induce apexification/apexogenesis in infected, nonvital, immature teeth: A pilot clinical study. *J Endod* 2008;34:919-25.
- Petrino JA, Boda KK, Shambarger S, Bowles WR, McClanahan SB. Challenges in regenerative endodontics: a case series. *J Endod* 2010;36:536-41.
- Cehreli ZC, Isbitirgin B, Sara S, Erbas. Regenerative endodontic treatment (revascularization) of immature necrotic molars medicated with calcium hydroxide: a case series. *J Endod* 2011;37:1327-30.
- Nosrat A, Homayounfar N, Oloomi K. Drawbacks and unfavorable outcomes of regenerative endodontic treatments of necrotic immature teeth: a literature review and report of a case. *J Endod* 2012;38:1428-34.
- Keswani D, Pandey RK. Revascularisation of an immature tooth with a necrotic pulp using platelet rich fibrin: a case report. *Int Endod J* 2013;46:1096-104.
- Bezgin T, Yilmaz AD, Celik BN, Sonmez H. Concentrated platelet rich plasma used in root canal revascularization; 2 case reports. *Int Endod J* 2014;47: 41-9.
- Choukroun J, Adda F, Schoffler C, Vervelle A. Une opportunit e en paro-implantologie : le PRF. *Implant* 2001;42:55-62.
- Dohan DM, Choukroun J, Diss A, Dohan SL, Dohan AJ, Mouhyi J, Gogly B. Platelet- Rich Fibrin (PRF): a second-generation platelet concentrate. Part I: technological concepts and evolution. *Oral Surg Oral Med Oral Path Oral Radiol Endod* 2006;101:37-44.
- Gabling W, Volker L, Yahya A. Platelet-rich Plasma and Platelet-rich fibrin in human cell culture. *Oral Maxillofac implants* 2009;108:48-55.
- Ding RY, Cheung SP, Chen J, Yin XZ, Wang QQ, Zhang C. Pulp revascularization of immature teeth with apical periodontitis: a clinical study. *J Endod* 2009;35:745-9.
- Jadhav G, Shah N, Logani A. Revascularization with and without platelet-rich plasma in nonvital, immature, anterior teeth: a pilot clinical study. *J Endod* 2012;38:1581-7.
- Wang Z, Pan J, Wright JT, Bencharit S, Zhang S, Everett ET, Teixeira FB, Preisser JS. Putative stem cells in human dental pulp with irreversible pulpitis: an exploratory study. *J Endod* 2010;36:820-25.
- Hoshino E, Ando-Kurihara N, Sato I, Uematsu H, Sato M, Kota K, Iwaku M. In vitro antibacterial susceptibility of bacteria taken from infected root dentine to a mixture of ciprofloxacin, metronidazole and minocycline. *Int Endod J* 1996;29:125-30.
- Sato I, Ando-Kurihara N, Kota K, Iwaku M, Hoshino E. Sterilization of infected root-canal dentine by topical application of a mixture of ciprofloxacin, metronidazole and minocycline in situ. *Int Endod J* 1996;29:118-24.
- Windley W, Teixeira F, Levin L, Sigurdsson A, Trope M. Disinfection of immature teeth with a triple antibiotic paste. *J Endod* 2005;31:439-43.
- Cohenca N, Heilborn C, Johnson JD, Flores DS, Ito IY, da Silva LA. Apical negative pressure irrigation versus conventional irrigation plus triantibiotic intracanal dressing on root canal disinfection in dog teeth. *Oral Surg Oral Med Oral Path Oral Rad Endod* 2010;109:42-6.
- Iwaya SI, Ikawa M, Kubota M. Revascularisation of an immature permanent tooth with apical periodontitis and sinus tract. *Dent Traumatol* 2001; 17:185-7.
- Ding Q1, Lee YK, Schaefer EA, Peters DT, Veres A, Kim K, et al. A TALEN genome-editing system for generating human stem cell-based disease models. *Cell Stem Cell* 2013; 12, 238-251
- Rafter M. Apexification: a review. *Dent Traumatol* 2005; 21, 1-8.
- Bottino MC, Kamocki K, Yassen GH, Platt JA, Vail MM, Ehrlich Y, Spolnik KJ, Gregory RL. Bioactive nanofibrous scaffolds for regenerative endodontics. *J Dent Res* 2013; 11: 963-9.
- Elakanti S, Cherukuri G, Rao VG, Chandrasekhar V, Rao SA, Tummala M. Comparative evaluation of antimicrobial efficacy of

- QMix™ 2 in 1, sodium hypochlorite, and chlorhexidine against *Enterococcus faecalis* and *Candida albicans*. *J Cons Dent* 2015; 18, 128-131.
37. Tronstad L, Andreasen JO, Hasselgren G, Kristerson L, Riis I. pH changes in dental tissues after root canal filling with calcium hydroxide. *J Endod* 1981; 7, 17-21.
 38. Ferraz CC, Gomes BP, Zaia AA, Teixeira FB, Souza –Fillo FJ. In vitro assessment of the antimicrobial action and the mechanical ability of chlorhexidine gel as an endodontic irrigant. *J Endod* 2001; 27, 452-5.
 39. Lindskog S, Pierce AM, Blomlöf L. Chlorhexidine as a root canal medicament for treating inflammatory lesions in the periodontal space. *Endod Dent Traumatol* 1998; 14, 186-90.
 40. Denton G.W. Chlorhexidine. In: *Disinfection, Sterilization and preservation*. Block SS (Editor). 4th ed. Philadelphia, Lea & Febiger 1991; 274-289.
 41. Paquette L, Milos L, Fillery ED, Friedman S. Antibacterial efficacy of chlorhexidine gluconate intracanal medication in vivo. *J Endod* 2007; 33, 788-95.
 42. Gomes BP, Montagner F, Berber VB, Zaia AA, Ferraz CC, de Almeida JF, Souza-Filho FJ. Antimicrobial action of intracanal medicaments on the external root surface. *J Dent* 2009; 37, 76-81
 43. Del Corso M, Vervelle A, Simonpieri A, Jimbo R, Inchingolo F, Sammartino G, Dohan Ehrenfest DM. Current knowledge and perspectives for the use of platelet-rich plasma (PRP) and platelet-rich fibrin (PRF) in oral and maxillofacial surgery part 1: Periodontal and dentoalveolar surgery. *Curr Pharm Biotech* 2012; 13, 207–30.
 44. Lucarelli R, Beretta R, Dozza B, Donati MD. A recently developed bifacial platelet-rich fibrin matrix. *European cells & materials* 2010; 20, 13-23.
 45. Toffler M, Toscano N, Holtzclaw D, Corso MD, Dohan Ehrenfest DM. Introducing Choukroun's Platelet Rich Fibrin (PRF) to the Reconstructive Surgery Milieu. *J Imp Adv Clin Dent* 2009; 1, 21-32
 46. Khalil I, Naaman A, Camilleri J. Investigation of a novel mechanically mixed mineral trioxide aggregate (MM-MTA™). *Int Endod J* 2014; 48, 757-67.
 47. Shimizu E, Ricucci D, Albert J, Alobaid AS, Gibbs JL, Huang GT, Lin LM. Clinical, Radiographic, and Histological Observation of a human immature permanent tooth with chronic apical abscess after revitalization treatment. *J Endod* 2013; 39, 1078-83.
 48. Martin G, Ricucci D, Gibbs JL, Lin LM. Histological findings of revascularized/revitalized immature permanent molar with apical periodontitis using platelet-rich plasma. *J Endod* 2013; 39(1), 138-44.
 49. Simon S, Smith AJ. Regenerative endodontics. *Brit Dent J* 2014; 216(6):E13
-