

2021

Benign Skin and Conjunctivalnevus Versus Malignant Melanoma: ClinicPathological Study of 83 Cases in Aden

Saleh Salman Ba-Saleh
Faculty of Medicine, University of Aden.

Mazen Abood Bin Thabit
Faculty of Medicine, University of Aden.

Follow this and additional works at: https://digitalcommons.aaru.edu.jo/huj_nas



Part of the [Medicine and Health Sciences Commons](#)

Recommended Citation

Ba-Saleh, Saleh Salman and Bin Thabit, Mazen Abood (2021) "Benign Skin and Conjunctivalnevus Versus Malignant Melanoma: ClinicPathological Study of 83 Cases in Aden," *Hadhramout University Journal of Natural & Applied Sciences*: Vol. 14 : Iss. 1 , Article 4.

Available at: https://digitalcommons.aaru.edu.jo/huj_nas/vol14/iss1/4

This Article is brought to you for free and open access by Arab Journals Platform. It has been accepted for inclusion in Hadhramout University Journal of Natural & Applied Sciences by an authorized editor. The journal is hosted on [Digital Commons](#), an Elsevier platform. For more information, please contact rakan@aar.edu.jo, marah@aar.edu.jo, u.murad@aar.edu.jo.

Benign Skin and Conjunctivalnevus Versus Malignant Melanoma: Clinic-Pathological Study of 83 Cases in Aden

Saleh Salman Ba-Saleh*

Mazen Abood Bin Thabit **

Abstract

The study aimed to provide basic information of skin &conjunctival nevi and melanoma in Aden. The study was a retrospective review of patients' records and the data were analyzed through descriptive statistics. Of the 83 patients studied 32 (38.6%) were males and 51 (61.4%) were females. Patients ranged in age from 3 years to 70 years. The most frequent age range was 20 to 39 years 30 (36.2%) patients. The benign nevi lesions were 68 (81.9%) while malignant consists of 15(18.1%) patients. The site of lesions were predominant on skin with 65 (78.3%) followed by conjunctiva 18 (21.7%). Nevi lesions on face were 27 (32.5%), followed by lower limb and skin. The histological types of nevi lesions, junctional nevi 19 (22.9%) followed by intra-dermal nevi 18 (21.7%). There were 15 cases of melanoma. They were 10 (66.7%) males and 5 (33.3%) females, all the cases in the age range ≥ 50 years and most site of melanoma were on lower limb (foot) 12 (80%). They were 11 (73.3%) ulcerative and 4 (26.7%) tumorus. Only, we found 1 (6.7%) Lymph Nodes metastasis, and 13 (86.6%) in the Clark stage II. We concluded that the study may describe the problem of skin and conjunctival nevus. Further studies into this aspect are needed.

Key words: Information, skin, conjunctival, nevi, melanoma, Aden.

Introduction:

The term nevus is often used synonymously for a mole but it actually means any congenital lesion of the skin. Clinically, most nevi are small, usually less than 6 mm. They are usually flat or slightly raised and have even pigmentation or flesh coloration with sharply circumscribed borders [17].

Benign tumors of nevus cells are called melanocytic nevi, while malignant tumors are called malignant melanomas [5].

Melanocytic naevi are commonly classified on the basis of a mixture of clinical and histopathological criteria. They are initially classified as either acquired or congenital, both further subdivided into junctional, compound and dermal naevi based on the location of the

melanocytes within the epidermis, the dermis, or both [1].

Melanocytic lesions of the conjunctiva have diverse clinical and histopathologic features. They can be classified into nevi (congenital, which are present at birth or appearing within the first 6 months of life, and acquired), melanosis (congenital and acquired), intermediate melanocytic proliferations and malignant melanoma. The three types of melanocytes involved in these lesions are "dendritic," which are most commonly found in benign congenital and acquired conjunctivamelanosis, "nevus cells" found in subepithelial, junctional and compound nevi, and "fusiform cells," which are most commonly found in melanosis oculi and the nevus of Ota (12). Most conjunctival nevi appear later in childhood, puberty or early adulthood, and thus are considered acquired [6].

In dermatopathology, the term "nevus" is used to

* Department of Ophthalmology, Faculty of Medicine, University of Aden.

** Department of Morphological Sciences, Faculty of Medicine, University of Aden. Received on 6/12/2016 and Accepted for Publication on 17/5/2017

describe a variety of hamartomatous and/or neoplastic lesions. The term melanocytic nevus is generally considered a benign neoplastic proliferation of melanocytes [4].

The three most common types of conjunctival nevi are junctional, compound and subepithelial with a phase of growth followed by maturational self-arrest and a stationary phase. Therefore, these entities may represent different stages in maturation and proliferation of melanocytes with early junctional activity and further descent of the nevus cells into the substantiapropria (6,12). The differentiation between these benign nevi and other pigmented lesions is essential to determine appropriate management [6].

Objective: To provide basic information about the clinical presentation, the histopathologic main features and the frequency of skin & conjunctival nevi and melanoma in Aden

Material and methods:

The present study is a retrospective review of patients' records. Nevi lesions patients from Aden governorate and the surrounding areas referred to our histopathology laboratory for histological examination in Almansoor, Aden from 1st January 2012 to 31 December 2014 were included in the study.

The total number of patients was 83. The patients were diagnosed clinically.

The following patient variables were analyzed: sex, age, category of nevus, site of lesion and histological findings. Data were tabulated and analyzed through descriptive statistics in a Microsoft Excel spreadsheet.

Results:

Of the 83 patients studied 32 (38.6%) were males and 51 (61.4%) were females as shown in figure 1.

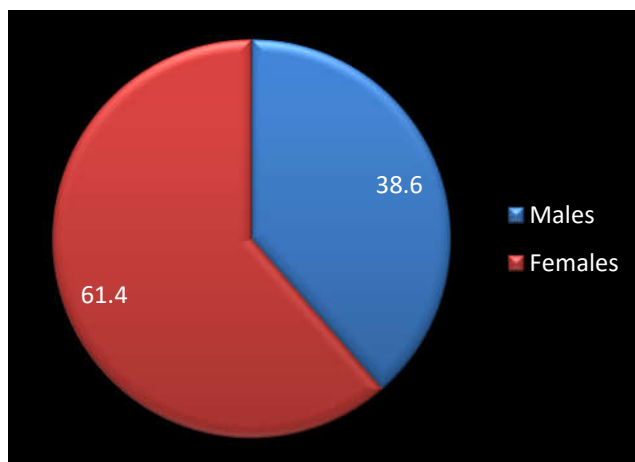


Figure 1: distribution of patients related to sex

Patients ranged in age from 3 years to 70 years. The most frequent age range was 20 to 39 years 30 (36.2%) patients.

Twenty six (31.3%) patients were under the age of 20 years and 18 (21.7%) patients were in the age group 60 years and more (Table 1).

Table 1: Distribution of patients related to age group

Age (years) Sex	< 20		20-39		40-59		≥ 60	
	No	%	No	%	No	%	No	%
Males	9	10.8	11	13.3	1	1.2	11	13.3
Females	17	20.5	19	22.9	8	9.6	7	8.4
Total	26	31.3	30	36.2	9	10.8	18	21.7

Table 2 shows the benign nevi lesions were 68 (81.9%) on skin with 65 (78.3%) followed by conjunctiva (21.7%) while malignant consists of 15 (18.1%) patients. Also the site of lesions was predominant

Table 2: Category and site of nevi

Variables	No	%
Category:		
Benign	68	81.9
Malignant	15	18.1
Site:		
Skin	65	78.3
Conjunctiva	18	21.7

Table 3 and figure 2 revealed distribution of nevi lesions on the bodies (skin & conjunctiva). The nevi lesions on face were 27 (32.5%), followed by lower limb and skin (NOS) for each one 14 (16.9%), trunk 7 (8.4%) and upper limb 3 (3.6%). The nevi lesions on conjunctiva were 18 (21.7%).

Table 3: Body distribution of nevi

Site	No	%
Face	27	32.5
Lower limb	14	16.9
Skin (NOS)	14	16.9
Trunk	7	8.4
Upper limb	3	3.6
Conjunctiva	18	21.7
Total	83	100

Table 4 illustrates the histological types of nevi lesions, junctional nevi 19 (22.9%) followed by intra-dermal nevi 18 (21.7%), sebaceous nevi 13 (15.7%), compound nevi 6 (7.2%), and the last one was dysplastic nevi 1 (1.2%).

Table 4: Histological distribution of skin & conjunctival nevi lesions

Type	No	%
Junctional nevi	19	22.9
Intra-dermal nevi	18	21.7
Sebaceous nevi	13	15.7
Compound nevi	6	7.2

Spitz nevi	3	3.6
Strawberry nevi	3	3.6
Cellular blue nevi	2	2.4
Dysplastic nevi	1	1.2
Others	3	3.6
Malignant melanoma	15	18.1
Total	83	100

Table 5 shows demographic variables and characters of the 15 cases of melanoma. They were 10 (66.7%) males and 5 (33.3%) females, all the cases in the age range ≥ 50 years and the site of melanoma were 12 (80%) on lower limb

(foot), ano-genital region 2 (13.3%) and eye 1 (6.7%). They were 11 (73.3%) ulcerative and 4 (26.7%) tumorous. Only, we found 1 (6.7%) LN metastasis, 13 (86.6%) and in the Clark stage II.

Table 5: Demographic variables & characters of malignant melanoma (n = 15)

Character	No	%
Sex:		
- Male	10	66.7
- Female	5	33.3
Age:		
< 50	0	0.0
≥ 50	15	100
Site:		
- lower limb (Foot)	12	80
- Ano genital region	2	13.3
- Eye	1	6.7
Shape:		
- Ulcerative	11	73.3
- Tumorous	4	26.7
Metastasis:		
- LN metastasis	1	6.7
- Distance metastasis	0	0.0
- No metastasis	14	93.3
Clark's stage:		
- Clark I	1	6.7
- Clark II	13	86.6
- Clark III	1	6.7
- Clark IV	0	0.0

Discussion:

A mole is a common benign skin lesion due to a local proliferation of pigment cells (melanocytes). It is more correctly called a melanocytic nevus and is sometimes also called a nevocytic nevus. A brown or black mole contains the pigment melanin, so may also be called a pigmented nevus [18]. Melanocytic lesions comprise a wide spectrum of tumors ranging

from small, macular lentiginous hyperplasias to congenital or acquired melanocytic nevi to malignant melanomas [19].

In the present study we found melanocytic nevi were more in females with a ratio male to female 1 : 1.6. This finding was to some extent similar to the study done in Augsburg region (KORA) in Germany [22] and less than that reported by

Laishram et al [13] .

In our study, the most frequent age range was 20 to 39 years 30 (36.2%) patients.

In our study, the most frequent age range was 20 - 39 years (36.2%). Similar finding was reported by Laishram et al [13] from India and Suzaki et al [25] from Japan . They found the majority of patients with melanocytic lesions in the age group 21-40 years and 16-45 years respectively.

In the current study, the benign nevi lesions were 68 (81.9%) while malignant consists of 15(18.1%) patients.

Similar findings were reported by Laishramet all [13] that out of the 183 cases, 158 (86.3%) were benign and 25 (13.7%) were malignant.

We found that the site of lesions were predominant of skin with 65 (78.3%) followed by conjunctiva 18 (21.7%). The commonest site of distribution of nevi was the face (32.5%) followed by lower limbs and skin (NOS) for each one (16.9%). Laishram et al (13) reported that the commonest site of the lesions was the face with (51.4%) cases followed by the upper limbs with (14.2%) cases and lower limbs with (10.9%) cases. A published study by Suvernakar et al [24] mentioned that the site distribution of lesions were located on the head and neck region (63.6%), followed by lower extremity (22.7%) and trunk (13.6%).

In the current study, the histological types of nevi lesions were junctional nevi (22.9%) followed by intra-dermal nevi (21.7%). Our result does not consistent with studies reported by Suvernakar et al [24] and Pailoor et al [19]. They found that the most common melanocytic nevi was intradermal followed by compound

nevus (58.3%, 33.3%) , (66% , 21%) respectively. These differences may be due to the small size of our studied sample.

Out of 83 cases with nevi we found 15 (18.1%) patients with malignant melanoma. They were 10 (66.7%) males and 5 (33.3%) females, all the cases in the age range ≥ 50 years and the site of melanoma were 12 (80%) on lower limb (foot), ano-genital region 2 (13.3%) and only 1 (6.7%) conjunctival melanoma.

In one of the largest reviews of cancer cases treated in the Kingdom at King Faisal Specialist Hospital and Research Center (KFSH) at Riyadh, malignant melanoma was found to be a rare disease in Saudi Arabia representing 0.6% in frequency in the registry for cases referred from all geographical regions. This low frequency could be linked to social and cultural practices e.g. conservative dressing [2].

In the review and experience of KFSH on malignant melanoma from 1975-1982, it was noted that out of 22 patients, 11 had their lesion on the foot [26].

In both hospital and population-based study of cancer in the Eastern Region, no specific mention was made of malignant melanoma [3,20]. A report from the Gizan province over a period of 11 years, recorded only 2 patients with malignant melanoma though other skin cancers were common [21]. In Iraq only 16 cases of malignant melanoma were reported within 6 years [11].A high incidence of malignant melanoma was also reported in a study from Sudan where it represented 3% of all cancer cases, the majority of which were lower limbs particularly the sole of foot and acral distribution

[28]. The same observation was noted in a study from Nigeria (10). Conjunctival melanoma is rare and accounts for only 2% to 3% of ocular cancer, about 1% of non-cutaneous malignant melanoma [7,14,23]. The incidence, which is increasing, is about 0.24 to 0.8 per million per year in the white population and is epidemiologically associated with ultraviolet light exposure [14,15]. Conjunctival melanomas are more common in older individuals, with the mean age at presentation of 50 to 60 years [9,27]. In our study, we found 13 (86.6%) cases in the Clark stage II. Our findings were unlike the

findings reported by others [8,16,24], that may be due to the small sample in our study.

Conclusion:

Our findings demonstrate that the frequency of skin & conjunctival nevi, melanoma, and the histopathologic main features in Adenis similar to other studies with predominant of benign lesions and skin site and less common in conjunctiva. Number of cases found as malignant melanoma and all the cases in the age range 50 years and more and the majority of melanoma were on foot. Further studies malignant melanoma is recommended.

References:

- 1- Ackerman AB, Cerroni L, Kerl H. (1994). Pitfalls in Histopathologic Diagnosis of Malignant Melanoma. Philadelphia: Lea &Febiger.pp: 536-539
- 2- Adnan E, Madras R, Ofelia TE, Dolores M, Shouki B. (1996). Frequency and distribution of 22836 adult cancer cases referred to KFSH & RC. *Annals of Saudi Medicine*.16(2):152-8.
- 3- Al-Tamimi TM, Ibrahim EM, Ibrahim AW, et al. (1997). Cancer in the Eastern Region of Saudi Arabia: a population based study (1987-1988) *Annals of Saudi Medicine*.17(1):53-65.
- 4- Elder DE, Elenitsas R, Murphy GF, Xu X. Philadelphia, (PA): Lippincott Williams and Wilkins; 2005. Benign pigmented lesions and malignant melanoma. In: *Lever's Histopathology of the skin*; pp. 715-803
- 5- Elder DE, Elenitsas R, Murphy GF, XU X. (2009). Benign Pigmented Lesions and Malignant Melanoma. In *Lever's Histopathology of the Skin*; 10th ed. Lippincott Williams and Wilkins; p: 699-790.
- 6- Folberg R, Jacobiec FA, Bernardino VB, Iwamoto T. (1989). Benign conjunctival melanocytic lesions: clinicopathologic features. *Ophthalmol*. 96:436-461
- 7- Grin JM, Grant-Kels JM, Grin CM, Berke A, Kels BD. (1998). Ocular melanomas and melanocytic lesions of the eye [comment in *J Am AcadDermatol*. 2000;42(1,pt 1):145]. *J Am AcadDermatol*. 38(5, pt 1):716-730.
- 8- Hussein MR, Elasers DA, Fadel SA, Omar AE. (2006).Clinicopathological features of melanocytic skin lesions in Egypt. *Eur. J Cancer Prev*. 15(1):64-68.
- 9- Inskip PD, Devesa SS, Fraumeni JF Jr. (2003). Trends in the incidence of ocular melanoma in the United States, 1974-1998. *Cancer Causes Control*. 14(3):251-257.
- 10- Ketiku KK, Foregeneao AO. (1989). The Incidence and Management of Skin Cancer in Nigeria. *African J Derm*.2:108-9.
- 11- Khalifa E. Sharquie, Adil A. Noaim, Wesal K. Al-Janabi. (2014).The Status of Malignant Melanoma in Iraqi Patients. *American Journal of Dermatology and Venereology*. 3(3): 63-67
- 12- Kurli M, Finger PT. (2005). Melanocytic conjunctivaltumors.*OphthalmolClin North Am*. 18:15-24
- 13- Laishram RS, Myrthong BG, Laishram S, Shimray R, Kumar AK, Sharma DC. (2013). Pigmented skin lesions: are they all of melanocytic origin? A histopathological perspective.*Journal of Pakistan Association of Dermatologists*.23 (3):284-288.
- 14- Lommatzsch PK, Lommatzsch RE, Kirsch I, Fuhrmann P. (1990). Therapeutic outcome of patients suffering from malignant melanomas of the conjunctiva. *Br J Ophthalmol*. 74(10):615-619.
- 15- Missotten GS, Keijser S, de Keizer RJ, et al. (2005).Conjunctival melanoma in the Netherlands: a nationwide study. *Invest Ophthalmol Vis Sci*. 46(1):75-82.
- 16- Mukhopadhyay S, Ghosh S, Siddharta D, Mitra P. (2008). A clinicopathological study of malignant melanoma with special reference to atypical presentation.*IJPM*. 51(4):485-488.
- 17- Nevus (mole). Last Updated October 4, 2010. Available from: http://www.thedoctorsdoctor.com/diseases/nevus_melanocytic.htm
- 18- Oakley A. Moles. *DermNet New Zealand*. 1997.Available from: <http://www.dermnetnz.org/lesions/moles.html>
- 19- Pailoor K, Marla NJ, Pai MR, Fernandes H, Graham S, Jayaprakash CS, Murali K. (2013).Histopathological Spectrum of Benign Melanocytic Nevi and Melanoma: A Study in a Tertiary Care Centre in Coastal Karnataka. *Indian Journal of Forensic Medicine and Pathology*.6(2): 65-69
- 20- Perrine RP, Jumma A. (1975). Changing trends in cancer in Saudi Arabs. *ARMCO Medical Service Organization Epidemiology Bulletin*. 1-4.
- 21- Pradeep T, Ved P, Pathak, Akhtar Z, et al. (1995).Cancer in the Gizan Province of Saudi Arabia 11 years Study. *Annals of Saudi Med*. 5(1):14-20.
- 22- Schafer T, Merkl J, Klemm E et al. (2006). The epidemiology of nevi and signs of skin aging in the adult general population: Results of the KORA-Survey 2000. *J Invest Dermatol*. 126:1490-6.
- 23- Shields CL, Demirci H, Karatza E, Shields JA.(2004). Clinical survey of 1643 melanocytic and nonmelanocyticconjunctival tumors.*Ophthalmology*. 111(9):1747-1754.
- 24- Suvernakar SV, Shweta R Harwani, Deshpande SA.(2014).Clinicopathological Study of Pigmented Skin Lesions.*IOSR Journal of Dental and Medical Sciences (IOSR-JDMS)*. 13(5): 70-73

-
- 25- Suzaki R, Ishizaki S, Iyatomi H, Tanaka M. (2014). Age-related prevalence of dermoscopic patterns of acral melanocytic nevi. *DermatolPract Concept*.4(1): 53-57
- 26- Tariq M, William AR. M.M0. (1982).Of the skin review and the KFSHexperience. *KFSH Med Journal*. 2(3):167–74.
- 27- Tuomaala S, Kivela` T. (2003).Conjunctival melanoma: is it increasing in the United States? *Am J Ophthalmol*. 136(6):1189–1190.
- 28- Yagi K, Mukhtar BI, Malik MO. (1977).A Study on Malignant Melanoma in the Sudan. *SMJ*. 15(2):29–35.

الشامة الجلدية الحميدة وشامة الملتحمة مقابل الملائوم الخبيث: دراسة إكلينيكية

باثولوجية ل 83 حالة في عدن

مازن عبود بن ثابت

صالح سلمان باصالح

الملخص

استهدفت الدراسة توفير معلومات أساسية عن الشامات الجلدية والملتحمة والملائوم في عدن. كانت دراسة استرجاعية لسجلات المرضى وتم تحليل البيانات من خلال الإحصاء الوصفي. عدد المرضى 83 الذين شملتهم الدراسة كانوا 32 (38.6%) من الذكور و 51 (61.4%) من الإناث. تتراوح أعمار المرضى بين 3 إلى 70 سنة. أغلبية المرضى 30 (36.2%) كانوا ذوي الأعمار بين 20 – 39 سنة. كانت آفات الشامات الحميدة 68 (81.9%)، في حين تتكون الملائوم الخبيث من 15 (18.1%) من المرضى. مواقع الآفات كانت سائدة في الجلد 65 (78.3%)، يليه الملتحمة 18 (21.7%). وكانت آفات الشامات على الوجه 27 (32.5%)، تليها الأطراف السفلى والجلد. أنواع النسيجية من آفات الشامات، شامات التحامية 19 (22.9%)، يليه شامات داخل الأدمة 18 (21.7%). وكانت هناك 15 حالة من الملائوم الخبيث. كانوا 10 (66.7%) من الذكور و 5 (33.3%) من الإناث، كل الحالات في الفئة العمرية ≤ 50 سنة وكان معظم مواقع الملائوم الخبيث على الأطراف السفلى (القدم) 12 (80%). كانوا 11 (73.3%) تقرحي و 4 (26.7%) ورمي. وجدنا فقط 1 (6.7%) في العقد للمفاوية و 13 (86.6%) في مرحلة كلارك الثاني. خلصنا إلى أن الدراسة قد وصفت المشكلة من شامة الجلد وشامة الملتحمة. وهناك حاجة إلى المزيد من الدراسات في هذا الجانب.

الكلمات المفتاحية: معلومات ، الجلد ، الملتحمة ، الشامات ، الملائوم ، عدن