

10-10-2019

## Influence of the vertical position of maxillary lateral incisors on the perception of smile esthetics among dentists, orthodontists and laypersons: A computerized simulated photographic assessment

Rita DAOU

Roula AKL

Joseph GHOURIL

Elie KHOURY

Follow this and additional works at: <https://digitalcommons.aaru.edu.jo/iajd>

---

### Recommended Citation

DAOU, Rita; AKL, Roula; GHOURIL, Joseph; and KHOURY, Elie (2019) "Influence of the vertical position of maxillary lateral incisors on the perception of smile esthetics among dentists, orthodontists and laypersons: A computerized simulated photographic assessment," *International Arab Journal of Dentistry*. Vol. 10: Iss. 1, Article 2.

Available at: <https://digitalcommons.aaru.edu.jo/iajd/vol10/iss1/2>

This Original Article is brought to you for free and open access by Arab Journals Platform. It has been accepted for inclusion in International Arab Journal of Dentistry by an authorized editor. The journal is hosted on [Digital Commons](#), an Elsevier platform. For more information, please contact [rakan@aarj.edu.jo](mailto:rakan@aarj.edu.jo), [marah@aarj.edu.jo](mailto:marah@aarj.edu.jo), [u.murad@aarj.edu.jo](mailto:u.murad@aarj.edu.jo).

# INFLUENCE OF THE VERTICAL POSITION OF MAXILLARY LATERAL INCISORS ON THE PERCEPTION OF SMILE ESTHETICS AMONG DENTISTS, ORTHODONTISTS AND LAYPERSONS: A COMPUTERIZED SIMULATED PHOTOGRAPHIC ASSESSMENT

Rita Daou\* | Roula Akl\*\* | Joseph Ghoubril\*\*\* | Elie Khoury\*\*\*\*

## Abstract

The aim of this study was to evaluate the impact of the vertical position of the maxillary lateral incisors borders on the perception of smile esthetics of a woman and a man, with respect to the resulting changes of the gingival margin. Pictures of two smiles of different sexes were edited using Adobe Photoshop (Version CS5; Adobe Systems, San Jose, Calif). The vertical position of the lateral incisors was modified, while keeping the same crown length and height / width ratio, thus respecting the resulting changes of the gingival levels. 210 evaluators (70 dentists, 70 orthodontists and 70 laypersons) aged between 18 and 60 years old were asked to grade the pictures with a scale from 0 to 10, with zero as the most unattractive and 10 as the most attractive. Orthodontists are the most sensitive to changes in the level of the maxillary lateral incisors. The most attractive vertical relationship between the lateral and the central incisors was the 1.0 mm step. The laypersons were not able to find any statistical difference between the lateral incisors levels for both sexes.

**Keywords:** Esthetics - lateral incisors - vertical position - computerized simulation - photographic assessment

IAJD 2019;10(1):19-24.

# INFLUENCE DE LA POSITION VERTICALE DE INCISIVES LATÉRALES MAXILLAIRES SUR LA PERCEPTION DE L'ESTHÉTIQUE DU SOURIRE CHEZ LES DENTISTES, LES ORTHODONTISTES ET LES NON-SPÉCIALISTES: UNE EVALUATION PHOTOGRAPHIQUE SIMULÉE

## Résumé

L'objectif de cette étude était d'évaluer l'impact de la position verticale des bords libres des incisives latérales maxillaires sur la perception esthétique du sourire d'une femme et celui d'un homme, en respectant les changements résultant sur le niveau gingival. Les photos de deux sourires de différents sexes ont subi des changements en utilisant le programme Adobe Photoshop (Version CSS ; Adobe Systems, San Jose, Calif). La position verticale des incisives latérales a été modifiée tout en gardant la même hauteur coronaire et le même rapport hauteur/largeur. 210 évaluateurs (70 dentistes, 70 orthodontistes et 70 profanes) âgés entre 18 et 60 ans ont attribué aux photos modifiées un score entre 0 et 10, zéro pour le sourire le moins beau, et 10 au sourire le plus beau. 180 évaluateurs ont répondu à l'enquête. Les orthodontistes sont les plus sensibles aux changements du niveau des bords des incisives latérales. Selon cette étude, le plus esthétique est d'avoir des latérales maxillaires à 1 mm par rapport aux centrales, en respectant les changements du niveau gingival. Les profanes ont été incapables de trouver une différence significative entre les différents niveaux des bords libres des incisives latérales dans les 2 sexes.

**Mots-clés :** esthétique - incisives latérales - position verticale - simulation informatisée - évaluation photographique.

IAJD 2019;10(1):19-24.

\* DDS, Post graduate student,  
Dpt of Orthodontics,  
Faculty of Dental Medicine, Saint-Joseph University, Beirut,  
Lebanon

\*\*\* DDS, DESO, PhD, Associate Professor,  
Dpt of Orthodontics,  
Faculty of Dental Medicine, Saint-Joseph University, Beirut,  
Lebanon

\*\* DDS, DESO, Senior lecturer,  
Dpt of Orthodontics,  
Faculty of Dental Medicine, Saint-Joseph University, Beirut,  
Lebanon

\*\*\*\* DDS, DESO, MSc, PhD,  
Assistant Professor,  
Head of Dpt of Orthodontics,  
Faculty of Dental Medicine, Saint-Joseph University, Beirut,  
Lebanon  
elie.khoury@usj.edu.lb

## Introduction

Function, esthetics and stability are the main goals of any orthodontic treatment. The smile is an important component of the facial esthetics and its attractiveness is tied to subjectivity and hard to measure [1]. For many years, clinical guidelines were based on authors' opinions rather than scientific evidence [2]. In order to achieve optimal smile esthetics, the orthodontist should follow evidence based guidelines [3] to create attractive smiles [4].

Recently, the vertical positions of the maxillary central and lateral incisors have been of great interest in the literature. The vertical position of the edges of the maxillary incisors defines the smile line, ideally parallel to the lower lip contour [5, 6]. On the other hand, a flattened or inverted line makes the smile less attractive [2-4, 6, 7].

The vertical relationship between the central and lateral incisors edges is a major criterion to be considered in the treatment plan, as well as in bonding and in finishing [8]. Machado et al. evaluated the esthetics of the smile by changing the vertical position of the maxillary central incisor while respecting the changes in the gingival margin [7, 8]. The outcomes of Machado's study demonstrate that the gingival margins have minimal impact on the perception of smile esthetics, whereas the incisal edge relationship plays an important role in the analysis of smile esthetics. Also this study gave the highest rate to smiles with a 1.5 mm step between the central and the lateral incisors, and the lowest rate to the smile with no step between the centrals and the laterals [7]. King et al. changed the levels of the lateral incisors borders and kept the central incisors fixed, neglecting the resulting changes in the gingival margin [9]. The study of King revealed no significant difference ( $p>0.05$ ) in the mean preferences of the 3 groups. The judges in this study preferred the lateral incisors being 0.6 mm above incisal plane formed by the

centrals' borders. Orthodontists and general dentists had a smaller range of acceptability than laypeople. The level of the lateral incisors was considered acceptable if it was between 0.3 mm and 1.0 mm above the incisal plane [9].

In another matter, the esthetics concepts of the orthodontist do not always coincide with those of patients or referring dentists, yet some studies find no significant differences [10]. For this reason, it is important to know the most accepted position of the lateral incisors, among orthodontists, dentists and laypeople with a survey that will serve as a reference.

The aim of this study was to evaluate the impact of the vertical position of the maxillary lateral incisors borders on the perception of smile esthetics of a woman and a man, with respect to the resulting changes of the gingival margin, among orthodontists, dentists and laypersons.

## Material and methods

The photographs of the smile of a man and a woman were taken with a Digital Single-Lens Reflex (DSLR) camera (Canon 700D), a macro 100 mm lens and Canon ring flash (30-2, Shimomaru 3-chome, Ohta-ku, Tokyo 146-8501, Japan). The 2 volunteers signed an informed consent for the use of their smile photos for a scientific research at the department of orthodontics of Saint Joseph University of Beirut.

The 2 representative smiles were selected because they had well aligned teeth after orthodontic treatment and they were showing the gingival contours of the maxillary teeth.

Each picture had one side digitally edited with Adobe Photoshop (version CS5; Adobe Systems, San Jose, California) and then was mirrored to form a complete symmetric smile. The real crowns of the lateral incisors of each patient (the man and the woman) were measured with a caliper in order to be able to calibrate the vertical movements on the photos with respect to the scale. Changes were made to the

vertical position of the lateral incisor, varying its crown edge from 0.0 to 2.0 mm in 0.5 mm steps compared to the corresponding central incisor edge. The vertical position of the lateral incisors was modified, while keeping the same crown length and height/width ratio, thus respecting the resulting changes of the gingival levels. The central incisor was kept untouched.

All manipulations were made by the same operator (R.D.) and resulted in 12 images, 6 for each sex. The first modification is a 0 mm step between the central and the lateral incisors (the central and lateral incisors borders being on the same level), followed by 0.5mm, 1.0 mm, 1.5mm, 2.0 mm steps. Finally, the 1.0 mm step picture was repeated twice for the intra-class correlation coefficient (Fig.1 and 2)

The sample size of the evaluators was calculated with G\*Power software (version 3.1.9.2; Heinrich Heine Universität Düsseldorf, Germany), considering an alpha error of 0.01, an 80% power, and 0.25 effect size.

210 evaluators were asked to judge the pictures. They were divided into 3 subgroups of 70 each: orthodontists, dentists and laypeople. This number was similar to the sample size of other comparable studies [2, 7, 8].

All evaluators were between 18 and 60 years of age. The laypeople group was randomly selected among participants having a complete or incomplete college degree, not related to dentistry. The dentists have a minimum of 2 years of experience. The orthodontists group included specialists who have been working with fixed appliances for more than 12 months.

A Google form was sent by e-mail to the participants. Starting with the smiles of the woman, the 6 pictures were shown, and the evaluator was asked to contemplate them for 2 minutes. After that, the same 6 pictures were shown, one by one, in random order. A scale from 0 to 10 was used to judge the smile attractiveness for each picture separately, with zero as the least attractive and 10 as the

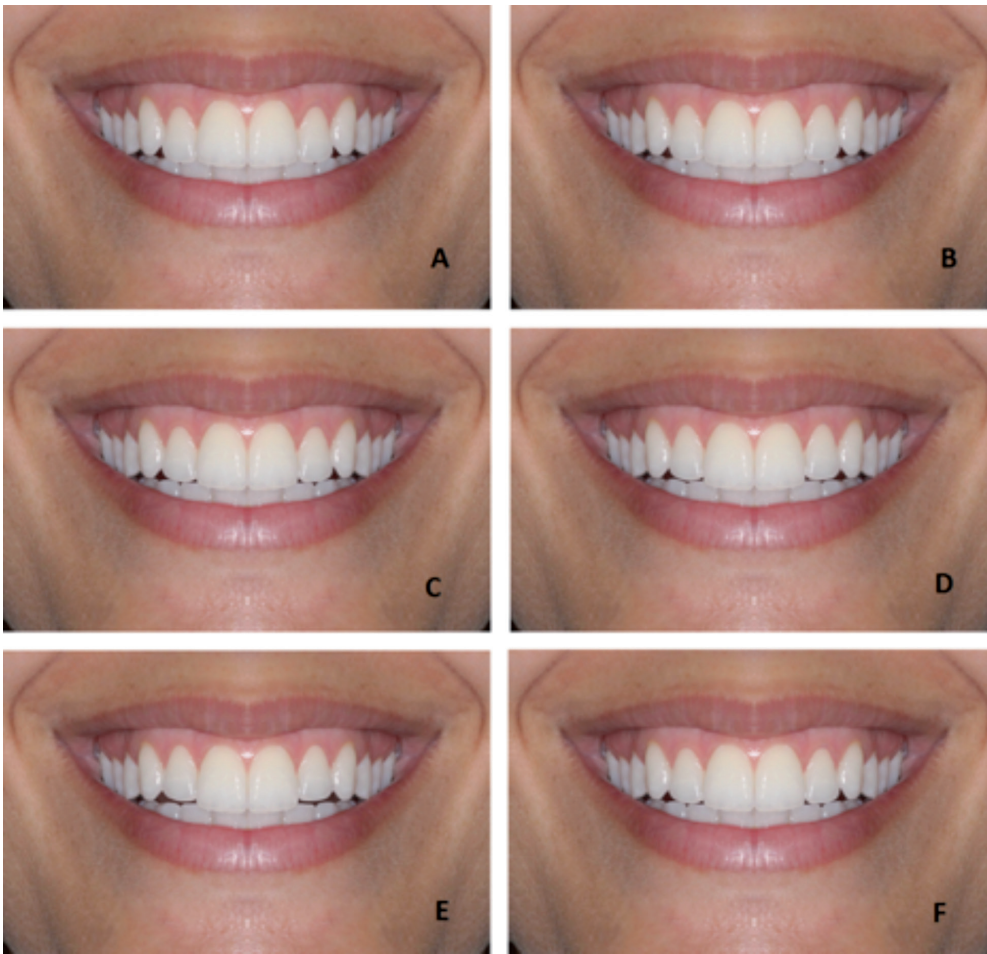

Fig. 1: Woman smile. A: 0 mm step between the upper lateral incisors and the upper central incisors (central incisors being fixed); B: 0.5 mm step; C: 1.0 mm step; D: 1.5 mm step; E: 2.0 mm step; F: repeated picture for the 1.0 mm step.

most attractive. The evaluators were not informed of the modified criterion in each picture.

### Statistical analysis

Multiple comparisons were made to compare the scores for each picture between the 3 groups of evaluators using the ANOVA and the Scheffe's post-hoc test, and to compare the scores of different incisors levels in each group and for each sex. The level of significance was set for  $p < 0.05$ .

Data from repeated measurements was used to calculate the ICC (intra-class correlation) for each group. All statistical analysis were performed using the software package (SPSS for windows, version 23.0, Chicago, USA).

### Results

180 (60 orthodontists, 60 dentists, 60 laypeople) of 210 evaluators responded to the survey, 49.5% women and 50.5% men (Table I). The descriptive statistics for each picture are shown in Figures 3 and 4. Thirty people did not respond to the message we sent, probably they did not check their electronic mail inbox.

For the orthodontists group, the highest grade was attributed to the smile with the 1.0 mm step for both the woman ( $p=0.04$ ) and the man ( $p=0.01$ ) smiles, with no significant difference with the 0.5 mm and 1.5 mm steps. For the woman smile, orthodontists gave significantly lower scores to the 0 mm ( $p=0.003$ ) and 2 mm ( $p=0.009$ ) steps. For the man smile, they gave a signi-

ficantly lower score to the 2 mm step ( $p=0.001$ ).

Dentists gave the highest score to the 0.5 mm step in the woman's smile, with no statistical differences detected between the other levels scores. However, for the man smile, the highest ranked picture was the 1.0 mm step with no statistical difference with the other groups, except for the 2mm step that was attributed to lowest score ( $p=0.02$ ).

The laypersons were not able to find any statistical difference between the lateral incisors levels for both sexes. Particularly, this group gave a significantly higher score to the 0 mm step in comparison with the scores given by the orthodontists and dentists to the same picture.

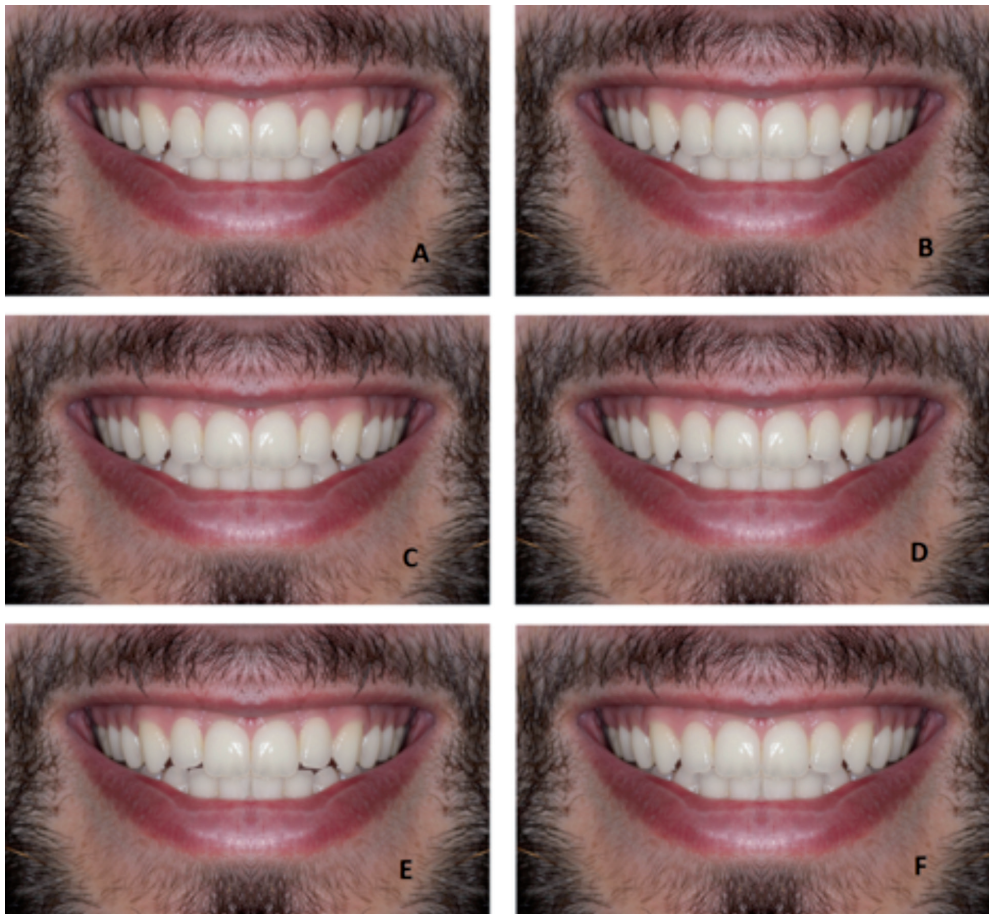

Fig. 2: Man smile. A: 0 mm step between the upper lateral incisors and the upper central incisors (central incisors being fixed); B: 0.5 mm step; C: 1.0 mm step; D: 1.5 mm step; E: 2.0 mm step; F: repeated picture for the 1.0 mm step.

As for the comparison between the results of women and men (all groups combined) not statistically significant difference was detected.

The intra-class correlation (ICC) was calculated using the second measurements recorded with the repeated picture of 1.0 step for both sexes. Correlation was significant for the 3 groups of evaluators demonstrating a good reproducibility of scores. For the dentists the ICC for the woman smile was 0.607 ( $p=0.0001$ ) and for the man smile was 0.761 ( $p=0.0001$ ); for the orthodontists the ICC for the woman smile was 0.613 ( $p=0.0001$ ) and for the man smile was 0.811 ( $p=0.0001$ ), finally the lay persons had an ICC of 0.555 for the women smile ( $p=0.0001$ ) and an ICC of 0.745 for the man smile ( $p=0.0001$ ).

## Discussion

In this study, we decided to evaluate the impact of different levels of lateral incisors borders on smile attractiveness for both sexes, because smile characteristics might differ according to the sex, age and personality [11]. Some studies have shown that the esthetic impact of smile visualization is greater in a dental view compared with a full facial view [12, 13], therefore, photographs of smiles were taken without the whole face in order to increase the focus on dental alterations and reduce the distraction of other factors [3].

The VAS (Visual Analogue Scale) was used to grade the smile attractiveness. It is a reliable scoring method used in epidemiologic and clinical research to measure the intensity of

various symptoms such as pain [14]. However, raters tend not to use the whole scale; they try to grade each picture around central values in case the next one was better. For this reason, we first showed all the 6 pictures together for each sex so that the evaluators can have a better idea about the more or less attractive smile.

According to this survey, orthodontists are the most sensitive to changes in the level of the maxillary lateral incisors, most probably because they are better trained to observe this particular characteristic. This confirms the results of the study made by Machado R.M and collaborators [8]. Orthodontists preferred the 1mm step for both sexes, even though no statistically significant difference was detected between the 0.5 mm, 1.0 mm and 1.5 mm steps. The least attractive smiles for this group

were the extremes (0 mm and 2.0 mm steps) for women, and 2 mm step for men: we can conclude that the flat smile lines are more accepted for men than women [3, 15].

For the man smile, dentists gave the highest score to the 1.0 mm and the lowest score to the 2.0 mm step.

The laypeople are not able to notice a significant difference between the different levels of the lateral incisors. However, the 0 mm step for both the woman and the man is more accepted by this group than by the specialists in dentistry, which means they prefer lateral incisors borders at the same level of the central incisors. This was also found by the study of Stolz et al. [16]. This result is particularly interesting and could explain the tendency of patients to prefer well-aligned teeth, all at the same level.

The ICC shows a good reproducibility of scores for the 3 groups of evaluators, which means that each evaluator was able to give statistically the same grade to the repeated picture.

## Conclusion

- Orthodontists were the most qualified group to identify differences between the smiles.
- The most attractive vertical relationship between the lateral and the central incisors was the 1.0 mm step, according to the orthodontists.
- Flat smiles with central and lateral incisors borders at the same level are more appreciated by laypeople.
- The perception of smile esthetics was identical between men and women.
- Flat smiles are more accepted for men, whereas convex smile lines fit better for women.

Group	n	SEX		AGE (years)		
		Male	Female	Mean	Minimum	Maximum
Orthodontists	60	33	27	43.8	25	60
Dentists	60	24	36	37.9	25	58
Laypersons	60	32	28	35.5	21	56
Total	180	89	91			

Table 1: Demographic distribution of the evaluators by sex and age.

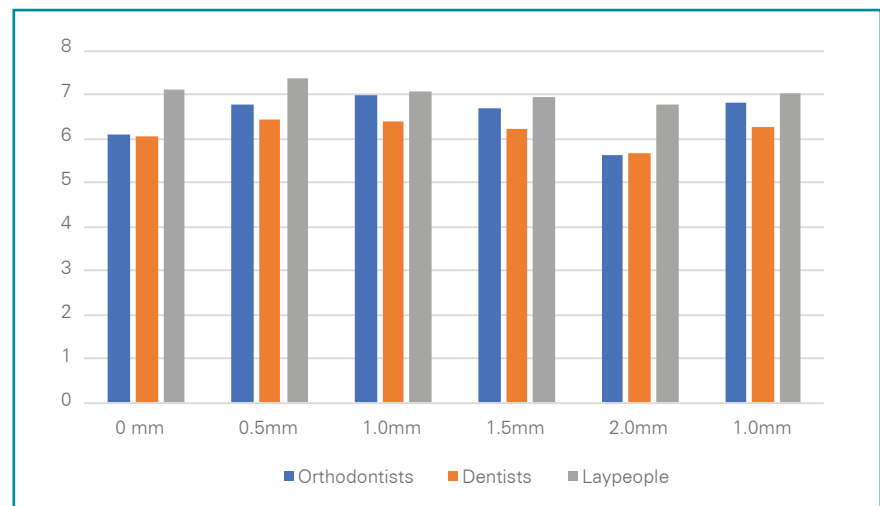


Fig. 3: Mean scores for the woman smile according to the 3 groups of evaluators.

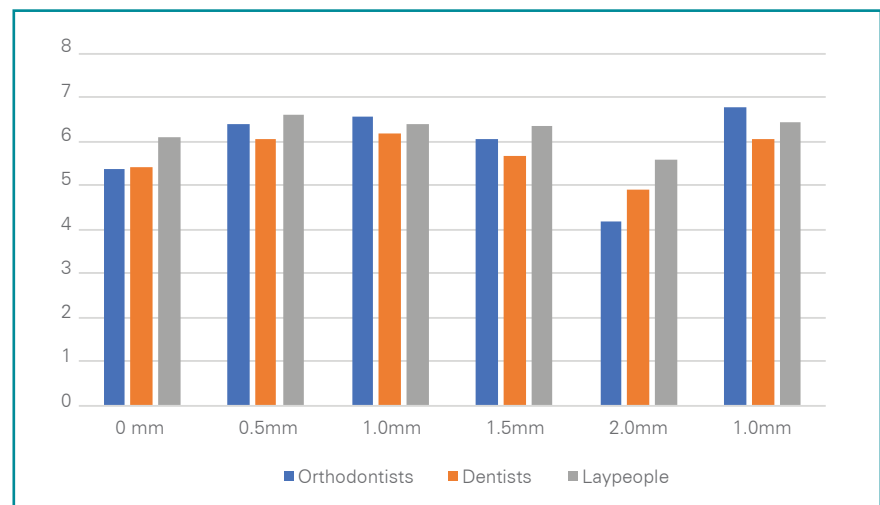


Fig. 4: Mean scores for the man smile according to the 3 groups of evaluators.

## References

1. McLeod C, Fields HW, Hechter F, Wiltshire W, Rody W, Christensen J. Esthetics and smile characteristics evaluated by laypersons. *Angle Orthod* 2011;81:198–205.
2. Machado AW. 10 commandments of smile esthetics. *Dental Press J Orthod* 2014;19:136–157.
3. Kaya B, Uyar R. Influence on smile attractiveness of the smile arc in conjunction with gingival display. *Am J Orthod Dentofacial Orthop* 2013;144:541–547.
4. Rodrigues C de DT, Magnani R, Machado MSC, Oliveira OB. The perception of smile attractiveness. *Angle Orthod* 2009;79:634–639.
5. Foulger TE, Tredwin CJ, Gill DS, Moles DR. The influence of varying maxillary incisal edge embrasure space and interproximal contact area dimensions on perceived smile esthetics. *Br Dent J* 2010;209, E4.
6. Sarver DM. The importance of incisor positioning in the esthetic smile: the smile arc. *Am J Orthod Dentofacial Orthop* 2001;120:98–111.
7. Machado AW, McComb RW, Moon W, Gandini LG. Influence of the vertical position of maxillary central incisors on the perception of smile esthetics among orthodontists and laypersons. *J Esthet Restor Dent* 2013;25:392–401.
8. Machado RM, Assad Duarte, ME, Jardim da Motta AF, Mucha JN, Motta AT. Variations between maxillary central and lateral incisal edges and smile attractiveness. *Am J Orthod Dentofacial Orthop* 2016;150:425–435.
9. King KL, Evans CA, Viana G, BeGole E, Obrez A. Preferences for vertical position of the maxillary lateral incisors. *World J Orthod* 2008;9:147–154.
10. Krishnan V, Daniel ST, Lazar D, Asok A. Characterization of posed smile by using visual analog scale, smile arc, buccal corridor measures, and modified smile index. *Am J Orthod Dentofacial Orthop* 2008;133:515–523.
11. Bhuvaneshwaran M. Principles of smile design. *J Conserv Dent* 2010;13: 225–232.
12. Flores-Mir C, Silva E, Barriga MI, Lagravere MO, Major PW. Lay person's perception of smile esthetics in dental and facial views. *J Orthod* 2004;31, 204–209.
13. Witt M, Flores-Mir C. Laypeople's preferences regarding frontal dentofacial esthetics:  
14. attractiveness for epidemiologic use. *Am J Orthod* 1985;88:402–408.
15. Zachrisson BU. Esthetic Factors Involved in Anterior Tooth Display and the Smile: Vertical Dimension. *JCO* 1998;1:303–443.
16. Stolz S, Lefebvre F, Bolender Y, Kanter D. Perception esthétique de la position verticale des bords libres des incisives latérales maxillaires dans l'arc du sourire. *Orthod Fr* 2017;88:251–261.