

10-10-2019

Comparing clinical and radiographic periodontal parameters to software generated CBCT measurements

Rachid SREIH

Nabil GHOSN

Carole CHAKAR

Nadim MOKBEL

Nada BOU ABOUD NAAMAN

Follow this and additional works at: <https://digitalcommons.aaru.edu.jo/iajd>

Recommended Citation

SREIH, Rachid; GHOSN, Nabil; CHAKAR, Carole; MOKBEL, Nadim; and BOU ABOUD NAAMAN, Nada (2019) "Comparing clinical and radiographic periodontal parameters to software generated CBCT measurements," *International Arab Journal of Dentistry*. Vol. 10: Iss. 1, Article 4. Available at: <https://digitalcommons.aaru.edu.jo/iajd/vol10/iss1/4>

This Original Article is brought to you for free and open access by Arab Journals Platform. It has been accepted for inclusion in International Arab Journal of Dentistry by an authorized editor. The journal is hosted on [Digital Commons](#), an Elsevier platform. For more information, please contact rakan@aar.edu.jo, marah@aar.edu.jo, u.murad@aar.edu.jo.

COMPARING CLINICAL AND RADIOGRAPHIC PERIODONTAL PARAMETERS TO SOFTWARE GENERATED CBCT MEASUREMENTS

Rachid Sreih* | Nabil Ghosn** | Carole Chakar*** | Nadim Mokbel**** | Nada Bou Abboud Naaman*****

Abstract

The aim of this study was to compare direct surgical measurements to data extracted from periapical radiographs and CBCT by means of software (coPeriodontix™ and Blue Sky Plan®) in order to assess the accuracy delivered by these 2 software. Ten patients were included in the study, and the number of teeth selected for measurements ranged from one to 10 per patient. All CBCT scans and X-rays were acquired within a maximum period of 1 month prior to surgery. Clinical linear measurements were performed at 6 sites for each tooth. Furcation defects were recorded according to the Hamp classification. Differences between data acquired from these 3 modalities were analyzed. Linear measurements showed statistically significant difference, where CBCT showed the least bone loss, periapical radiographs showed more bone loss, while direct surgical measurements showed the most bone loss. The Blue Sky Plan® that measured the furcation involvement accurately depicted the true furcation defect.

Keywords: Diagnostic-periodontitis, dental radiography, cone beam computed tomography, coPeriodontix™ software.

IAJD 2019;10(1):9-22.

COMPARAISON DE PARAMÈTRES PARODONTAUX CLINIQUES ET RADIOGRAPHIQUES AVEC DES MESURES DE CBCT GÉNÉRÉES PAR UN LOGICIEL

Résumé

Le but de cette étude était de comparer les données provenant de mesures intra-chirurgicales, de radiographies rétro-alvéolaires et celles obtenues à partir de tels logiciels (coPeriodontix™ et Blue Sky Plan®) afin d'évaluer leur précision. 10 patients ont été inclus dans l'étude, avec une sélection de 1 à 10 dents par patient pour la prise des mesures, et répartis en 3 groupes. Tous les CBCT et les rétro-alvéolaires ont été pris 1 mois maximum avant la chirurgie. Les mesures linéaires cliniques de la jonction amélo-cémentaire au niveau osseux marginal ont été faites au niveau de six sites pour chaque dent incluse dans l'étude. Les atteintes furcatoires ont été évaluées selon la classification de Hamp. Les résultats ont montré une différence statistiquement significative entre ces trois modalités. Les mesures obtenues par CBCT ont montré le moins de pertes osseuses, suivies par les radiographies qui ont montré des pertes plus prononcées, les mesures intra-chirurgicales ont montré des valeurs plus importantes.

Le coPeriodontix™ en mesurant le niveau osseux tend à sous-estimer la perte osseuse et le Blue Sky Plan® a montré avec précision les atteintes furcatoires.

Mots-clés : diagnostic-parodontite, radiographie intraorale, tomодensitométrie à faisceau conique, coPeriodontix™.

IAJD 2019;10(1):9-22.

* DDS, Resident, Masters in periodontology, Dpt of Periodontology
Faculty of Dental Medicine, Saint-Joseph University, Beirut
rachidsreih@gmail.com

*** DDS, MSc, PhD, Head of Dpt of Periodontology
Faculty of Dental Medicine, Saint-Joseph University, Beirut

***** DDS, DUSCP, PhD, Honorary Dean, Professor at the
Department of Periodontology
Faculty of Dental Medicine, Saint-Joseph University, Beirut

** DDS, MScD, Instructor, Dpt of Oral and Maxillo-facial
Radiology
Faculty of Dental Medicine, Saint-Joseph University, Beirut

**** DDS, MSc, PhD, Post graduate director, Dpt of
Periodontology
Faculty of Dental Medicine, Saint-Joseph University, Beirut

Introduction

Diagnosis in periodontology relies on clinical and radiographic assessments. Clinical assessment of the periodontium includes probing pocket depth (PPD), bleeding on probing (BOP), clinical attachment loss (CAL), tooth mobility and furcation involvement while radiographic examination relies on panoramic (OPT) and full mouth intra-oral X-rays [1]. These conventional examination methods have some disadvantages. The periodontal probe is unable to assess bone position without an open flap [2]. Nabers probe has a limited access to the furcation area: the site of the furcation area is generally covered with gingival tissues allowing limited physical access to the depths of the furcation, with morphological variations and measurement errors inherent to tooth position, inclination, presence of adjacent teeth, and variability in operator technique with an estimated clinical probing accuracy of 56% [3]. The image produced by a conventional periapical radiograph (PA) is a two-dimensional (2D) representation of a three-dimensional (3D) area of interest makes diagnosis of missing buccal or lingual plates impossible [4]. While the diagnosis of intra-bony defects is detectable in only 67% of the cases [5], only 38.7 % of furcation defects are accurately diagnosed [6]. OPT hinders the same limitations as intra-oral radiographs in addition to the distortion of images and blurring of anatomical structures [7].

Today, Cone Beam Computed Tomography (CBCT) is widely used in many fields of dentistry due to scan time reduction, less radiation exposure, reduced cost for the patient, and a high image quality when compared to Dentascan [8]. Recently, the American Academy of Periodontology underlined the importance of continued research on CBCT. The widespread and the quick advancement in this field could be a useful tool of diagnosis and treatment planning in patients with compromised periodontium [9].

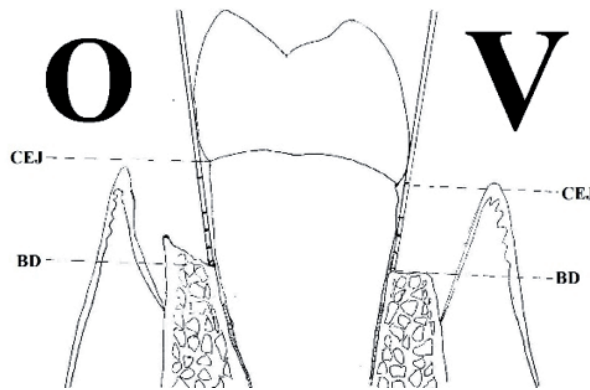


Fig. 1: Schematic drawing of a sagittal cut at the level of a molar representing intra-surgical measurements from CEJ to BD at the buccal (V) level (right side) and at the lingual (O) (left side).

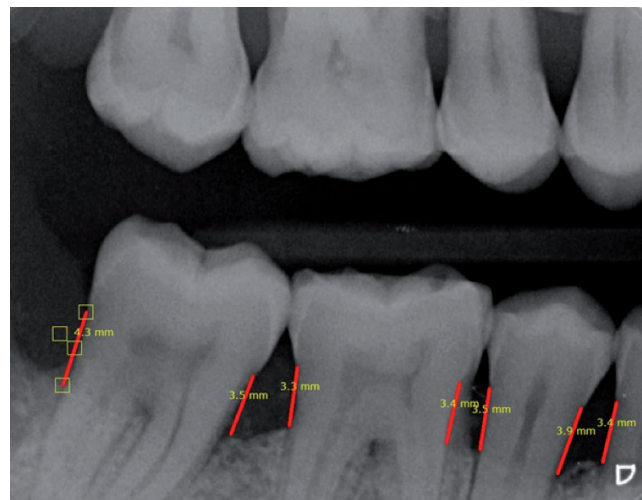


Fig. 2: Interproximal measurements on periapical radiographs.

Since the establishment of CBCT imaging modality, many studies have been conducted to assess its reliability in measuring periodontal bone breakdown, intra-bony defect width, height and length, and furcation defects [10-14].

Mol et al. [10] stated that the evaluation of alveolar bone height in relation to the cemento-enamel junction (CEJ) is the primary benefit of radiologic examination in periodontal diagnosis as it shows the severity of bone loss and whether it is localized or generalized. This linear measurement has many advantages in case it is accurately provided by CBCT: First, it prevents surgical reentries for measuring defect fill and defect resolution after

regenerative procedures [2]. Second, it has the benefit, in contrast to PA, of showing the interproximal buccal and lingual bone levels, as well as buccal and lingual bony levels. This is essential because the number of walls remaining determines the potential of regenerative procedures [15]. This measurement might also be used as a parameter for periodontal disease evaluation in periodontally compromised patients [10]. In addition, it can be a mean of quantification for disease progression or improvement after periodontal therapy.

The primary objective of our study was to compare linear measurements and furcation defects assessments on CBCT when delivered by two dedica-

ted software (coPeriodontix™, Dental Wings and Blue Sky Plan®, Blue Sky Bio, LLC, Grayslake, IL, USA), to those obtained clinically as direct surgical measurements. The secondary objective was to evaluate the accuracy of periapical radiographs to assess bone loss, compared to CBCT and surgical measurements.

Materials and methods

Study design

Patients from the department of Periodontology, Faculty of Dental Medicine at St-Joseph University, Beirut, were recruited for the study between March and November 2016. This observational study was conducted without the need for additional surgeries neither further radiographic exposures since the patients selected for this study had planned surgical treatments and CBCT scans were taken only when indicated for implant placement, bone regeneration procedures or open flap debridement. Informed consent was signed by the patients upon entry to the dental care center, patients were informed about the rationale of the study.

Inclusion criteria

Patients who presented a previous or current history of periodontitis with horizontal and vertical bone loss, a recent CBCT (taken in less than 4 weeks prior to intervention) and a treatment plan including an open flap debridement or implant placement adjacent to the investigated teeth.

Exclusion criteria

Patients with a compromised CBCT (artefacts, blurred images...) were excluded, as well patients with images presenting an inability to locate the CEJ or a fixed reference point because of carious lesions, filling material at the CEJ, metallic crowns, and amalgam fillings near the alveolar crest.

Initial X-ray examination

Peri-apical radiographs (PA) of the studied teeth were taken prior to surgery using digital radiography (Dürr dental image plates, size 2: 3 x 4 cm) using the long cone parallel technique.

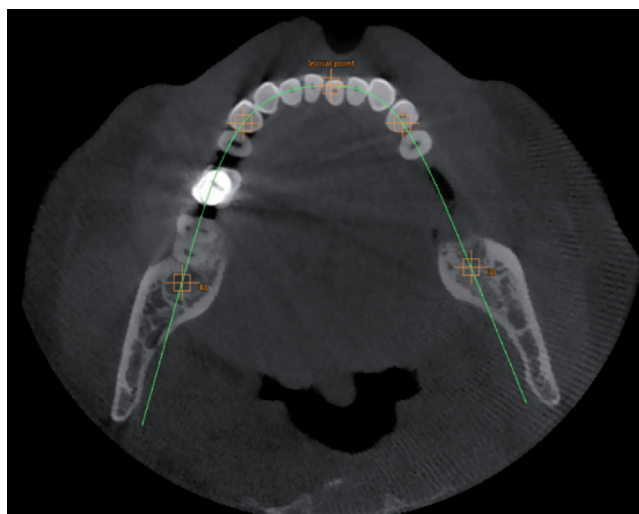


Fig. 3: Digital drawing of the panoramic curve

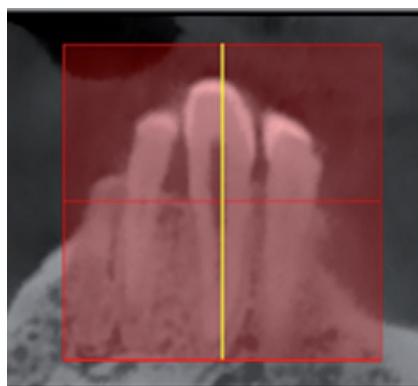


Fig. 4a: Mesio-distal section at the level of a canine

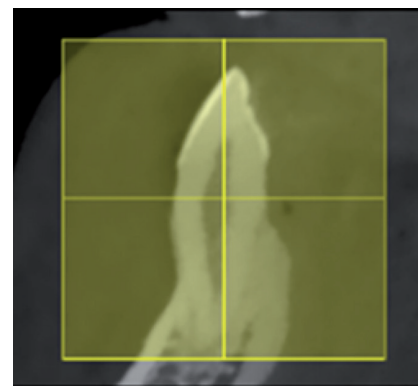


Fig. 4b: Buccal-lingual section at the level of a canine




Fig. 4c: Axial section at the level of a canine.

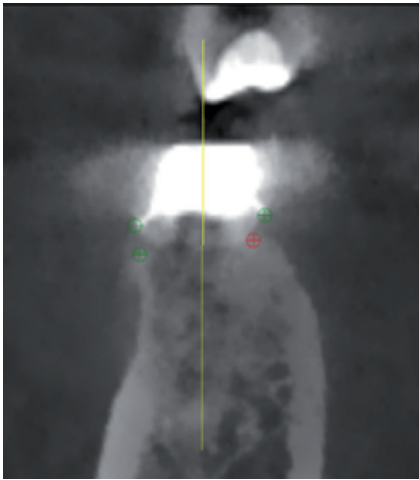


Fig. 5a: Pinpointing the CEJ and bone position in the buccal-lingual aspect of a lower molar at the middle of the tooth (sagittal cut).

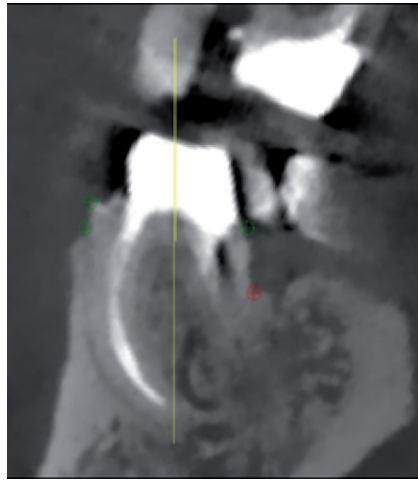


Fig. 5b: Pinpointing the CEJ and bone position in a diagonal cut from the disto-lingual to the mesio-lingual of a lower molar.

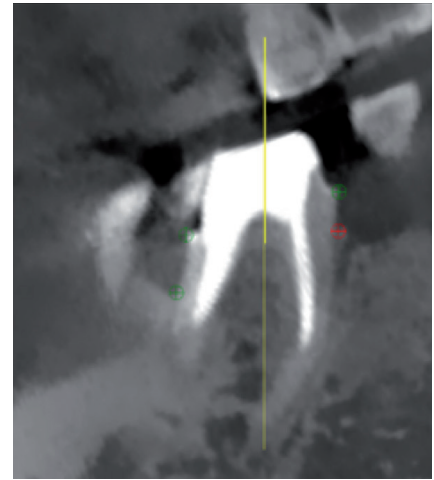


Fig. 5c: Pinpointing the CEJ and bone position in a diagonal cut from the disto-buccal to the mesio-lingual of the lower molar.

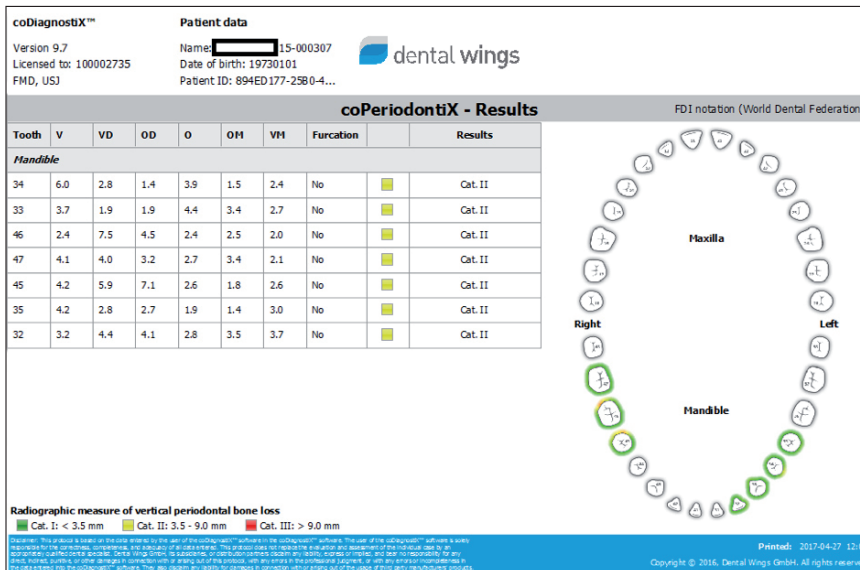


Fig. 6: Results delivered by the coPeriodontiX™ software

The CBCT scans were taken with the Newtom VGI scanner, with an effective dose of radiation of 99 μ Sv for a full field of view (FOV), with a scan time of 18 seconds (\pm 26s), x-ray emission time of 3.6 seconds (\pm 5.4s) and a voxel size of 300 μ . CBCT data were saved in DICOM format in order to transfer it to the coPeriodontiX™ (Institute Straumann AG, Basel, Switzerland) and Blue Sky Plan software (Blue Sky Bio, LLC, Grayslake, IL, USA).

Surgical procedure and clinical measurements

After administration of local anesthesia, flaps were reflected allowing identification of the cemento-enamel junction and good access to the marginal bone, then bony defects were thoroughly debrided, and all direct surgical measurements were made.

The following measurements were performed by a single operator:

Hard tissue measurements were recorded by a periodontal probe CP 15 UNC (HU-Friedy®, Chicago, IL, USA) accurate to the nearest 0.5mm, placed parallel to the long axis of the tooth. Six measurements of the linear distance between the CEJ (or the margin of an existing restoration) and the base of the defect (BD) (Fig. 1) were taken at the following locations:

- V (Buccal)
- VD (Buccal-Distal)

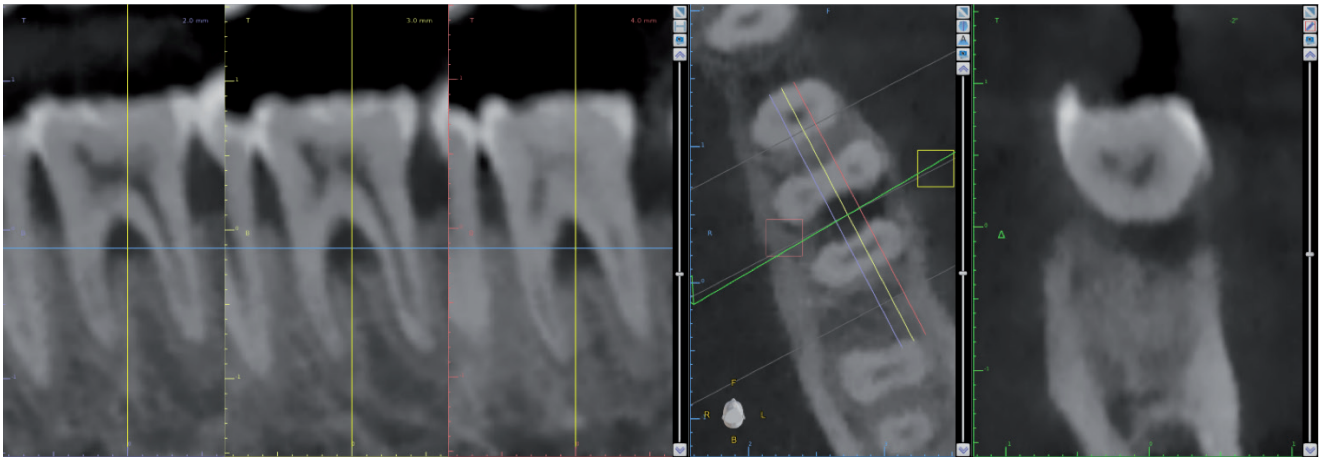


Fig. 7a: Class III furcation involvement: All bucco-lingual slices showing radiolucent lesion under the furcation area.

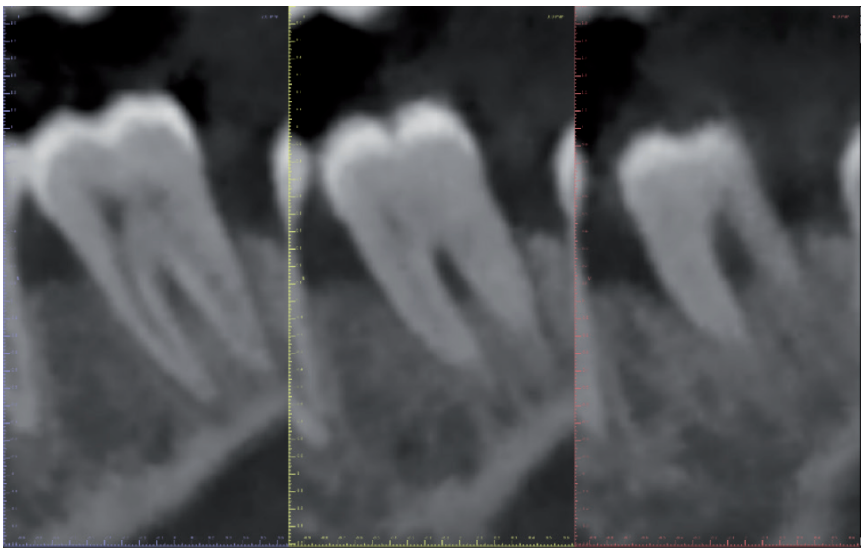


Fig. 7b: Class II furcation involvement: Bucco-lingual slices showing radiolucent lesion in the furcation area and no bone resorption in the central sagittal plane.

OD (Lingual-Distal)
O (Lingual)
OM (Lingual-Mesial)
VM (Buccal-Mesial)

Furcation defects (FD) were assessed using a curved Nabers probe (PQ2N, HU-Friedy®) according to Hamp classification (1975) [16]: at three locations for the investigated maxillary molars (buccal, mesio-palatal and disto-palatal) and at 2 loca-

tions for the mandibular molars (buccal and lingual).

Once measurements were recorded, periodontal and/or implant surgeries were finalized as planned.

Peri-apical radiograph measurements

The linear distance from the CEJ and BD were measured mesially and distally on each tooth on PA radiographs (Fig. 2), and assessment of furcation involvement was done on the investigated molars.

CBCT measurements of periodontal bone loss using the coPeriodontix™ software

DICOM images were imported into the coPeriodontix™ software. A reconstruction process of the 3D anatomy of the dental arch (teeth and surrounding bone) was performed. First, a panoramic curve was defined at the level of the CEJ (Fig. 3). In order to have an accurate positioning, the CEJ was referred to in both sagittal and coro-

nal planes. The axis of each tooth was manually oriented in a defined centered position in the 3 spatial planes: transversal (fig. 4a), sagittal (Fig. 4b) and axial (Fig. 4c).

The distance between the CEJ and the marginal bone position was measured at 6 locations on each tooth (Figs. 5a, b & c):

1. V (Buccal)
2. VD (Buccal-Distal)
3. OD (Lingual-Distal)
4. O (Lingual)
5. OM (Lingual-Mesial)
6. VM (Buccal-Mesial)

For each molar, the presence or absence of furcation involvement defect was noted without stating the degree of that involvement.

The coPeriodontix™ software delivered the results in a table and a graphic image showing the value of the distance from the CEJ to the marginal bone at the six previously indicated positions for each tooth, and the linear measurements for furcation involvement (Fig. 6).

CBCT measurements of furcation involvement using the Blue Sky Plan

Since the results delivered by the coPeriodontix™ software concerning the furcation involvement gives the horizontal width of the furcation area and not the furcation involvement according to the classification of Hamp 1975 [16], furcation involvement was measured in the Blue Sky Plan® software (Fig. 7a,7b).

After importing the DICOM data, custom mesio-distal slices (at a 1mm interval) were obtained from the vestibular to the lingual part of the lower molars in order to assess the furcation defect (FD), and sections from the buccal to the interproximal sides to assess trifurcation defects of the upper molars. Furcation defects were classified as follow:

- Degree 0 FD: when no radiolucency was observed under any roof furcation of the corresponding furcation slices.
- Degree I FD: when 1 or 2 slices showed a radiolucency under the roof of the furcation.

- Degree II FD: when 3 or more slices showed radiolucency under the roof of the furcation at the condition that at a certain level, no more radiolucency under the roof of the furcation was observed.

- Degree III FD: when all slices showed a radiolucency under the roof of the furcation from one side of the tooth to the other.

Data analysis

Surgical measurements were done by one operator (RS) and were considered as the reference values. The CBCT measurements were conducted by the same operator and monitored by an experienced periodontist (NG) in both 3D imaging and CBCT usage.

Statistical analyses were performed using a software program (SPSS for Windows, Version 22.0, Chicago, IL). The level of significance was set at $\alpha = 0.05$. The normality distribution of continuous variables was assessed using the Shapiro-Wilk tests. Since measurements were not normally distributed, non-parametric tests were carried out. Wilcoxon tests were used to compare the measurements between:

PA measurements and surgical values.

coPeriodontix™ software measurements and surgical values.

coPeriodontix™ software measurements and PA measurements.

The relationship between linear measurements using PA and surgical value, coPeriodontix™ and surgical measurements, coPeriodontix™ and PA measurements were investigated using Spearman test.

Concerning furcation involvements, Mac-Nemar tests was used to compare surgical, peri-apical, and Blue Sky Plan® values.

Results

Overall, 10 patients were included in the study. The number of teeth per patient ranged from one to 10 teeth, 2 to 6 measures were noted for each

tooth depending on the flap elevation needed for the surgery. The distance from the CEJ (or the apical margin of an existing restoration) to the base of the bony defect was measured for 270 surfaces intra-surgically. 19 measurements were excluded from the coPeriodontix™ due to the difficulty in identifying the CEJ or BD, and only 69 measures were noted for peri-apical radiographs due the two-dimensional reality of this method (Table 1).

Comparison of the linear measurements

The linear measurements on each surface were performed using three different techniques: (1) the direct surgical values considered as the reference, (2) the PA radiographs, and (3) CBCT measurements using the coPeriodontix™ software.

Periapical and surgical measurements

Statistical analysis showed that the mean linear value for PA measurements was significantly lower compared to the surgical method value ($p < 0.001$).

There was a strong positive correlation between these two measurement techniques with high PA value associated with higher surgical value (Spearman correlation coefficient $r = +0.839$; $p < 0.001$; $N = 68$).

CoPeriodontix™ and surgical measurements

Statistical analysis showed that the mean value of linear measurements using the coPeriodontix™ software was significantly lower compared to the surgical method (4.32mm and 5.53mm respectively with a $p < 0.001$).

There was a medium positive correlation between the two techniques as the high coPeriodontix™ value was associated with higher surgical value (Spearman correlation coefficient $r = +0.496$; $p < 0.001$; $N = 251$).

Periapical and coPeriodontix™ software

The mean linear measurements for PA measurements was significantly higher than the coPeriodontix™ mean value ($p = 0.005$) and a strong positive correlation between the two tech-

| | coPeriodontix™ values | Surgical values | PA values | Surgical values | PA values | coPeriodontix™ values |
|---------|-----------------------|-----------------|-----------|-----------------|-----------|-----------------------|
| N | 251 | 251 | 68 | 68 | 69 | 69 |
| MEAN | 4.32 | 5.53 | 4.45 | 5.3 | 4.43 | 4.000 |
| SD | 1.38 | 2.39 | 2.04 | 2.13 | 2.03 | 1.5703 |
| MINIMUM | 1.1 | 1 | 1 | 1 | 1 | 1.1 |
| MAXIMUM | 9.0 | 15 | 12 | 15 | 12 | 9 |

Table 1: Comparison between each of the 3 techniques used for the acquirement of the linear measurement. "N" represents the total number of surfaces measured. The mean value of the linear measurement (in mm) shows that the surgical values are the highest between all groups, and the maximum linear measurement noted concerns surgical values (15mm) suggesting that the highest bone resorption is noted intra-surgically.

| PA | Surgical | | | | Total |
|--------------|------------------|------------------|------------------|------------------|-----------|
| | No furcation | I | II | III | |
| No furcation | 4(100.0%) | 0(.0%) | 0(.0%) | 0(.0%) | 4 |
| I | 0(.0%) | 1(20.0%) | 0(.0%) | 0(.0%) | 1 |
| II | 0(.0%) | 4(80.0%) | 2(28.6%) | 2(100.0%) | 8 |
| III | 0(.0%) | 0(.0%) | 5(71.4%) | 0(.0%) | 5 |
| Total | 4(100.0%) | 5(100.0%) | 7(100.0%) | 2(100.0%) | 18 |

Table 2: Furcation involvement according to surgical findings and PA. A total of 18 furcations were compared between these 2. 4 degree I FD were overestimated into degree II FD on PA, 5 degree II FD were overestimated into degree III FD on PA, and 2 degree III FD were underestimated into degree II furcation defects on PA.

| Blueskybio | Surgical | | | | Total |
|--------------|------------------|------------------|------------------|------------------|-----------|
| | No furcation | I | II | III | |
| No furcation | 4(100.0%) | 0(.0%) | 0(.0%) | 0(.0%) | 4 |
| I | 0(.0%) | 6(100.0%) | 0(.0%) | 0(.0%) | 6 |
| II | 0(.0%) | 0(0.0%) | 7(100.0%) | 0(0.0%) | 7 |
| III | 0(.0%) | 0(.0%) | 0(0.0%) | 3(100.0%) | 3 |
| Total | 4(100.0%) | 6(100.0%) | 7(100.0%) | 3(100.0%) | 20 |

Table 3: Furcation involvement according to surgical findings and CBCT. For both modalities, 4 furcations presented no defects, 6 were noted as degree I FD, 7 were noted as degree II FD, and 3 were noted as degree III FD.

niques with high PA value associated with higher software value (Spearman correlation coefficient $r=+0.764$; $p<0.001$; $N=69$).

Assessment of furcation involvement

Six patients were examined for furcation defects. A total of 20 furcations for 9 molars (2 upper and 7 lower) were assessed using three techniques: the clinical PA radiographs, CBCT images (Blue Sky Plan®) and the surgical assessment which was considered as the reference source.

Statistical analysis showed that the diagnosis of each type of furcation involvement was significantly different between PA radiographs and surgical assessment ($p=0.01$) (table 2). In contrast CBCT and surgical evaluations were similar ($p=1.000$) (table 3).

Compared to surgical assessment, furcation involvements on PA radiographs were underestimated for 11.11%, overestimated for 50% and truly determined for 38.88% of the cases, while

two furcation involvements were not detected (table 2).

Discussion

The primary objective of this study was to compare linear measurements and furcation defects on CBCTs to those obtained clinically by direct surgical measurements. The first in vitro study to address the accuracy of linear measurements in CBCTs was conducted on cadavers in 2006 [5]. In contrast

to our present study, the results showed no statistically significant difference for this modality when compared to direct measurements. However, the findings of that study should be interpreted with caution because the CEJ was replaced by gutta percha markings, the bony defects were artificially made by burs which do not reproduce the exact morphology and demineralization of bone in periodontal diseases. Moreover, since the measurements were obtained from skulls, there was absence of motion when taking radiographs in contrast to patients.

Another *in vitro* study by Vandenberghe et al. [4] showed more accurate results, with no statistical difference between CBCT (90% accuracy) and PA radiographs (82% accuracy) where 1 mm discrepancy for direct measurements was allowed. However, this *ex vivo* study had inherent factors that differ from clinical situations: standardized repositioning and stabilization provided by a rigid occlusal key during exposure ensured a complete absence of motion for the image intakes for both modalities. Gutta-percha was positioned at the level of the faded JEC. There was no interference of soft tissues (cheeks, gingiva, tongue, lips and alveolar mucosa) when measurements were performed on the dry skull. However, such accurate probe positioning and fabrication of waxed bite blocks for PA radiographs cannot be reproduced on patients.

Our study showed similar findings to that conducted by Grimard et al. [2] regarding linear measurements from CEJ-BD, as they had statistically different values between surgical measurements and CBCTs and PA radiographs. They found an underestimation of the CBCT values, and to a lesser extent for the PA radiographs. The authors explained that many factors could have accounted for this discrepancy: the thorough debridement of the surgical site prior to the measurements could have removed some of the mineralized bone, observed on the CBCT, resulting in higher surgical values. Another rea-

son for discrepancy could be the probe angulation at the site of measurement.

The study of Li et al. [13] showed also an underestimation of the CEJ-BD values for CBCT (mean value was 8.14 mm with CBCTs versus 8.9 mm for surgical), according to the authors, CBCT had no advantages over PA for CEJ-BD measurements.

Feijo et al. [12] performed an *in vivo* study on 12 teeth, resulting in 72 linear measurements from the CEJ to BD, compared to 251 linear measurements in our present study. They showed a statistically significant difference between surgical and CBCT measurements concerning the buccal and palatal aspects, but no difference for interproximal measurements. The authors highlighted the fact that surgical measurements were nearest to 1 mm, while CBCT measurements were calculated in decimals and lacked contrast. In addition, bone quality and details of lamina dura were not well defined as in the PA radiographs, and this observation was also perceived in our present study.

In a recent study conducted by Guo et al. [8] the authors relied also on the six-site linear measurements but had no statistically significant difference between surgical and CBCT measurements. This study was conducted by trained investigators on CBCT measurements (three investigators were post-graduate students in dental and maxillofacial radiology, and one was a post-graduate student in periodontology); measurements were done under strict conditions (calibration of the observers) which is more important than the observers clinical experience [17]. However, the finding that is in line with our present study is that values delivered by CBCT tend to be lower than the ones measured during surgery suggesting that bone loss is actually greater clinically to what is observed on CBCTs.

Another important factor for CBCT measurement is image quality; it is in fact related to parameters such as milliamperage, kilo-voltage and voxel size [15]; the images acquired in this study

were regular computed tomography parameters with a maximum FOV (field of view) of 15 cm x 15 cm and a maximum voxel size of 0.3 mm, implying that a slightly better resolution of the CBCT slices was obtained compared to other *in vitro* studies where they had a voxel size of 0.4 mm [4,5] but inferior to some *in vivo* studies that used a voxel size of 0.2 mm [2,8,12].

The secondary objective of our study was to evaluate the accuracy of periapical radiographs. This modality showed a lack of precision when depicting the height from the CEJ to BD. This was in accordance with other *in vivo* studies [2,13] where there was a tendency for PA to underestimate surgical measurements. This underestimation might be due to the cancellous nature of the apical part of the defect that is eliminated with thorough debridement which can lead to deeper probe insertion in surgeries. An elevated correlation was seen in our study between PA and surgical values (83.9%) while a moderate correlation was found between surgical and CBCT measures (49.6%). One possible factor accounting for this discrepancy could be the fact that PA radiographs were manually measured on the screen and noted, while CBCT measurements were numerically delivered on a table after inserting the landmarks points. These numerical values seemed anarchical as some values did not match with the bone level on the CBCT slices implying the presence of an error in the coding of the software.

Regarding furcation involvement, the coPeriodontix™ software was unable to deliver the degree of furcation involvement according to the Hamp classification. It is due to the lack of parameters requested by the software. It requests the CEJ position along with the bone position on each determined slice. If the tooth is multi-rooted, and for the software to be able to determine the degree of FD, it should ask for additional landmarks: the most coronal point of the roof of the furcation and the deepest part of the furcation (or the absence of the lat-

ter in case of degree III FD). But the software only delivered a linear measurement for the horizontal length of the roof of the furcation when the operator indicated the presence of a multi-rooted tooth.

The use of the Blue Sky Plan® software allowed a direct visualization of the furcation area on the CBCT slices and the values obtained matched the intra-surgical measurements in 100% of the cases according to Hamp classification. This number suggests that CBCT is an accurate tool for assessment of furcation defects. Other studies found a high correlation between CBCT and intra-surgical measurements [18,19]. In the study of Walter et al. (2010), 84% of the CBCT data were confirmed by intra-surgical findings [19]. This lower percentage might be explained by the difference in the methodologies between the two studies. First, Walter et al. assessed only maxillary molars in contrast to our study where only 2 maxillary molars were assessed. The lower radiological density (gray values) of the maxillary bone compared to the mandibular bone might have affected the accuracy of the measurements. Second, they had a superior number of furcation involvement (75) compared to our study where only 20 furcations were assessed. Finally, the open flap surgeries for intra-surgical furcation assessment were conducted three to six months after the CBCT scans compared to 4 weeks in the present study. This might allow bone remodeling/resorption to take place between the time of the scan and surgery.

In our study, PA radiographs showed a low accuracy in depicting the degree of furcation defects, as two furcations were excluded due to the inherent disadvantage of PA to identify vestibular maxillary FD. In fact, 11.11% of furcation defects were underestimated, 50% were overestimated and only 38.88% were in accordance with the intra-surgical results. This finding is in line with other studies [6] where the sensitivity of a PA to identify an actual furcation invasion was 38.7%. This meant that “furcation arrow” defi-

ned by the authors as the small triangular radiolucent shadow sometimes seen across the mesial or distal roots of maxillary molars, showed a small predictive value for the presence of furcation bone loss and that most actual furcation involvement were not associated with this radiolucent shadow. This finding, and our results suggests that post anesthesia bone sounding has greater diagnostic value in furcation assessment than pre-anesthetic probing.

Conclusion

This study showed that linear surgical measurements are not accurately replicated by the coPeriodontix™ and PA radiographs, where both had underestimation of the real bone loss, with the coPeriodontix™ displaying the least bone loss. CBCT measurements (with Blue Sky Plan® software) can accurately reflect the true furcation defect in posterior maxillary and mandibular molars.

References

- Hourdin S, Glez D, Gagnot G, Sorel O, Jeanne S. A screening method for periodontal disease. *J Dentofacial Anom Orthod* 2013;16:104.
- Grimard BA, Hoidal MJ, Mills MP, Mellonig JT, Nummikoski PV, Mealey BL. Comparison of clinical, periapical radiograph, and cone-beam volume tomography measurement techniques for assessing bone level changes following regenerative periodontal therapy. *J Periodontol* 2009;80:48-55
- Graetz C, Plaumann A, Wiebe JF, Springer C, Salzer S, Dorfer CE. Periodontal probing versus radiographs for the diagnosis of furcation involvement. *J Periodontol* 2014;85:1371-1379.
- Vandenberghe B, Jacobs R, Yang J. Diagnostic validity (or acuity) of 2D CCD versus 3D CBCT-images for assessing periodontal breakdown. *Oral Surg Oral Med Oral Pathol Oral Radiol Endod* 2007;104:395-401.
- Misch KA, Yi ES, Sarment DP. Accuracy of cone beam computed tomography for periodontal defect measurements. *J Periodontol* 2006;77:1261-1266.
- Deas DE, Moritz AJ, Mealey BL, McDonnell HT, Powell CA. Clinical reliability of the "furcation arrow" as a diagnostic marker. *J Periodontol* 2006;77:1436-1441.
- Aljehani YA. Diagnostic applications of cone-beam CT for periodontal diseases. *Int J Dent* 2014; Article ID 865079, 5 pages, 2014. <https://doi.org/10.1155/2014/865079>.
- Guo Y-J, Ge Z-p, Ma R-h, Hou J-x, Li G. A six-site method for the evaluation of periodontal bone loss in cone-beam CT images. *Dentomaxillofac Radiol.* 2016; 45(1):20150265. doi: 10.1259/dmfr.20150265.
- Mandelaris GA, Scheyer ET, Evans M, et al. American Academy of Periodontology best evidence consensus statement on selected oral applications for cone-beam computed tomography. *J Periodontol* 2017;88:939-945.
- Mol A, Balasundaram A. In vitro cone beam computed tomography imaging of periodontal bone. *Dentomaxillofac Radiol* 2008;37:319–324.
- Fleiner J, Hannig C, Schulze D, Stricker A, Jacobs R. Digital method for quantification of circumferential periodontal bone level using cone beam CT. *Clin Oral Investig* 2013;17:389-396.
- Feijo CV, de Lucena JG, Kurita LM, da Silva Pereira SL. Evaluation of cone beam computed tomography in the detection of horizontal periodontal bone defects: an in vivo study. *Int J Periodontics Restorative Dent* 2012; 32: e162–e168.
- Li F, Jia PY, Ouyang XY. Comparison of measurements on cone beam computed tomography for periodontal intrabony defect with intrasurgical measurements. *Chin J Dent Res* 2015; 18:171-176.
- Bradley S, McAllister, V, Thomas Eshraghi. Cone-Beam Computed Tomography: An Essential Technology for Management of Complex Periodontal and Implant Cases. *J Periodontol* 2017. 937-938. doi: 10.1902/jop.2017.1710001
- de Faria Vasconcelos K, Evangelista KM, Rodrigues CD, Estrela C, de Sousa TO, Silva MA. Detection of periodontal bone loss using cone beam CT and intraoral radiography. *Dentomaxillofac Radiol* 2012; 41:64–9. doi: 10.1259/dmfr/13676777.
- HampSE, NymanS, Lindhe J. Periodontal treatment of multirrooted teeth. Results after 5 years. *J Clin Perio- dontol* 1975;2:126-135.
- Savage A, Eaton KA, Moles DR, Needleman I. A systematic review of definitions of periodontitis and methods that have been used to identify this disease. *J Clin Periodontol* 2009; 36: 458–67. doi: 10.1111/j.1600-051X.2009.01408.
- Qiao J, Wang S, Duan J, et al. The accuracy of cone beam computed tomography in assessing maxillary molar furcation involvement. *J Clin Periodontol* 2014; 41:269-274.
- Walter C, Weiger R, Zitzmann NU. Accuracy of three dimensional imaging in assessing maxillary molar furcation involvement. *J Clin Periodontol* 2010;37: 436-441.