

10-10-2019

## Knowledge and behavior towards oral lichen planus: An observational study

Hiam WEHBÉ

Edgard NEHMÉ

Follow this and additional works at: <https://digitalcommons.aaru.edu.jo/iajd>

---

### Recommended Citation

WEHBÉ, Hiam and NEHMÉ, Edgard (2019) "Knowledge and behavior towards oral lichen planus: An observational study," *International Arab Journal of Dentistry*. Vol. 10: Iss. 2, Article 5.  
Available at: <https://digitalcommons.aaru.edu.jo/iajd/vol10/iss2/5>

This Original Article is brought to you for free and open access by Arab Journals Platform. It has been accepted for inclusion in International Arab Journal of Dentistry by an authorized editor. The journal is hosted on [Digital Commons](#), an Elsevier platform. For more information, please contact [rakan@aar.edu.jo](mailto:rakan@aar.edu.jo), [marah@aar.edu.jo](mailto:marah@aar.edu.jo), [u.murad@aar.edu.jo](mailto:u.murad@aar.edu.jo).

# KNOWLEDGE AND BEHAVIOR TOWARDS ORAL LICHEN PLANUS: AN OBSERVATIONAL STUDY

Hiam Wehbé\* | Edgard Nehmé\*\*

## Abstract

Lichen planus is an immunologically mediated mucocutaneous disease that is triggered by multiple etiological agents. Oral lichen planus (OLP) is characterized by a slow evolution without complete remission, nor spontaneous healing.

The establishment of an early diagnosis is essential to be able to support and to relieve patients with oral lichen plan lesions especially those in active phase.

This requires recognition by the dentists of the signs and symptoms, characteristics and different clinical forms under which this pathological entity may occur.

The purpose of our survey was to evaluate the knowledge of dentists (teachers and Master students) in the Faculty of Dental Medicine of Saint Joseph University, Beirut, on the oral lichen planus by means of a survey study.

**Keywords:** Lichen planus - oral lichen planus - auto-immune disease – diagnosis - corticosteroid.

IAJD 2019;10(2):78-86.

# CONNAISSANCES ET COMPORTEMENT VIS-A-VIS DU LICHEN PLAN ORAL : ETUDE OBSERVATIONNELLE

## Résumé

*Le lichen plan buccal (LPO) est une affection de la muqueuse buccale, vraisemblablement due à un dérèglement de la réponse immunitaire, caractérisée par une évolution lente, sans rémission complète, ni guérison spontanée.*

*L'établissement d'un diagnostic précoce est essentiel pour pouvoir soulager les patients atteints de lésions lichéniennes, en particulier celles en phase active. Cela nécessite la reconnaissance par les dentistes des signes et symptômes, des caractéristiques et des différentes formes cliniques sous lesquelles cette entité pathologique peut se présenter.*

*Notre enquête visait à évaluer, à l'aide d'une enquête, les connaissances des dentistes (enseignants et étudiants en Master) de la faculté de médecine dentaire de l'Université Saint-Joseph de Beyrouth sur le LPO.*

**Mots clés:** lichen plan – lichen plan oral - maladie auto-immune - diagnostic - corticoïdes.

IAJD 2019;10(2):78-86.

\* DDS,  
University diploma in Oral Pathology,  
Master in Periodontology,  
Master in Research, Saint-Joseph University, Beirut, Lebanon  
Hiam.wehbe@usj.edu.lb

\*\* Professor,  
Dpt of Diagnosis and Oral Medicine,  
Director of Postgraduate Programs of Oral Medicine,  
Faculty of Dental Medicine, Saint-Joseph University, Beirut,  
Lebanon

## Introduction

The lichen planus (LP) is a mucocutaneous, inflammatory and chronic dermatosis [1]. The cutaneous lichen appears as small polygonal, flat-topped, violet-colored papules with a glossy or transparent surface and white lines (Wickham striae) or gray-white spots [2].

Skin lesions most commonly occur in the forearms, wrists, dorsal surface of the hands, the anterior surface of the feet and neck [1]. Genital LP occurs in about 50% of women and 25% of men associated with skin LP [1]. Rarely, the scalp, nails, esophagus, larynx or conjunctiva are affected [3].

Oral LP (OLP) is common and usually asymptomatic. It is usually mild and chronic. It can evolve over a very long period and can go through a succession of phases of activity and quiescence. The lesions persist throughout the illness and are recurrent.

The typical oral manifestation of LP is characterized by a disorder of keratinization, symmetrical white reticular lesions in the oral mucosa, although various clinical features can be observed (Figs. 3 & 4).

The prevalence of OLP varies between 0.1% and 4% depending on the authors and the studied populations: 0.5% in Japan, 1.9% in Sweden, 2.6% in India [4, 5].

The OLP develops preferentially in the age group between 30 and 60 years [6, 7]. Women are more affected than men at a ratio of 2: 1. OLP is less frequent in children. It is often misdiagnosed as candidiasis, recurrent herpes or stomatitis.

The exact etiology of the OLP remains unidentified. Although various antigens have been considered, what triggers the inflammatory response of T lymphocytes is unknown. Suggested predisposing factors include genetic factors, stress, trauma and infections. Smoking and alcoholism (heat and irritation of the mucous membranes by vapors, class of Betel [4, 6]) could promote the development of lichenous lesions.

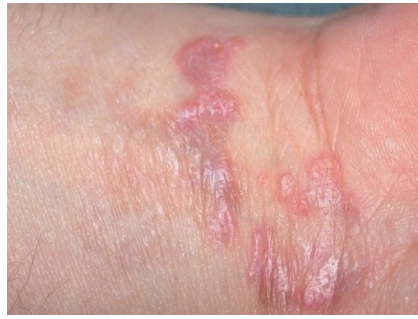

Fig. 1: Wickham striae that course the surface of a papule of lichen planus.

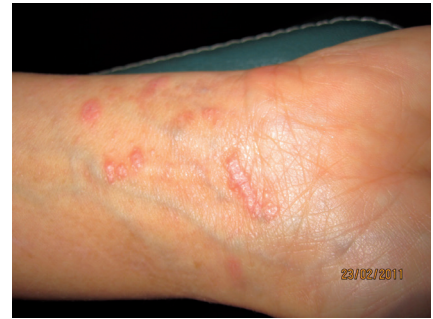

Fig. 2: Lichen planus lesions on the forearm.

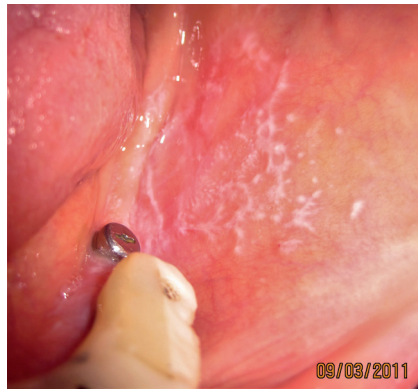


Fig. 3: Reticular oral lichen planus of the inner side of the cheek.

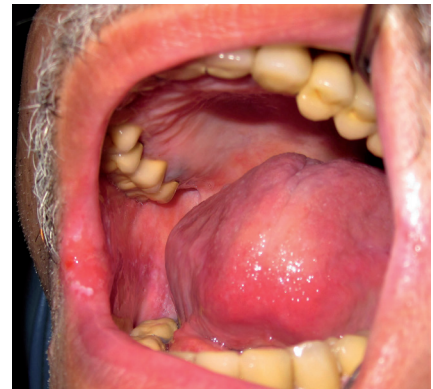

Fig. 4: Muco-cutaneous lichenous lesions.

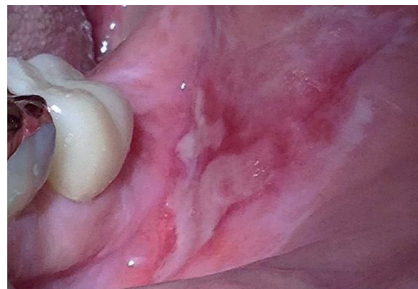

Fig. 5: Erosive LPO.

Various associations between the OLP and certain systemic pathologies are described in the literature. Most are controversial, due to lack of documentation or to geographical disparities [8, 9]. These include Grinspan syndrome, liver disease and graft-versus-host disease [10].

OLP should be distinguished from lichenoid reactions [11, 12]. A lichenoid reaction is of known cause, induced by certain drugs or by contact with dental materials (such as mer-

cury, gold, chromium, copper sulphate and certain composite resins) and may evolve differently from an OLP [13]. The diagnosis of these lesions is guided by the anamnesis because the histology does not always determine their induced nature [7].

OLP is a lesion with a potential for malignant transformation, especially in these (Fig. 5) erosive and atrophic forms; the dentist could be the first to establish early diagnosis, initiate treatment, refer the patient to a specialist

and insure an adequate follow-up if necessary.

According to our review of the literature, it has been found that dentists fail to establish an accurate diagnosis of OLP due to multifactorial etiology and lack of knowledge about the disease [14]. Hence the idea of conducting a survey on the knowledge of a sample of dentists on the OLP in order to detect the shortcomings in the diagnosis of the OLP and to propose adequate seminars on the management of this disease.

#### Materials and methods

A survey study was conducted based on a comprehensive questionnaire. The structured questionnaire was established after a review of the literature and was divided into two parts. The first part concerned socio-demographic data of participating dentists, the second one included questions about recognizing the clinical features of the OLP and about their relevant professional experience in managing OLP patients: etiologies, localizations, clinical forms, symptoms, need and utility to diagnose this potentially malignant condition, referral procedure to specialists and contraindicated dental procedures in these patients.

The questionnaire obtained the agreement of the Ethics Committee of Research of Saint-Joseph University of Beirut, under the reference USJ-2019-42. In this questionnaire, only the data concerning the age, academic status and specialty of the dentist were collected, useful information for the statistical study.

As inclusion criteria, the participants must all be holders of a diploma of dentist, be teachers or post-graduate students of Master's degree, at the various departments of the faculty of Dental Medicine of Saint-Joseph University, Beirut. Graduate dentists who are not faculty members or who are not pursuing a Master's degree at the faculty have been excluded from the study. The questionnaires were distributed and collected by hand to all the participants; they were assessed

Field of specialization	Numbers	Percentage
Oral Surgery	13	14.1
Restorative Dentistry	7	7.6
Endodontics	18	19.6
Endodontics/ Oral Pathology	1	1.1
Occlusodontics	1	1.1
Orthodontics	9	9.8
Periodontology	7	7.6
Perio/ Prosthesis	1	1.1
Oral Pathology	4	4.3
Oral Pathology / Periodontology	2	2.2
Pedodontics	8	8.7
Prosthodontics	18	19.6
Multidisciplinary	2	2.2
Radiology	1	1.1

Table 1: Percentage of the participants in the study depending on their specialty.

for completeness and only the completed questionnaires were taken into account for the final statistical analysis. 100 questionnaires were distributed; 8 were found to be ineligible.

### Statistical analysis

The statistical software "SPSS for Windows" (Chicago, IL, USA, version 25.0) was used for the statistical analysis of the data. The significance level used corresponds to  $p \leq 0.05$ .

Averages and standard deviations were used to describe the quantitative variables. Percentages were used to describe the qualitative variables.

The normality of the distribution of quantitative variables was evaluated by the Kolmogorov-Smirnov tests.

Student's tests and Mann-Whitney tests were conducted to compare quantitative variables between groups.

The Kruskal-Wallis test was conducted to compare the quantitative variable between several groups. Chi-squared tests and Fisher Exact tests were used to compare percentages.

A score was assigned to each completed questionnaire after correction and evaluation of the responses.

The Pearson correlation coefficient was used to study the correlation between the score and the number of years of experience.

### Results

Ninety-two questionnaires were completed (the response rate was 92%). Of the study participants, 44 were men (48%) and 48 women (52%). The mean age of men was  $38.50 \pm 11.968$  years (range 23 - 61 years) and that of women was  $32.40 \pm 10.225$  years ( $p = 0.010$ ). The average number of years of experience was  $12.91 \pm 11.339$  years (range: 1-37 years). 53 (57.6%) are teachers with a Master's degree or equivalent, 35 (38%) are post-graduate students pursuing a Master's degree and 4 (4.3%) are teachers with a certificate of specialized education (CES). The table 1 represents the percentage of the participants depending on their specialty.

	Numbers	Percentage
<b>Nature of the disease (OLP)</b>		
Autoimmune	87	94.6
Bacterial	1	1.1
I do not know	4	4.3
<b>The lichen plan is a</b>		
mucous lesion	16	17.4
mucocutaneous lesion	75	81.5
I do not know	1	1.1
<b>LP can affect nails</b>		
Yes	55	59.8
No	20	21.7
I do not know	17	18.5
<b>OLP lesions are</b>		
Unilateral	36	39.1
Bilateral	50	54.3
I do not know	6	6.5
<b>The most frequent sign of OLP is</b>		
Burning sensation	73	79.3
Altered taste	9	9.8
Pain during meals	13	14.1
Bleeding	4	4.3
I do not know	6	6.5
<b>OLP plus prevails in the group</b>		
20-40 years	14	15.2
40-60 years	60	65.2
> 60 years	9	9.8
I do not know	9	9.8

Table 2: Dentists' knowledge of the OLP (Part 1).

Knowledge of dentists on the OLP  
The dentists' knowledge of the OLP is shown in tables 2, 3 and 4. Most dentists responded that the OLP is an autoimmune disease (94.6%), and that it is a muco-cutaneous lesion (81.5%), which can affect nails (59.8%). 53.3% of participants know that this is a bilateral lesion.

The burning sensation is the most common sign according to 78.3% of dentists whereas the age group at which the OLP is more prevalent is 40-60 years (64.1%). Only 9.8% of the survey participants found that an alteration of the taste sensation could be a clinical complaint of patients with OLP.

69.6% of respondents said the OLP is reactive to a dental material, and a

few (5.5%) gave the example of amalgam restorations.

33% of dentists have examined patients with OLP lesions during their practice; 56.5% of them do not know the OLP diagnostic criteria. 21.7% responded that OLP diagnosis is based on clinical appearance and characteristics, while 21.7% are aware that bio-

	Numbers	Percentage
<b>There is a    between OLP and</b>		
Diabetes mellitus	19	20.7
hepatitis C	30	32.6
autoimmune disease	69	75.0
I do not know	4	4.3
<b>OLP is reactive to a material of dental use</b>		
Yes	64	69.6
No	11	12.0
I do not know	16	17.4
Missing answers	1	1.1
<b>Have you seen any OLP lesions</b>		
Yes	31	33.7
No	58	63.0
I do not know	3	3.3
<b>Diagnostic criteria of OLP</b>		
Clinical aspects	20	21.7
Histo-pathological aspects	20	21.7
Both aspects	20	2.2
I do not know	40	43.4
<b>Clinical form of the OLP is</b>		
Strictly white	61	66.3
Erythematous	60	65.2
Atrophic	34	37.0
Erosive	61	66.3
Bullosa	18	19.6
I do not know	1	1.1
<b>OLP is a pre-malignant lesion</b>		
Yes	61	66.3
No	22	23.9
I do not know	9	9.8
<b>Risk of malignant transformation of OLP is estimated at</b>		
0-5%	40	43.5
5-10%	24	26.1
10-20%	1	1.1
> 20%	6	6.5
I do not know	21	22.8

Table 3: Dentists' knowledge of the OLP (Part 2).

psy and histopathology are the tests of choice for diagnosing OLP.

The study also showed that the number of years of practice was significantly associated with dentists' knowledge concerning:

- the bilateral localization of OLP lesions ( $p = 0.034$ );
- the link between OLP and diabetes mellitus ( $p = 0.005$ );
- the potential malignant transformation of the OLP lesions ( $p = 0.031$ ).

This study showed a positive average correlation between the number of years of experience and the dentists' knowledge score on OLP ( $r = 0.307$ ,  $p = 0.003$ ).

Dentists who opt to refer the patient to an oral medicine specialist have significantly more years of experience than other dentists ( $p = 0.048$ ) (Table 5).

	Numbers	Percentage
<b>The patient with OLP is referred to</b>		
Oral medicine specialist	67	72.8
Oral surgery specialist	17	18.5
ENT specialist	10	10.9
I do not know	3	3.3
<b>The cutaneous and oral lesions of the LP</b>		
Are treated the same way	16	17.4
Are not treated the same way	55	59.8
I do not know	21	22.8

Table 4: Dentists' knowledge of the OLP (3rd part).

Specialty to which dentists refer the patient in case of suspicion of OLP		
	N	Mean (years) ± Standard deviation
Oral medicine	67	14.67 ± 11.619
Oral surgery	14	6.14 ± 6.916
ENT	8	11.75 ± 12.826
I do not know	3	8.33 ± 6.807

Table 5: Specialty to which dentists refer the patient in case of suspicion of OLP depending on years of experience.

## Discussion

Lichen planus is a chronic autoimmune disease that affects the oral mucosa as well as the skin, genital mucosa and other sites. According to the literature review, our study was the first study conducted in the Faculty of Dental Medicine of Saint-Joseph University, to evaluate the knowledge of participating dentists about the clinical features, location, prevalence, potential malignant transformation, diagnosis and appropriate management of patients with OLP within a Faculty.

To the best of our knowledge, a similar study was recently published by Prasad et al. in 2018 [14]. The authors analyzed the knowledge of general dentists in the Bangalore region of India and their practices regarding the OLP. They evaluated several notions such as the prevalence of OLP cases,

the signs and symptoms and the diagnosis of OLP lesions.

OLP is often asymptomatic, but it passes through active phases associated with a sensation of minor discomfort. This is observed especially in case of papular, reticulated and plate types lesions. On the other hand, atrophic and ulcerous lesions can cause burning sensations, intense pain, felt especially during meals and when brushing teeth.

In this study, 79.3% of dentists reported that the burning sensation was the most common symptom complained of by patients, followed by pain during meals (14.1%). These latter results are concordant with others reported in the literature [15, 16]. However, in the study by Prasad et al. [14], 39% of the participating dentists reported that the burning sensation was the most commonly reported

symptom, followed closely by taste impairment (38%).

The World Health Organization (WHO) classifies the OLP as a "potentially malignant lesion" [17] with a risk of unspecified malignant transformation and suggests monitoring patients closely. A lesion initially diagnosed as OLP has different potential for malignant transformation over time, although these findings remain controversial.

Richards [18] published in December 2018 the results of his study in which a review of the literature was made in search of malignant transformation rates. Twenty-one studies were included, 18 were retrospective and three prospective. Follow-up periods ranged from 18 to 300 months. Ninety-two cases of oral squamous cell carcinoma developed during the observation period. The overall transformation

rate was 1.4%; 1.37% for OLP and 2.43% for lichenoid lesions. He suggests that the erosive type and the occurrence of OLP at the tongue should be considered as risk factors for malignant transformation of the OLP.

An article recently published by Atzori et al. [19] in March 2019 describes the impressive progression in three months of a case of OLP squamous cell carcinoma.

In our study, 66.3% of dentists reported that OLP is a potentially malignant condition, a percentage similar to that reported by Prasad et al. [14] (68%). 72.8% of the dentists in our study preferred to refer patients to an oral medicine specialist for proper management, compared to 55% of Prasad study participants.

Many previous studies have found an association between OLP and other diseases. Recently, the study by Kumar et al. [20] evaluated the association of OLP with diabetes mellitus, dyslipidemia, metabolic syndrome, thyroid dysfunction and infection with hepatitis C virus (HCV). The authors found that there is a clear link between OLP on the one hand and dyslipidemia and diabetes mellitus on the other. Screening for dyslipidemia and diabetes mellitus in all OLP patients would assist in early detection, initiation of treatment, and prevention of long-term morbidity.

Li et al. (2017) [21] conducted a meta-analysis to systematically evaluate the association between OLP and autoimmune thyroid disease (Hashimoto's thyroiditis). Eight studies were selected, including four case-control studies included in the final meta-analysis. The authors revealed a significantly elevated prevalence of thyroiditis in patients with OLP compared to control groups, suggesting that routine screening for thyroid disease might be beneficial for patients with OLP. However, due to the small number of studies included, further research is needed to confirm the results.

In our study, 75% of participants thought that the OLP could be primarily linked to another autoimmune

disease; an association between OLP and diabetes was mentioned by 20.7% of participants.

Metallic contact allergy may play an important role in the pathogenesis and management of oral lichenoid lesions patients diagnosed as OLP.

Martin et al. [22] examined the association of dental materials with OLP and, in particular, the effects of amalgam, the corrosion state of amalgam, gold and dissimilar metals in continuous contact. The results obtained suggest that amalgam corrosion and the presence of a "galvanic effect" from dissimilar dental materials in continuous contact (bimetalism) are associated with an increased risk of OLP.

However, Lopez-Jornet et al. [23] found no statistically significant clinical or histopathological difference between OLP with or without dental amalgam. The study involved 213 patients with OLP. In the present study, 69.6% of dentists knew that the OLP could be reactive to a dental material such as amalgam.

The diagnosis of OLP is based on both clinical manifestations and histopathological features. Previous history, typical oral lesions, and skin involvement are usually sufficient to diagnose OLP, but laboratory studies and biopsy may be required [24]. The direct immunofluorescence test will make it possible to positively diagnose an erosive bullous OLP or that of a pemphigus vulgaris, a pemphigoid benign mucosa, dermatitis herpetiformis, and linear IgA bullosa dermatosis. The most important feature of OLP is the linear distribution of fibrin.

A biopsy is imperative on an active OLP to exclude a malignant evolution. In all cases this biopsy is of a certain medicolegal interest. It will also make it possible to positively diagnose OLP in relation to other oral diseases such as white leukoplakia lesions, keratoses of other origins (traumatic, physical or chemical) or those of infectious origins (chronic hyperplastic candidiasis) or related dermatological autoimmune diseases (discoid erythe-

matusus lupus) or gastrointestinal diseases (Crohn's disease) or anemic conditions.

In the study by Prasad et al. [14], 79% of participants reported being able to diagnose OLP based on the clinical aspect alone compared to 21.7% of participants in our study. In addition, 51% of dentists surveyed by Prasad et al. knew that biopsy was the procedure of choice for definitive diagnosis of a lichen lesion and that follow-up was necessary in these patients, compared to 21.7% of our sample.

The diagnostic criteria of the OLP established by the WHO in 1978 were modified by Van der Meij & Van der Waal in 2003 [25]. The clinical and histopathological criteria were revisited, the presence of more or less symmetrical bilateral lesions becoming a fundamental diagnostic criterion of this entity. However, these recommendations are not unanimous among the medical authorities.

The ambiguity in the diagnosis of OLP is sometimes due to the existence of lesions that have a clinical and pathological resemblance to lichenous lesions (Ex.: Oral Psoriasis) (Sanketh et al., [26]). In the study by Raj and Patil [27], the authors attempted to highlight the most observed errors in the provisional diagnosis of OLP and associated lesions, such as oral epithelial dysplasia (OED), OLP with dysplasia and oral lichenoid lesions (OLL). They noted the possible existence of an isolated entity they called "oral lichenoid dysplasia" (OLD). It would be a primitive epithelial dysplasia with secondary lichenoid histological features, as opposed to an OLP with dysplasia, which is an OLP presenting secondarily during its evolution dysplastic characters. Based on all these data, a modified diagnostic approach seems appropriate; it would make it possible to go from the provisional diagnosis to the definitive diagnosis as soon as a lichenian lesion sets in.

The goal of the OLP treatment is to relieve pain, to reduce the patient's functional discomfort, to treat active



lesions and to follow-up by monitoring their progress.

The treatment can be administered by topical or systemic application. The systemic route is especially indicated in case of concomitant skin involvement and in case of failure of local treatment.

We will retain from the review of the literature on the treatment of lichens the following elements [28]:

- The priority of the topical application of corticosteroids in first intention and that until resolution of OLP lesions.

- The use of general corticosteroid therapy, more or less supported by topical applications on accessible lesions, in the presence of severe and diffuse lesions (oral and oropharyngeal).

- Topical tacrolimus should be used as a second-line treatment and for a period not exceeding one month, knowing that at the end of treatment, the risk of imminent or delayed recurrence is higher compared to that occurring after corticosteroid therapy.

- The use of retinoids has long since been discontinued, with some studies reporting the potential risk of transformation into cancer.

Aloe Vera, or aloe, is sometimes useful in the treatment of OLP because this plant can decrease the intensity of pain and reduce the size of lesions, with a favorable side-effect profile [29].

In our study, only 17.4% responded that skin lesions and mucous membranes of the LP are treated in the same way.

Oral rehabilitation of OLP patients is a major challenge for clinicians. Implant placement in these patients is controversial. Scientific evidence is limited, mainly clinical cases and clinical case series.

In the review of the literature of Petruzzi et al. in 2012 [30], eight studies (41 patients with OLP lesions who had been rehabilitated by implant-prosthetic restorations) met the inclusion criteria. The implant survival rate was 94.8% on an average follow-up of 56.5 months. The authors stated that the OLP was not an absolute contrain-

dication to implant placement and that there was no increased risk of failure in these patients. However, implants should not be placed if mucosal signs and symptoms are active.

Recently, Strietzel et al. [31] conducted a literature review published in English between 1980 and 2018 on PubMed, Medline and Embase and related to implant-prosthetic rehabilitation in patients with OLP as well as other systemic disorders. The follow-up period of the implants was  $\geq 12$  months. They found an implant survival rate in patients with OLP of 98.3% after an average follow-up period of 44.6 months, comparable to those in healthy controls. The authors concluded that the management of patients with OLP should be strict, must meet the recommendations of implant-prosthetic rehabilitation in terms of oral hygiene and maintenance. More frequent monitoring visits are recommended for these patients.

In our study, 24% stated that the presence of OLP lesions is a contraindication for implant placement.

The present study did not show a statistically significant difference in the ability to diagnose OLP between experienced dentists and recent graduates. The same observation was made by Prasad et al. [14] when they took into account the qualifications of the participants. However, the number of years of experience was significantly associated with the knowledge of dentists on some features of the OLP, including the notion of unilaterality / bilaterality of lesions ( $p = 0.034$ ) and the risk of malignant transformation ( $p = 0.031$ ). Also, specialists in Surgery or Oral Medicine had significantly more knowledge about the OLP than dentists from other specialties ( $p < 0.001$ ).

## Conclusion

OLP is a common cutaneous and mucosal dermatosis, essentially of dysimmune origin, affecting the oral cavity.

The lesions of OLP once installed in the oral cavity seem to persist there

all the life, to take the most diverse clinical forms there and evolve progressively towards a scar state of variable aspect (post-lichenian state). This post-Lichenian state carries a risk of carcinomatous evolution.

This study highlighted gaps in awareness and practical knowledge regarding the incidence, the need of early identification and of histopathology to confirm the clinical diagnosis, the perceived potential for malignant transformation, and the case management of OLP.

The questionnaire also identified the difference in diagnostic skills of the OLP between practitioners of various specialties. The reasons for this difference could be the lack of exposure to this disease during the received training.

Among the limitations of this study, we note that it was conducted in a limited geographic area with the participation of a small sample of dentists.

Given the results obtained, it would be interesting to carry out a survey at the national level, by addressing teachers and Master students in other universities in Lebanon, or even a survey of a larger number of liberal dentists.

Similarly, the development of a more comprehensive questionnaire would allow for a more accurate assessment of knowledge.

Finally, it would be interesting to offer continuing education and seminars covering oral lesions to develop dentists' knowledge and practical skills in oral pathology.

## References

- Bolognia J, Jorizzo J & Schaffer J. (2012) *Dermatology*. Philadelphia, Elsevier.
- Sachdeva S, Sachdeva S & Kapoor P. Wickham striae: etiopathogenesis and clinical significance. *Indian J Dermatol* 2011;56(4): 442–443.
- Gorouhi F, Davari P & Fazel N. Cutaneous and mucosal lichen planus: a comprehensive review of clinical subtypes, risk factors, diagnosis, and prognosis. *Scientific World Journal* 2014: 742-826.
- Lombardi T, Kuffer R. Concept actuel du lichen plan oral. Le diagnostic facile au début, peut devenir très difficile dans les lichens anciens. *Presse Méd* 2016;45(2):227-239.
- Mccartan B, Healy C. The reported prevalence of oral lichen planus: a review and critique. *J Oral Pathol Med* 2008;37(8):447-453.
- Al-Rashdan MS, Cirillo N, Mcculough M. Oral lichen planus : a literature review and update. *Arch Dermatol Res* 2016;308(8):539-551.
- Kuffer R, Lombardi T, Husson-bui C et al. Lichen plan buccal. In : KUFFER R, LOMBARDI T, HUSSON-BUI C et coll. *La muqueuse buccale de la clinique au traitement*, Paris: Medcom, 2009:77-89.
- Chbiched S, El Wady W. Lichen plan buccal. *Encycl Méd Chir (Paris), Médecine buccale* 2008 ;28-285-G-10.
- Fahri D, Dupin N. Pathophysiology, etiologic factors, and clinical management of oral lichen planus, part I: facts and controversies. *Clin Dermatol* 2010;28(1):100-108.
- Seintou A, Gaydarov N, Lombardi T, Samson J. Histoire naturelle et transformation maligne du lichen plan buccal. 1ère partie: mise au point. *Méd Buccale Chir Buccale* 2012;18(2):89-107.
- Ismail SB, Kumar SK, Zain RB. Oral lichen planus and lichenoid reactions: etiopathogenesis, diagnosis, management and malignant transformation. *J Oral Sci* 2007;49(2):89-106.
- Lysitsa S, Abi Najm S, Lombardi T, Samson J. Lichen plan buccal: histoire naturelle et transformation maligne. *Méd Buccale Chir Buccale* 2007;13(1):19-29.
- Gonzalez-Moles MA, Scully C, Gil-Montoya J. Oral lichen planus: controverses surrounding malignant transformation. *Oral Dis* 2008;14(3):229-243.
- Prasad S, Pai A, Deverashetty A, Yaji A. Knowledge and awareness regarding oral lichen planus. An analysis among dental practitioners in Bangalore. *Paripex – Indian Journal of Research* 2018;7(6): 81-84.
- Varghese SS, George GB, Sarojini SB, et al. Epidemiology of oral lichen planus in a cohort of South Indian population: A Retrospective Study. *J Cancer Prev* 2016;21(1):55-9.
- Boorghani M, Gholizadeh N, Taghavi Zenouz A, Vatankhah M, Mehdipour M. Oral lichen planus: Clinical features, etiology, treatment and management; A review of literature. *Journal of Dental Research, Dental Clinics, Dental Prospects* 2010;4(1):3-9.
- Pai A. Etiology of oral cancer revisited. *Journal of Medicine, Radiology, Pathology & Surgery* 2015;1:27–31.
- Richards D. Malignant transformation rates in Oral Lichen Planus. *Evid Based Dent*. 2018 Dec;19(4):122.
- Atzori L, Robustelli Test E, Ferreli C, Pilloni L, Rongioletti F. Impressive oral lichen planus progression to invasive squamous cell carcinoma in a three months lapse. *Oral Oncology* 2019;90:\150-152.
- Kumar SA, Krishnam Raju PV, Gopal KVT, Rao TN. Comorbidities in Lichen Planus: A Case-control study in Indian patients. *Indian Dermatol Online J*. 2019 Jan-Feb;10(1):34-37.
- Li D, Li J, Li C, Chen Q, Hua H. The association of thyroid disease and oral lichen planus: a literature review and meta-analysis. *Front Endocrinol (Lausanne)*. 2017 Nov 9;8:310.
- Martin MD, Broughton S, Drangsholt M. Oral lichen planus and dental materials: a case-control study. *Contact Dermatitis*. 2003 Jun;48(6):331-6.
- López-Jornet P, Camacho-Alonso F. Do metal restorations in mouth alter clinical and histological appearance of oral lichen planus? *N Y State Dent J*. 2008 Nov;74(6):40-3.
- Thoppay JR. Oral Lichen Planus Workup. *Drugs & Diseases*. Updated on 29 March 2018. <https://emedicine.medscape.com/article/1078327-workup>.
- Van der Meij EH, van der Waal I. Lack of clinicopathologic correlation in the diagnosis of oral lichen planus based on the presently available diagnostic criteria and suggestions for modifications. *J Oral Pathol Med* 2003;32:507-12.
- Sanketh DS, Srinivasan SR, Patil S, Ranganathan K. Issues related to diagnosing oral lichen planus among oral pathologists in South India: A pilot survey. *J Invest Clin Dent* 2017;8(4).
- Raj AT, Patil S. Diagnostic flaws in oral lichen planus and related lesions. *Oral Oncology* 2017;74:190–191.
- Resende MJP, Chaves MMD, Aarestrup FM, Aarestrup BV, Olate S, and Netto HD. Oral lichen planus treated with tacrolimus 0.1%. *Int J Clin Exp Med*. 2013; 6(10): 917–921.
- Mansourian et al. Comparison of aloe vera mouthwash with triamcinolone acetonide 0.1% on oral lichen planus: a randomized double- blinded clinical trial. *Am J Med Sci*. 2011; 342(6): 447–451.
- Petruzzi M, De Benedittis M, Cortelazzi R, Milillo L, Lucchese A, Serpico R, Grassi FR. Implant rehabilitation in patients with oral lichen planus: an overview. *Clin Oral Investig*. 2012 Oct;16(5):1347-52.
- Strietzel FP, Schmidt-Westhausen AM, Neumann K, Reichart PA, Jackowski J. Implants in patients with oral manifestations of autoimmune or muco-cutaneous diseases - A systematic review. *Med Oral Patol Oral Cir Bucal*. 2019 Mar 1;24(2):e217-e230.