

2022

## Assessment of Maximal Incisal opening using autogenous Inlay Eminoplasty Technique For Treatment Of chronic recurrent temporo mandibular joint Dislocation

mustafa abdelkawy  
Cairo University, mustafaabdelkawyy@gmail.com

Youssef Elmansi  
Military Medical Academy, yelmansy@yahoo.com

ahmed shehab  
Future University in Egypt, Afarid@fue.edu.eg

mohamed mounir  
associate professor , oral and maxillofacial surgery cairo university,  
mohamed.mounir@dentistry.cu.edu.eg

ragia mounir  
Cairo University, rmmounir@hotmail.com

Follow this and additional works at: <https://digitalcommons.aaru.edu.jo/fdj>



Part of the [Oral and Maxillofacial Surgery Commons](#)

---

### Recommended Citation

abdelkawy m, Elmansi Y, shehab a, mounir m, mounir r. Assessment of Maximal Incisal opening using autogenous Inlay Eminoplasty Technique For Treatment Of chronic recurrent temporo mandibular joint Dislocation. *Future Dental Journal*. 2022; 8(1):11-15. doi: <https://doi.org/10.54623/fdj.8012>.

This Article is brought to you for free and open access by Arab Journals Platform. It has been accepted for inclusion in Future Dental Journal by an authorized editor. The journal is hosted on [Digital Commons](#), an Elsevier platform. For more information, please contact [rakan@aarj.edu.jo](mailto:rakan@aarj.edu.jo), [marah@aarj.edu.jo](mailto:marah@aarj.edu.jo), [u.murad@aarj.edu.jo](mailto:u.murad@aarj.edu.jo).

---

## **Assessment of Maximal Incisal opening using autogenous Inlay Eminoplasty Technique For Treatment Of chronic recurrent temporo mandibular joint Dislocation**

### **Cover Page Footnote**


this is a new less morbid protocol for autogenous augmentation of the articular eminence for treatment of recurrent tmj dislocation



Contents lists available at Arab Journals Platform

Future Dental Journal

Journal homepage: <https://digitalcommons.aaru.edu.jo/fdj/>



# Assessment of Maximal Incisal Opening Using Autogenous Inlay Eminoplasty Technique For Treatment of Chronic Recurrent Temporomandibular Joint Dislocation

Mustafa Abdelkawy,<sup>a</sup> Youssef Elmansi,<sup>b</sup> Ahmed Shehab,<sup>c</sup> Mohamed Mounir,<sup>d,\*</sup> Ragia Mounir<sup>e</sup>

a. Cairo University

b. Oral and Maxillofacial Surgery, Military Medical Academy, Egypt.

c. Professor, Oral and Maxillofacial Surgery, Future University in Egypt

d. Associate Professor, Oral and Maxillofacial Surgery, Cairo University

e. Professor, Oral and Maxillofacial Surgery, Cairo University

## ARTICLE INFO

### Discipline:

Oral and Maxillofacial Surgery

### Keywords:

Temporo-mandibular joint, dislocation, eminence augmentation, eminoplasty, inlay, autogenous bone graft.

\* Corresponding author.

E-mail address:

[mohamed.mounir@dentistry.cu.edu.eg](mailto:mohamed.mounir@dentistry.cu.edu.eg)

(Mohamed Mounir)

## ABSTRACT

**Purpose:** Different surgical protocols have been introduced for eminence augmentation for treatment of recurrent temporomandibular joint dislocation. The aim of this study is to assess maximal incisal opening (MIO) using inlay (sandwich osteotomy) autogenous block augmentation harvested from patient's symphysis for more stable condylar movements. **Methods:** five patients were treated in this study (10 joints) with bilateral autogenous inlay block bone grafting technique, each autogenous cortico-cancellous bone block was harvested from chin and wedged at the created defect of the eminence through a green stick fracture to increase its height. **Results:** The follow up period ranged from six months to two years to access the maximal incisal opening (MIO), the mean preoperative maximal incisal opening was 45.8mm and that of the postoperative was 32.3 mm. One patient reported postoperative slight unilateral edema and pain that gradually diminishes after one month postoperative. Another patient showed intraoperative condylar dislocation that was treated with masseter scarification. **Conclusion:** Autogenous block interpositional eminoplasty technique is a reliable procedure for management of antero-medial recurrent condylar dislocation.

## 1. INTRODUCTION

Chronic recurrent antero-medial condylar dislocation (CRD) is a rare disorder affecting the temporomandibular joint (TMJ). There are many factors governing such condition either sudden anatomic affection in the joint supporting soft tissue components as capsule and Muscles and laxity of ligaments, or bony structures as mandibular condylar head and the articular eminence.

Another popular cause of anterior-medial condylar recurrent dislocation was the loss of harmony in the relation between the mandibular condylar movements in a 3d space and the articular eminence. Different treatment Modalities have been introduced in the literature dealing with this disturbance starting from conservative management as intermaxillary fixation using guiding elastics, injection of sclerosing agents or intra articular surgical management aiming to control the condylar path hypermobility either by creating or removing the obstacle Infront of the condylar path.

Proper diagnosis of these cases is considered the key for ideal selection of the proposed surgical management.<sup>1</sup> most of the surgical protocols altering the bony structure of the temporomandibular joint used previously for surgi-

cal treatment of condylar dislocation was technically sensitive and showed either prolonged intra operative time, donor site morbidity, or un predictable results with high rate of recurrence.<sup>2</sup> Although the development of various grafting procedures for articular eminence augmentation had various range of successful results, yet still the results is not predictable. The aim of this study was to determine the efficiency of a minimally invasive autogenous sandwich grafting technique for articular eminence augmentation in prevention of recurrent condylar dislocation.

## 2. MATERIALS AND METHODS

### Criteria of patient selection :

Five patients (10 JOINTS) were included in the study, all selected from the outpatients clinic of the Oral and Maxillofacial Surgery Department, Faculty of Dentistry, Cairo University. The patient ranged in age from 22 to 35 years, all of them were diagnosed having chronic recurrent dislocation of the temporomandibular joint treated by inlay autogenous eminoplasty with chin block graft.

Follow this and additional works at: <https://digitalcommons.aaru.edu.jo/fdj>

Part of the Dental Hygiene Commons, Dental Materials Commons, Dental Public Health and Education Commons, Endodontics and Endodontology Commons, Oral and Maxillofacial Surgery Commons, Oral Biology and Oral Pathology Commons, Orthodontics and Orthodontology Commons, Pediatric Dentistry and Pedodontics Commons, Periodontics and Periodontology Commons, and the Prosthodontics and Prosthodontology Commons

**Inclusion criteria:**

- Patient with recurrent dislocation with maximum inter incisal opening over 55mm
- Failure of conservative strategies such as orientation to self-limit jaw movement and the use of a chin-cap or bandage
- Both sexes
- Age between 18 and 48 years.
- Highly motivated patients.

Each patient was interviewed for detailed history and they were examined clinically to know the frequency of dislocation, any parafunctional habits, pain and determine the maximum inter-incisal distance (MIO) beyond which the joint is dislocated. A routine panoramic x-ray was requested to primary investigate the joint components and to exclude any foci, lesions or osteoarthritic changes of the condylar head. Patients were scheduled for C.T. scans, bone, and soft tissue windows, with slice cutting thickness 1mm and cutting interval 1mm, the machine gantry tilt is zero degrees. Upon collection, data was exported and stored in DICOM format (Digital Imaging and Communications in Medicine) and transmitted to a personal computer for review via a Compact Disk (CD), where the strategic management program was installed.

**Operative procedures**

All patients were operated under general anesthesia. After the endotracheal tube application to all the patients, scrubbing and draping were done in the standard manner, followed by intra and extra oral betadine swabbing. Periarticular region and overlying skin will be infiltrated by 2% lidocaine (20 ml lidocaine + adrenalin 1% . bone was approached via layered endural approach where the Incision was performed through the skin and subcutaneous tissues to the temporalis fascia . then exposure of The superficial layer of temporalis fascia . The superficial temporal vessels may be retracted with the skin flap or left in place .

The zygomatic arch and the lateral border of the condyle can easily be palpated at this point of the dissection. This can be facilitated by a surgical assistant manipulating the jaw. An oblique full thickness incision parallel to the temporal branch of the facial nerve was done through the superficial

layer of the temporalis fascia above the zygomatic arch. periosteal elevator was inserted under the superficial layer of the temporalis fascia and strip the periosteum off the lateral zygomatic arch. Dissection was carried inferiorly to expose the capsule of the TMJ.

The temporal branch of the facial nerve is then protected within the superficial layer of the temporalis fascia. Periosteal elevator was inserted to dissect over the superior border of the zygomatic arch till reaching the temporal bone (fig 1). Dissection of the arch anteriorly approximately 2 cm is readily performed by sub periosteal dissection. An oblique osteotomy of the eminence and a green stick incomplete fracture was carried out in a posteromedial direction to partially mobilize the articular eminence that was still pedicled to its base maintaining its blood supply.

**Graft harvest from chin:**

Local anesthesia was infiltrated intra foraminal and into the anterior mandibular vestibule and bilateral mental nerve block anaesthesia was also done ; mucosal incision was performed 1 cm labial to the vestibular depth to allow for maximum protection of the labial branch of the mental nerve that was identified and retracted laterally. Then, the mentalis muscle was then exposed and was horizontally incised, followed by subperiosteal reflection of the flap for better access of the mental foramina bilaterally as well as the inferior border of the anterior mandible. one unilateral cortical rectangle of the proposed required dimensions was marked with fine round surgical burs lateral to the symphysis menti (fig 2), extended to the canine region with a minimum safety zone of 5 millimeters beneath the apices of the mandibular incisors and canine and above the inferior mandibular border.

Fine surgical discs were used to pass and connect the drilled holes under copious saline irrigation, followed by careful tapping of fine graduated osteotomes to harvest the mono-cortical chin block graft that was sectioned into 2 blocks (fig 3) to be inserted at each articular eminence as an interpositional block graft. The chin wound was closed in layers with 4-0 polyglycolic resorbable suture (AssuCryl, Assut, Switzerland) material for the deep layers and polypropylene 5-0 (Polypropylene, Assut, Switzerland) for the skin.

The Wedge shaped block bone graft was smoothed and trimmed then inserted and tapped tightly into the interpositional created defect without any extra method of fixation. (fig 4,5)

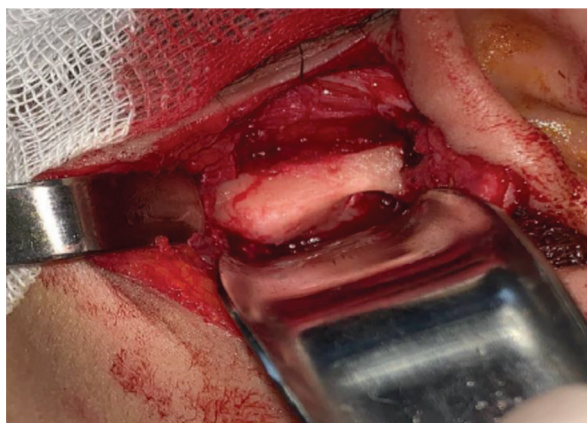


Figure (1) — Multilayer surgical exposure of the articular eminence via endural approach.

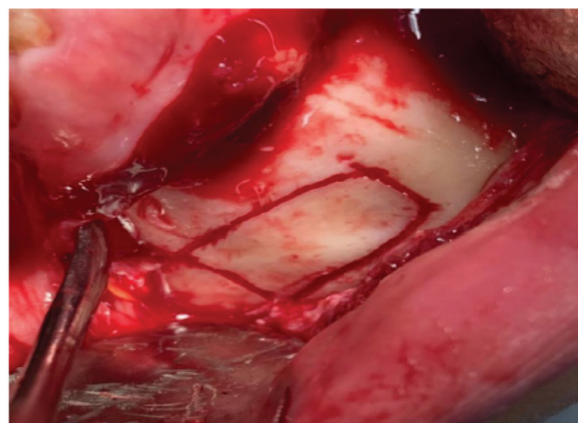


Figure (2) — Multilayer surgical exposure of the symphysis via vestibular approach and marking the block outline.

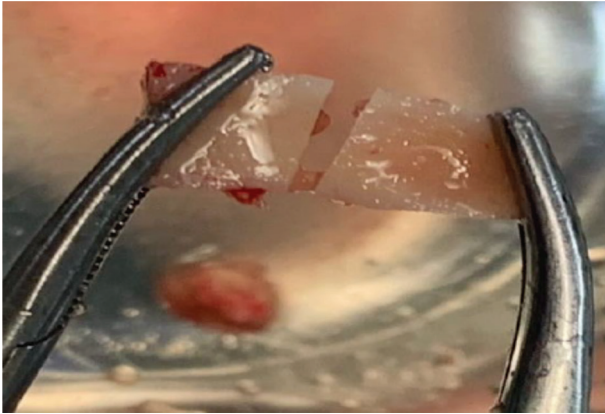


Figure (3) — Segmentation and sectioning of the harvested block , each to be inserted at the eminence bilaterally.

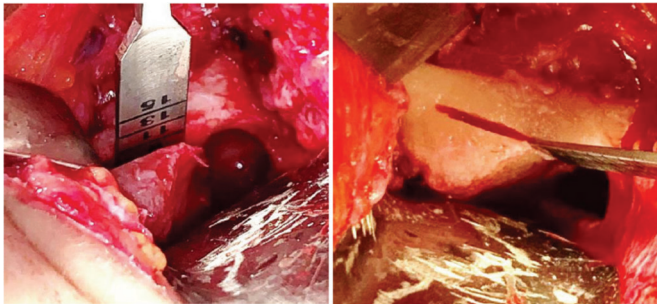


Figure (4) — Creating an incomplete osteotomy at the articular eminence bilaterally to partially down-fracture it.

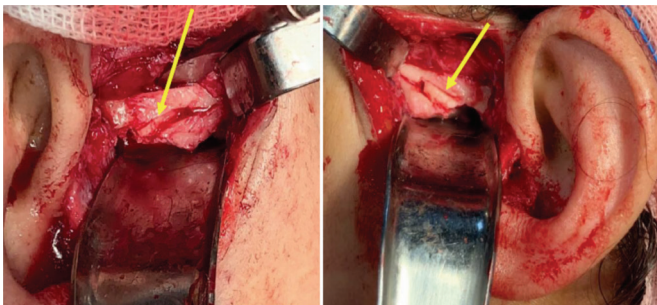


Figure (5) — The harvested symphyseal block placed at the created interpositional gap bilaterally.

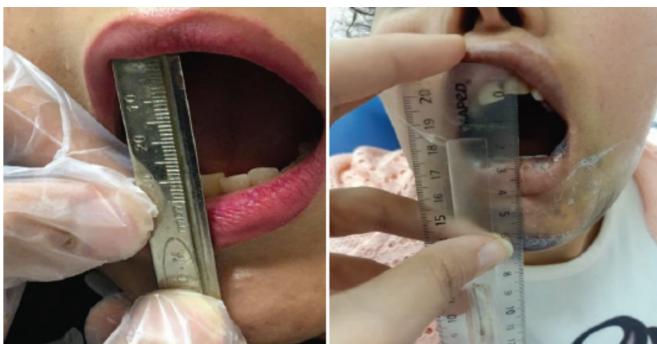


Figure (6) — The Maximal Incisal Opening pre and postoperatively.

3. RESULTS

No recurrence was found in the five cases, all the descriptive data are summarized in (table 1), the mean post operative follow up period was 24 months and the mean preoperative maximal incisal opening was 45.8 mm, and the postoperative was 32.3 mm (Table 1) (FIG 6). Only One patient reported postoperative slight b ilateral pain and edema that gradually diminishes after 3 weeks postoperatively.no post operative joint sounds, no radiographic evidence of any resorption either at the interpositional bone graft or at the mandibular condylar head or the articular eminence (fig 7).

Table 1 :

Descriptive data of all patients and maximal incisal opening (MIO) pre and post operatively.

Patient number	Gender/age	Frequency of preoperative dislocation	Postoperative Follow up period	MIO(maximal incisal opening) preo and postop.	
				Preop.	Postop.
1	Female /25	2 times / day	12 months	48.3 mm	36.8mm
2	Female /32	Once / day	12 months	49.7.mm	32.6mm
3	Male/40	2 times / day	24 months	52.4 mm	37 mm
4	Female/28	3 times / day	22 months	51.8 mm	38.3mm
5	Male/37	4 times /day	6 months	46.3 mm	30.4mm

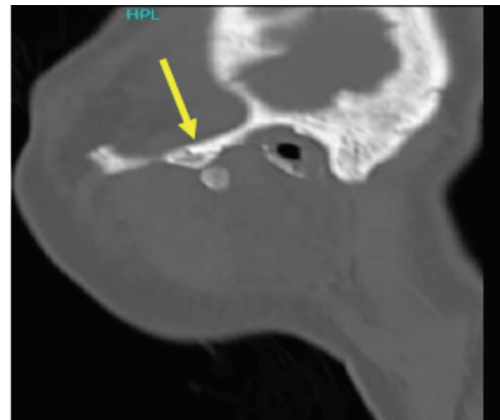


Figure (7) — 2 years postoperative c.t scan showing complete graft integration with normal condylar position during mouth opening .

4. DISCUSSION

Different modalities were used for treatment of recurrent TMJ dislocations; either by soft tissue alteration of the joint as capsuloraphy and scarification of the lateral pterygoid muscle <sup>3,4</sup>, or excision of the temporalis tendon by scarification aiming for shortening of the muscle <sup>5</sup>. Although there is variable techniques that aimed to augment the articular eminence creating an obstacle in front of the condylar path for management of recurrent dislocation, However, the results is still a matter of debate.

The eminectomy procedure was first introduced in 1951 with full removal of the articular eminence height allowing for a smooth condylar translation in a three dimensional space in all directions without any anatomical limitation,

since then, it has been widely used with acceptable results<sup>2,6,7</sup> with minimal intra operative time and with no donor site morbidity. Mayer in 1933 used the down-fracture of the zygomatic arch followed by a modification done later by Leclerc and Girard in 1943<sup>8</sup>, then by Dautrey in 1975. It depends on making an incomplete fracture at the zygomatico-temporal suture after cutting the zygomatic arch in an oblique direction posteriorly, then the posterior part is mobilized anterior and infront the articular eminence to hinder the condylar movements. the technique used in our case series study is simpler and easier than that used by Lerec and Girard with better long term results concerning the recurrence where the Dautrey technique not only associated with high rate of recurrence but also<sup>9,10</sup> resorption of the mobilized bony segment. failure of dautrey technique could be also due to the presence of a small condylar dimensions that could still be displaced infront of the down-fractured portion<sup>11</sup>.

Miniplates eminoplasty was also another less morbid technique depending on placement of miniplates fixed to the lateral aspect zygomatic arch was a trial to hinder the mediolateral condylar displacement<sup>12-14</sup> however; plate fracture was the most popular reported complication in some cases<sup>15</sup>. Eminence augmentation techniques were the second most used protocols after eminectomies, an oblique osteotomy creating a green stick fracture starting backwards and extended to the medial direction followed by gentle tapping using surgical mallet resulting in an incomplete separation of the segment anteriorly and a gap caudally, then an interpositional graft was inserted such as hydroxyapatite, or autogenous bone harvested from the chin, iliac crest or the calvaria<sup>11,16,17</sup>.

In this study, the autogenous block bone graft harvested from the mandibular symphysis was the choice due to its proximity to the recipient site, minimal donor site morbidity and its intramembranous nature for better graft consolidation. One of the advantages of using interpositional bone grafting of the eminence is not only the maintained blood supply to the graft at the created defect but also the difficulty of graft reshaping and fixation together with expected resorption if it was placed as an onlay bone graft.

Bad-splits or even complete separation of the eminence due to bone brittleness specially at the old age together with the donor site morbidity due to autogenous graft harvesting that could occur were considered the most popular intraoperative complications associated with this type of joint open surgeries. many fixation methods to the interpositional graft had been introduced as a wire osteosynthesis or fixation with micro screws. In this study no extra fixation method for the interpositional block was done depending on the primary stability of the wedged bone graft with no added means of fixation. The key point is the medial extension of the wedged block graft that prevent the medial escape of mandibular condyle. antero-medially.

Xu C et al<sup>18</sup> In 2019 reviewed the different eminence augmentation procedures., they have treated 2 (67 and 69 years old) patients with chronic dislocations whom were treated by computer guided surgical technique, They concluded that the modified cad-cam technique had a great advantage with highly accurate cutting guides over the previously discussed techniques at the literature.

In 2020, Ihab et al<sup>19</sup> performed a study to control the antero medial condylar dislocation using a customized onlay patient specific implant as a more accurate, less morbid protocol of eminence augmentation, authors stated that there was no direct relation between the amount of vertical eminence augmentation and the the postoperative Maximal Incisal Opening (MIO) as it is a case dependent. The same authors conducted another study at the same year<sup>20</sup> comparing the interpositional augmentation of the articular eminence with the patient specific onlay titanium implants, results of their study showed that there was no statistical significant difference between both groups.

In all of the five cases, the autogenous sympheseal blocks were snugly fitted to the created interpositional gap at the native eminence, with no signs

of intraoperative antero medial dislocation over the augmented eminence except in one case who was treated with masseter scarification through and intra oral vestibular approach at the posterior mandible with post operative inter maxillary fixation for ten days.

## 5. CONCLUSIONS

In the present study After two years of follow up period showed stable and repeatable condylar movements with no recurrence and no condylar head changes suggesting that this technique could be a good alternative for eminence augmentation protocols used for treatment of recurrent TMJ dislocation.

## Compliance with ethical standards:

Competing interests : the authors declare that they have no conflict of interest

Patient consent: patient consent have been obtained

## 6. REFERENCES

1. Guarda-Nardini L, Palumbo B, Manfredini D, Ferronato G. Surgical treatment of chronic temporomandibular joint dislocation: A c2008) *Oral Maxillofac Surg*;12(1):43-46. doi:10.1007/s10006-008-0097-5
2. Sato J, Segami N, Nishimura M, Suzuki T, Kaneyama K, Fujimura K. Clinical evaluation of arthroscopic eminoplasty for habitual dislocation of the temporomandibular joint: Comparative study with conventional open eminectomy. (2003) *Oral Surg Oral Med Oral Pathol Oral Radiol Endod*. 2003;95(4):390-395. doi:10.1067/moe.2003.128
3. Sindet-Pedersen S. Intraoral myotomy of the lateral pterygoid muscle for treatment of recurrent dislocation of the mandibular condyle. (1988) *J Oral Maxillofac Surg*;46(6):445-449. doi:10.1016/0278-2391(88)90409-0
4. Laskin DM. Myotomy for the management of recurrent and protracted mandibular dislocations.(1973) *Trans Int Conf Oral Surg*;4:264-268.
5. Gould JF. Shortening of the temporalis tendon for hypermobility of the temporomandibular joint(1978). *J Oral Surg*. ;36(10):781-783.
6. Helman J, Laufer D, Minkov B, Gutman D. Eminectomy as surgical treatment for chronic mandibular dislocations. (1984) *Int J Oral Surg*;13(6):486-489. doi:10.1016/S0300-9785(84)80018-6
7. Myrhaug H. A new method of operation for habitual dislocation of the mandible.-review of former methods of treatment. (1951) *Acta Odontol Scand*;9(3-4):247-261. doi:10.3109/00016355109012789
8. LECLERC GC, GIRARD C. [Long-term results in 4 cases of recurrent dislocation of the mandible operated on by the Leclerc and Girard method].(1958) *Mem Acad Chir (Paris)*;84(14-15):420-421.
9. Ying B, Hu J, Zhu S. Modified Leclerc blocking procedure with miniplates and temporal fascial flap for recurrent temporomandibular joint dislocation. (2013) *J Craniofac Surg*;24(3):740-742. doi:10.1097/SCS.0b013e3182802441
10. Lawlor MG. Recurrent dislocation of the mandible: treatment of ten cases by the Dautrey procedure.(1982) *Br J Oral Surg*;20(1):14-21. doi:10.1016/0007-117X(82)90002-6
11. Ldpez AC, Gil FM, Sanromfn JF, Adame CG, Ruiz PC. Glenotemporal osteotomy as a definitive treatment for recurrent dislocation of the jaw. (1996):178-183.
12. Cavalcanti JR, Vasconcelos BC, Porto GG, Carneiro SCAS, Do Nascimento MMM. Treatment of chronic mandibular dislocations using

- a new miniplate. (2011) *Int J Oral Maxillofac Surg*;40(12):1424-1427. doi:10.1016/j.ijom.2011.04.019
13. Bakardjiev A. Treatment of chronic mandibular dislocations by bone plates: Two case reports.(2004) *J Cranio-Maxillofacial Surg*.;32(2):90-92. doi:10.1016/j.jcms.2003.09.010
  14. Vasconcelos BC do E, Porto GG. Treatment of Chronic Mandibular Dislocations: A Comparison Between Eminectomy and Miniplates (2009). *J Oral Maxillofac Surg*.;67(12):2599-2604. doi:10.1016/j.joms.2009.04.113
  15. Vasconcelos BC, Porto GG, Lima FTB. Treatment of chronic mandibular dislocations using miniplates: follow-up of 8 cases and literature review. ( 2009) *Int J Oral Maxillofac Surg*.;38(9):933-936. doi:10.1016/j.ijom.2009.04.013
  16. Gu O. A Clinical Study on Treatment of Temporomandibular Joint Chronic Recurrent Dislocations by a Modified Eminoplasty Technique:1275-1280.
  17. Medra AM, Mahrous AM. Glenotemporal osteotomy and bone grafting in the management of chronic recurrent dislocation and hypermobility of the temporomandibular joint. (2007) *Br J Oral Maxillofac Surg*. 2008;46(2):119-122. doi:10.1016/j.bjoms..08.004
  18. Xu C, Liu H, Du W, Wang Y, Hu J, Luo E1. Computer-Aided Design and Computer-Aided Manufacturing Cutting Guides in Eminoplasty for the Treatment of Temporomandibular Joint Dislocation. (2019) *J Craniofac Surg*. Mar/Apr;30(2):541-547.
  19. Ihab R, Mounir R, Mounir M. Patient Specific Titanium Onlay Eminoplasty (PSTOE): A Novel Protocol for treatment of recurrent temporomandibular joint Dislocation. (2020): *Int J Med Robot*. Apr 17:e2114
  20. Rania Ihab<sup>1</sup>, Ragia Mounir<sup>2</sup>, Sherif Ali<sup>2</sup>, Mohamed Mounir<sup>2</sup> Assessment of patient-specific titanium onlay versus autogenous inlay eminoplasty technique for treatment of recurrent temporomandibular joint dislocation: a randomized clinical trial, *Oral Maxillofac Surg*. 2020 Dec;24(4):411-415