

5-2-2022

The bisection: still a reliable treatment option of the first mandibular molar: A 3 years follow up case report

Rahma BOUNAOUARA

Amel LABIDI

Sana BEKRI

Sameh RZIGUI

Lamia MANSOUR

Follow this and additional works at: <https://digitalcommons.aaru.edu.jo/iajd>

Recommended Citation

BOUNAOUARA, Rahma; LABIDI, Amel; BEKRI, Sana; RZIGUI, Sameh; and MANSOUR, Lamia (2022) "The bisection: still a reliable treatment option of the first mandibular molar: A 3 years follow up case report," *International Arab Journal of Dentistry*. Vol. 13: Iss. 1, Article 5.

Available at: <https://digitalcommons.aaru.edu.jo/iajd/vol13/iss1/5>

This Original Article is brought to you for free and open access by Arab Journals Platform. It has been accepted for inclusion in International Arab Journal of Dentistry by an authorized editor. The journal is hosted on [Digital Commons](#), an Elsevier platform. For more information, please contact rakan@aarj.edu.jo, marah@aarj.edu.jo, u.murad@aarj.edu.jo.

THE BISECTION: STILL A RELIABLE TREATMENT OPTION OF THE FIRST MANDIBULAR MOLAR: A 3 YEARS FOLLOW UP CASE REPORT

Rahma Bounaouara* | Amel Labidi** | Sana Bekri*** | Sameh Rzigui**** | Lamia Mansour*****

Abstract

Conservation of mandibular molar teeth exhibiting furcation involvement and perforation of the pulp floor have always been a challenge. Section of the affected tooth at the furcation zone, and preservation of the mesial and distal roots individually with its crown portion, helps to preserve the tooth structure, alveolar bone and avoids sacrificing a strategic tooth. Therapeutic planning is multidisciplinary. It contains surgical, endodontic and prosthetic phase. Long-term success depends on thorough diagnosis and careful selection of cases.

This article describes a simple procedure for bisection in mandibular molar. This is illustrated by a clinical case while detailing the entire operative sequences of bisection procedure.

Key words: bisection; mandibular molar; conservative approach

IAJD 2022;13(1): 36-41.

LA BISECTION: UNE OPTION TOUJOURS FIABLE DE TRAITEMENT DE LA PREMIÈRE MOLAIRE MANDIBULAIRE: À PROPOS D'UN CAS CLINIQUE AVEC 3 ANS DE SUIVI

Résumé

La conservation des molaires mandibulaires présentant une atteinte des furcations et une perforation du plancher pulpaire a toujours été un défi. La section de la dent affectée au niveau de la zone de furcation, et la préservation des racines mésiales et distales individuellement avec sa partie couronne, permet de préserver la structure dentaire, l'os alvéolaire et évite de sacrifier une dent stratégique. La planification thérapeutique est multidisciplinaire. Elle contient une phase chirurgicale, endodontique et prothétique. Le succès à long terme dépend d'un diagnostic approfondi et d'une sélection minutieuse des cas. Cet article décrit une procédure simple pour la bissection dans la molaire mandibulaire. Ceci est illustré par un cas clinique tout en détaillant l'ensemble des séquences opératoires de la procédure de bissection.

Mots clé: bissection, molaire mandibulaire, approche conservatrice

IAJD 2022;13(1): 36-41.

* University of Monastir, Faculty of Dental Medicine, Laboratory of Biological, Clinical and Dento-Facial Approach LR12ES10, Avicenna Avenue 5000, Monastir, Tunisia . Email: rahma.bounaouara.11@gmail.com

** University of Monastir, Faculty of Dental Medicine, Laboratory of Biological, Clinical and Dento-Facial Approach LR12ES10, Avicenna Avenue 5000, Monastir, Tunisia . Email: amellabidi16@yahoo.fr

*** Sana Bekri: University of Monastir, Faculty of Dental Medicine, Laboratory of Biological, Clinical and Dento-Facial Approach LR12ES10, Avicenna Avenue 5000, Monastir, Tunisia. Email: sanabekri2015@gmail.com

**** Sameh Rzigui: University of Monastir, Faculty of Dental Medicine, Laboratory of Biological, Clinical and Dento-Facial Approach LR12ES10, Avicenna Avenue 5000, Monastir, Tunisia . Email: samehrzigui@gmail.com

***** University of Monastir, Faculty of Dental Medicine, Laboratory of Biological, Clinical and Dento-Facial Approach LR12ES10, Avicenna Avenue 5000, Monastir, Tunisia . Email: mansourlamia64@yahoo.fr

Introduction

The first mandibular molar can be damaged by periodontal disease, caries or accidents during endodontic treatment. In some clinical cases, extraction is not the only treatment that could be planned. Tooth resection procedures can be used as a conservative option to preserve this tooth which constitutes the major standpoint for occlusion[1]. Various resection procedures were described in the literature[2-6]: hemisection, root amputation, radisection and bisection known also as bicuspidization,

They are all surgical procedures whose purpose is to remove or separate the roots of a multi-rooted tooth. The difference between these concepts is the portion affected by the surgery. Hemisection is the separation and removal of a root with its coronal part, while radisection is a procedure that concerns the extraction of the roots of the maxillary molars and root amputation is the removal of one or more roots without touching the coronal part [2,4]. Root amputation generally concerns mandibular molars, whereas preservation of the crown is only exceptionally used for upper premolars because of the very apical situation of the furcation.

These 3 procedures present the same clinical indications:

Severe vertical bone loss involving only one root of multi-rooted teeth, unfavorable proximity of roots of adjacent teeth, preventing adequate hygiene maintenance in proximal areas, severe root exposure due to dehiscence, vertical fracture traverses one root while the other roots are unaffected, and finally a perforation of pulp canal of one of the roots of an endodontically involved tooth which cannot be instrumented. [2]

For these procedures, there has been a conservation of the other roots of the teeth.

However, in bisection, all portions of the tooth are preserved, just separating the multi-rooted tooth into two parts, mesial and distal. The separation concerns both the root and the

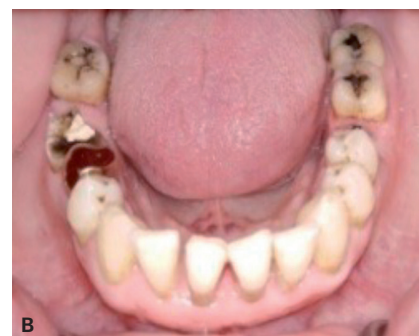
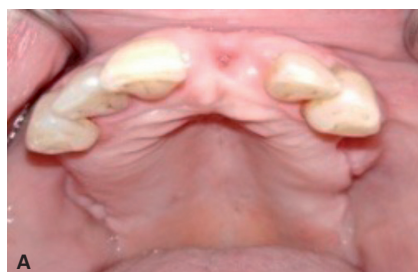

Figure 1 : Clinical situation at baseline

A- Pre-treatment maxillary occlusal view.
B- Pre-treatment mandibular occlusal view.

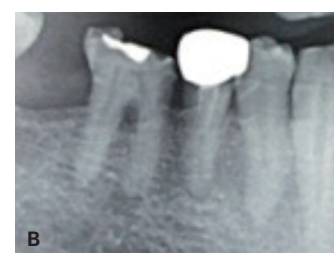
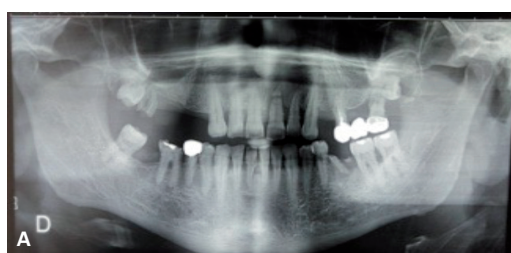

Figure 2: Pre-Operative radiographs

A- Panoramic radiograph
B: radiograph of 46

crown [2,6]. This procedure is useful in case of perforation through the floor of the pulp chamber and through furcation destruction.

All these procedures can be considered as a valid treatment when the cases are selected appropriately. Thus, an evaluation of the prognosis of the tooth on the periodontal, endodontic and prosthetic plan is necessary[7].

Knowledge of the different indications of tooth resection guides the practitioner in the choice of the appropriate procedure for the clinical case. [3].

-The aim of this clinical report was to illustrate a case of bisection of a mandibular molar to conserve a strategic tooth and respond to the prosthetic needs of the patient.

Case Report

A 68-year-old patient consulted the prosthetic department for replacing his missing teeth. The clinical examination shows a bilateral maxillary terminal edentulous with absence of the 21. In the mandible all the teeth were

present except the 47 and the 36. (Fig 1, A et B)

The 46 has a decay underneath a defective coronal filling and a Class I of Miller furcation pathology (Fig 2). The 48 was not acceptable as an abutment tooth because it presented an important version and there is an insufficient prosthetic space above.

This has been diagnosed after mounting the study models in articulator and the materialization of the prosthetic project. The conservation of the 48 imposes to sacrifice more than half of the crown to restore the occlusion plane moreover this tooth has no antagonist so it was decided to extract the 48 and to stop the occlusion at the level of the 46.

A ceramic bridge fused to metal replacing the 36 and a metal crown on the 46 were planned.

The prosthetic decision in the maxilla was to make a metal-ceramic bridge from canine to canine to replace the 21 and a removable partial denture with metal frame replacing the posterior teeth.

Clinical Case | Cas clinique

-During the root canal treatment of the 46, there was a perforation of the pulp floor occurred (Fig 3A). The root canals were closed by the lateral condensation method and the chamber was filled with glass ionomer to maintain a good seal (Fig 3B and Fig4A)

An adequate amount of attached gingiva was noticed. In order to preserve this strategic tooth, bisection of the 46 was indicated. The treatment plan was discussed with the patient and his written consent was obtained regarding the treatment and its further publication.

The surgical phase:

Under local anesthesia, a full thickness flap was reflected. On the vestibular side, the detachment stopped at the muco-gingival line. The granulation tissue was removed with curettes till the bone exposure. The furcation zone became quite evident (Fig 4 B, C).

-The mesial and distal roots were sectioned at the level of the furcation using a Zékrya stone® bur (Fig 4D).

-A radiograph was taken at this point in order to evaluate the remaining furcation tooth structure (Fig5 A). It had to be checked that there was no persistent beak at the furcation that may hinder healing. This horizontal concavity was eliminated by using the same bur at the furcation with a buccal-lingual movement. Finally, the flap was closed (fig4 F). The sutures were removed 10 days later (Fig 5 B).

Prosthetic phase:

-At a follow-up appointment 2 months after the surgery, the healing was completed and the tooth had a good bone support (Fig 6A). At this stage, each segment of the tooth was satisfactory to be used as an individual abutment for fixed prosthesis to restore the masticatory function.

-The tooth preparation was performed using a diamond bur long enough to penetrate both the roof of the furcation chamber and the occlusal portion of the tooth, and narrow enough to avoid excessive removal of tooth structure above the furcation.

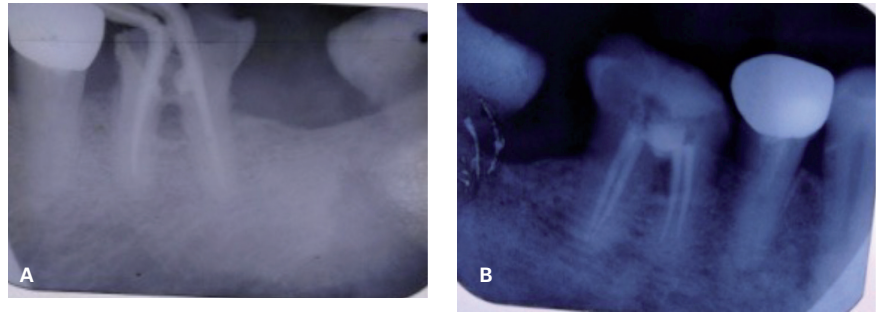
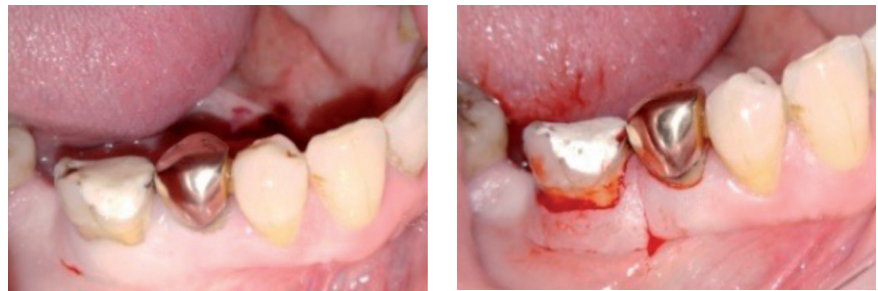

Figure 3 :Endodontic treatment

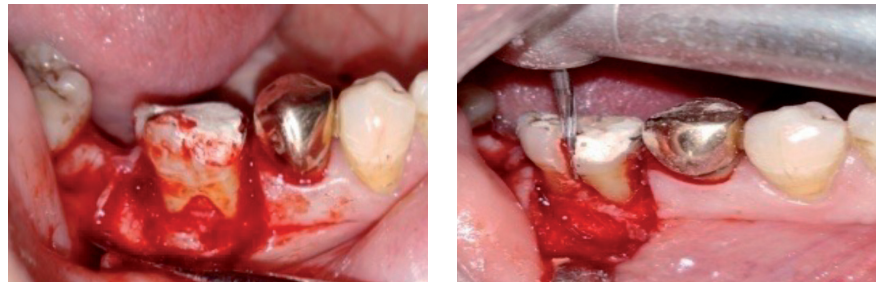
A: Radiograph showing a class I furcation pathology and a perforation of the pulp floor after a pulpectomy

B: Radiograph after endodontic therapy



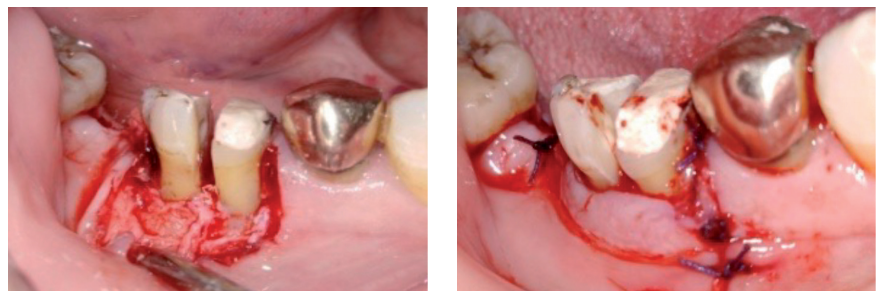
A: Pre-Operative view

B: Local anesthesia and incision



C: A mucoperiosteal flap was raised

D: Section of the mesial and distal roots at the furcation zone



E: Hemisected tooth

F: Sutures placed

Figure 4: Section surgery

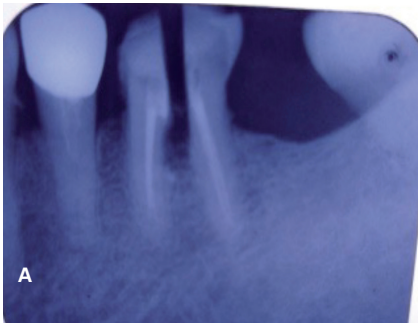
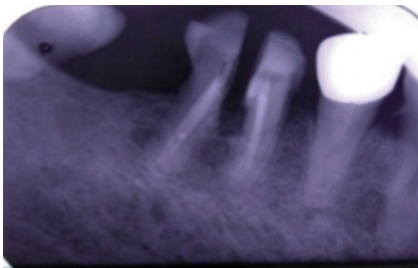
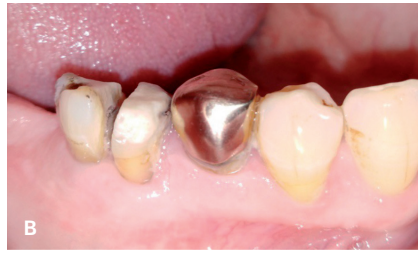

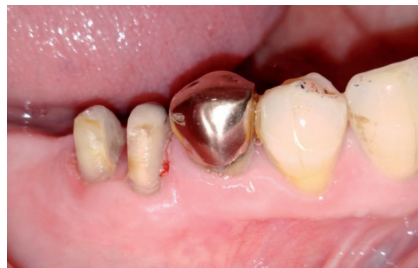Figure 5 : Post operative result

A : Radiograph showing the section of mesial and distal roots

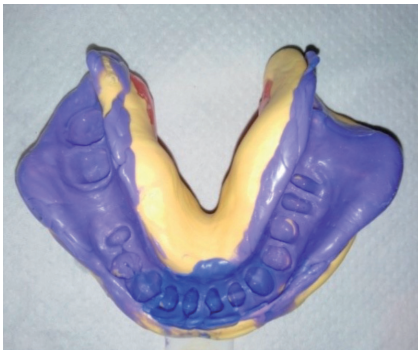B: Bisected tooth 10 days after surgery



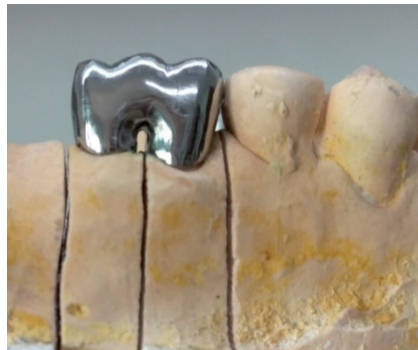A :Radiograph 2 months later



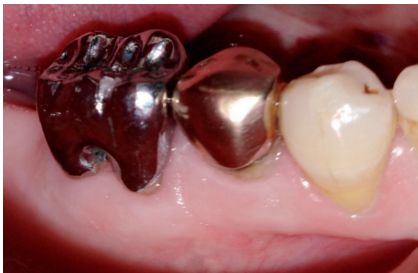B : Crown preparation



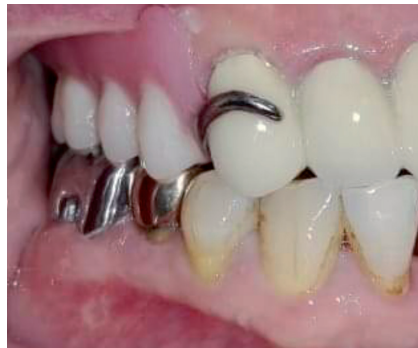C: Final impression



D :Metal crown conception



E : fixed prosthesis in place
(6 months after surgery)



F :Post operative view with fixed prosthesis
in occlusion

Figure 6 : The prosthetic phase

The finish line was placed at the juxta gingival level (Fig 6 B).

- The provisional prosthesis was made. It served as a guide for healing and the design of the gingival contour. The embrasure was widened enough for self-maintenance. The tenets of plaque control were possible effectively in the furcation zone.

- Final impression was made with high and medium viscosity silicone (Fig6C) and the master cast was derived from the casting of this impression. Opposing teeth were mounted in an articulator and interocclusal records were sent to the laboratory.

- Wax pattern was fabricated. Metal restoration was casting using standard techniques (Fig 6 D). This type of prosthesis was chosen to avoid a mutilating preparation which imposes the ceramic crown and weakens the tooth.

Occlusion was checked with articulating paper. Final prosthesis was cemented using glass ionomer cement (Fig 6 E, F).

The patient was instructed regarding oral hygiene and the use of interproximal brushes in the furcation zone.

Patient was followed up to 30 months later. He was very satisfied with the efficiency of the masticatory function. On clinical examination, the prosthesis has a good cervical adaptation, without any periodontal alteration. (Fig7)

Discussion

For this clinical case, the bisection of the mandibular molar was a conservative procedure because the extraction of this tooth would have led to a terminal edentation that would have required a implant placement or a removable prosthesis [9].

However, roots bisection was an alternative treatment that was proposed and discussed with the patient

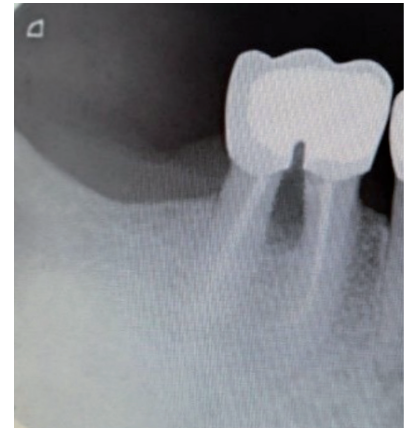
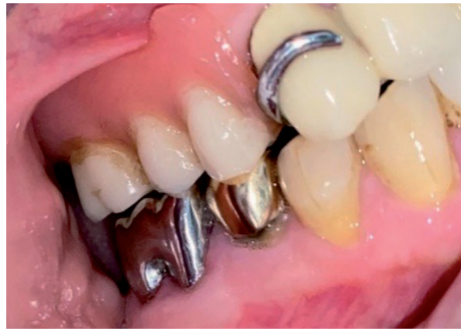
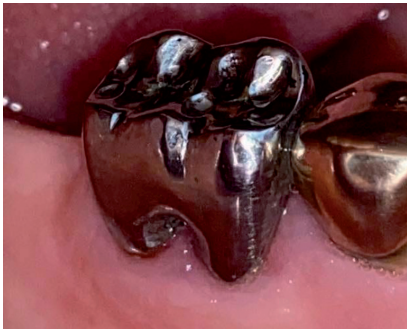Figure 7: Clinical and radiological evaluation 30 months later

in addition to extraction and implant therapy [10].

This surgical procedure was indicated after a thorough diagnosis and a careful selection of the case. Periodontal, prosthodontics, and endodontic prognosis were important and were taken into consideration.

From a periodontal perspective, bisection is indicated in case of class III furcation damage. In addition it has endodontic and restorative indications such as accidents during endodontic treatment like perforation of the pulp floor of a multi-rooted tooth [2].

In the literature, several studies have shown the long-term success of this procedure. The failure rate of this procedure was evaluated by Buhler et al and Blomlof et al. to 32% at 10 years. [1,3].

In the present case, the first mandibular molar has a class I furcation pathology and a perforation of pulpal floor after a pulpectomy. Bisection was indicated to restore an endodontically compromised tooth.

-This tooth was transformed in 2 premolars that were restored with a modified fixed denture design. Each stage of treatment must be performed adequately.

Long term success depends on following surgical, endodontic and prosthetic guidelines:

Prior to tooth sectioning, an endodontic treatment should be performed with a tight root canal filling. The access cavity has to be sealed with glass ionomer. Amalgam should be avoided because it affects healing if they become lodged in the socket during bisection [9,10].

After root separation, the furcation embrasure should be cleared to facilitate proper cleaning of this area and avoid plaque accumulation [10].

For the prosthetic phase, the points to consider when fabricating the prosthesis are as follow: the restoration may contribute to periodontal destruction if the marginal or occlusal surfaces are defective and do not respect a physiological shape essentially in the furcation area [1].

The occlusal tables should have a smaller size. Thus, an inadequately shaped occlusal contact zone induces destructive occlusal forces leading to failure of bisection [1,7].

Two therapeutic choices were made in our case: bisection or extraction with the placement of an implant. Our choice was oriented towards bisection due to the motivation and cooperation of our patient. We counted on good therapeutic maintenance. In fact, postoperative maintenance is certainly essential for a good prognosis of a resection treatment.

Maybe a period of 3 years is not enough to give a reliable estimate of the prognosis of the bisection but it remains a therapeutic alternative more conservative and financially more economical than implant for the patient.

In conclusion, root resection can be a successful solution for perforation of the mandibular molar's pulp floor. Long-term complications with bisection are not rare but can be reduced if endodontic, surgical and prosthetic steps are conducted properly [7].

Conflict of interest: None

References

1. Radke U, Kubde R, Paldiwal A. Hemisection: a window of hope for freezing tooth. *Case Rep Dent*. 2012;2012:390874.
2. Parmar G, Vashi P. Hemisection : A case-report and review. *Endodontology*. 2003;15: 26-29.
3. Samir S, BhaveshM ,Khushboo D , Sareen D. Hemisection – A Conservative Approach for a Periodontally Compromised Tooth: A Case Report . *Journal of Advanced Oral Research*. 2012; 3(2):21-25.
4. Mohammad KS,Asaad J, SaadiaA.Hemisection: an option to treat apically fractured & dislodged part of a mesial root of a molar. *Journal of the Pakistan Dental Association*. 2011; 20(3) :183-186
5. Kurtzman GM,Mahesh L, Qureshi I. Hemisection as an alternative treatment for the vertically fractured mandibular molar. *Journal of the Pakistan Dental Association*. 2012; 21(03) :177 – 181
6. Jain A, Rachana B, VineetA. Hemisection as an Alternative Treatment for Resorbed Multirooted Tooth - A Case Report. *Asian Journal of Oral Health & Allied Sciences*. 2011 ;1(1):42-46.
7. Hrushikesh N, Saurabh C, Mudita C, Tanuja D. Hemisection as an Alternative Treatment for Decayed Multirooted Abutment: A Case Report. *Journal of Dental and Medical Sciences*.2013;7 (4): 32-36
8. Zafiropoulos GG, Hoffmann O, Kasaj A, Willershausen B, Deli G, Tatakis DN. Mandibular molar root resection versus implant therapy: a retrospective nonrandomized study. *J Oral Implantol*. 2009;35(2):52-62.
9. Pai AR, Babu VM, Kundabala M. The role of hemisection in the prosthetic management of a distal extension ridge—a case report. *Dent Update*. 2014; 41(6):514-6.
10. Saad MN, Moreno J, Crawford C. Hemisection as an alternative treatment for decayed multirooted terminal abutment: a case report. *J Can Dent Assoc*. 2009;75(5):387-90.