

5-2-2022

Hybrid implant supported prosthesis: Transfer of prosthetic data to the laboratory. 4 clinical cases

Jihad FAKHOURI

Maha DAOU

Elyssia INATY

Nada EL OSTA

Follow this and additional works at: <https://digitalcommons.aaru.edu.jo/iajd>

Recommended Citation

FAKHOURI, Jihad; DAOU, Maha; INATY, Elyssia; and EL OSTA, Nada (2022) "Hybrid implant supported prosthesis: Transfer of prosthetic data to the laboratory. 4 clinical cases," *International Arab Journal of Dentistry*. Vol. 13: Iss. 1, Article 6.

Available at: <https://digitalcommons.aaru.edu.jo/iajd/vol13/iss1/6>

This Original Article is brought to you for free and open access by Arab Journals Platform. It has been accepted for inclusion in International Arab Journal of Dentistry by an authorized editor. The journal is hosted on [Digital Commons](#), an Elsevier platform. For more information, please contact rakan@aar.edu.jo, marah@aar.edu.jo, u.murad@aar.edu.jo.

HYBRID IMPLANT SUPPORTED PROSTHESIS: TRANSFER OF PROSTHETIC DATA TO THE LABORATORY. 4 CLINICAL CASES

Jihad Fakhouri* | Maha Daou** | Elyssia Inaty*** | Nada el Osta****

Abstract

Purpose: The transfer of data to the laboratory remains the key to the success of hybrid implant supported prosthesis.

The impression represents the preliminary step of this procedure. It is important to establish a protocol that is appropriate to the clinical situation from implant placement to insertion of the prosthesis into the mouth.

Materials and Methods: This article develops 4 case reports, each with a different recording procedure.

Results: Plaster remains the material of choice when precision is required. The Novum system has the advantage of not requiring an impression but its indication remains very limited.

Keywords: Impression, hybrid prosthesis, Novum system, Trefoil system, Plaster

IAJD 2022;13(1): 42-48.

PROTHÈSES HYBRIDES SUR IMPLANT: TRANSFERT AU LABORATOIRE DES DONNÉES PROTHÉTIQUES. A PROPOS DE 4 CAS CLINIQUES

Résumé

Objectif: Le transfert des données au laboratoire reste la clé du succès de la construction prothétique d'une prothèse hybride implanto-portée.

L'empreinte représente l'étape préliminaire de cette construction. Il est important d'établir un protocole approprié à la situation clinique depuis la pose d'implants jusqu'à l'insertion de la prothèse en bouche.

Matériels et méthodes: Cet article développe 4 cas cliniques avec pour chacun une procédure d'enregistrement différente.

Résultat: Le plâtre reste le matériau de choix lorsqu'une précision est requise. Le Novum système a l'avantage de ne pas nécessiter d'empreinte mais son indication reste très limitée.

Mots clés : Empreinte, prothèse hybride, Novum système, Trefoil système, Plâtre

IAJD 2022;13(1): 42-48.

* DMD, MSc, PhD, Associate Professor, Department of Removable Prosthodontics, School of Dentistry, Saint Joseph University, Beirut, Lebanon.
Jihad.fakhouri@usj.edu.lb

** DMD, MSc, PhD, Associate Professor in Dental Materials, School of Dentistry, Saint Joseph University, Beirut, Lebanon.
maha.daou@usj.edu.lb

*** DMD, MSc, Private practice
elyssia.in@gmail.com

**** DMD, MSc, PhD, Clinical Professor, Department of Removable Prosthodontics, School of Dentistry, Saint Joseph University, Beirut, Lebanon.
nada.osta@usj.edu.lb

Introduction

The elaboration of a hybrid implant supported prosthesis requires the development of a provisional prosthesis for a few months pending the osseointegration phase. During this period, immediate loading of the provisional prosthesis will be recommended provided that the primary stability of all implants is ensured.

On the other hand, a definitive loading of the prosthesis will be postponed pending the time necessary for the good osseointegration of the implants and this will depend on the surgical phase. [1,2] When the primary stability of all implants is ensured, the provisional prosthesis, previously designed according to conventional standards, will be connected to the implants on the same day of the implant placement and the prosthesis will be adjusted to allow proper hygiene during the bone healing phase (4 to 6 months).

In the opposite case, and when at least one of the implants presents a primary stability problem, the implants will be submerged and the provisional prosthesis will be placed later when the time is right. [2]

When the final impression is indicated, after the temporization phase, the technique must be adapted to the clinical context: the prosthetic state of the opposing maxillary, the volume and the height of the available prosthetic space, the amplitude of the mouth opening, the physiology of the patient (gag reflex, tics, allergies, intolerances ...). [3, 4]

The transfer of data to the laboratory is based on the choice of transfer methods. The basic criteria are the type of impression tray, the choice of the impression material and the three-dimensional occlusal registration techniques.

Four clinical cases of implant-retained hybrid prosthesis will be discussed in this article. In each of the cases described, the impression technique is different as well as the materials used.

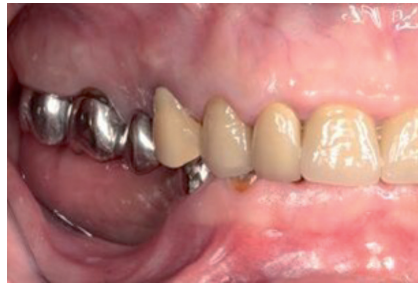

Figure 1: Right side

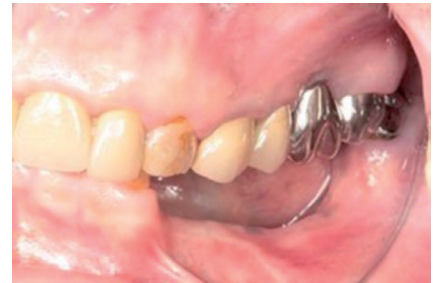

Figure 2: Left side

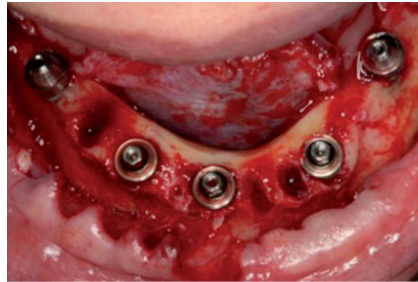


Figure 3: 5 implants placement

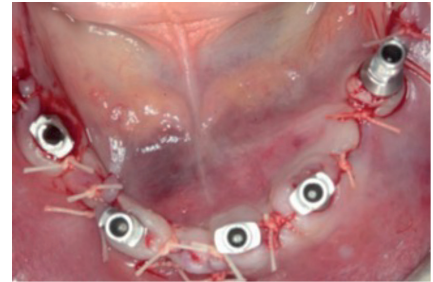


Figure 4: Screwing of 5 impression coping

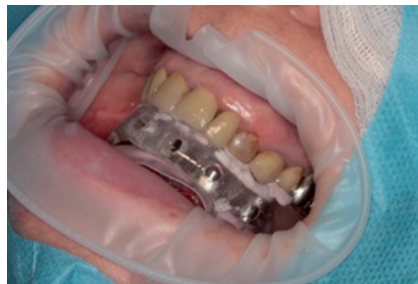

Figure 5: Duplicate fitting

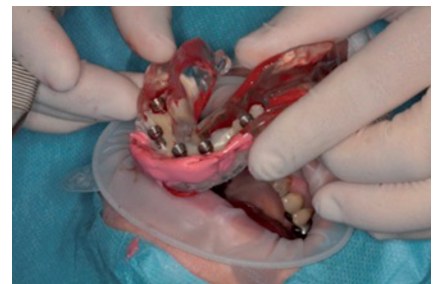

Figure 6: Impression using acrylic resin

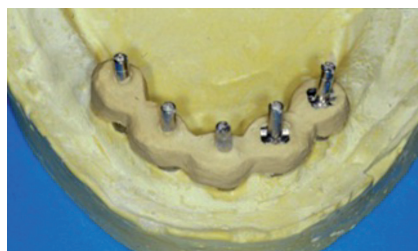

Figure 7: Plaster key

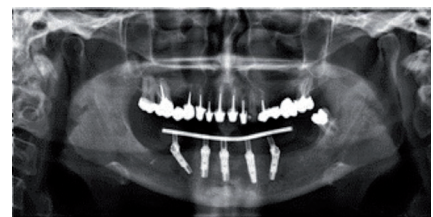


Figure 8: Radiological control

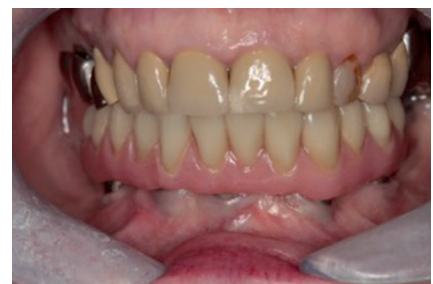

Figure 9: Prosthesis insertion

Case report 1:

A patient presented with an extraction plan of the remaining teeth in the mandible and the placement of 5 implants (Branemark system - Nobel Biocare Göteborg, Sweden). (Fig 1, 2)

After the extraction, 5 implants were placed. On the head of each implant, a straight multiunit is screwed. (Fig 3)

Impression copings were screwed on multiunits and sutures were performed. (Fig 4)

The duplicate of the previously designed total mandibular prosthesis was perforated facing each transfer. (Fig 5)

A rubber dam is placed to protect the sutures. After the duplicate is inserted, we asked the patient to close in occlusion. Through the holes, cold acrylic resin was injected. The duplicate was then removed and the stability of the impression copings was verified. (Fig 6)

After pouring the impression, a verification plaster key will check its accuracy. (Fig 7)

After validation, a bar that connects multiunits is performed, tested in the mouth and verified after radiological control. (Fig 8)

Then laboratory steps will lead to the fabrication of the prosthesis and finally its insertion. (Fig 9)

Case report 2:

A patient presents with 5 remaining teeth in the mouth left to extract. After extraction, it was agreed upon to wait 3 months before the placement

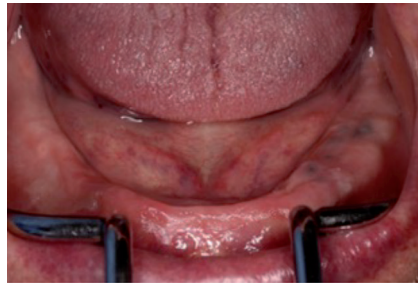

Figure 10: Edentulous ridge

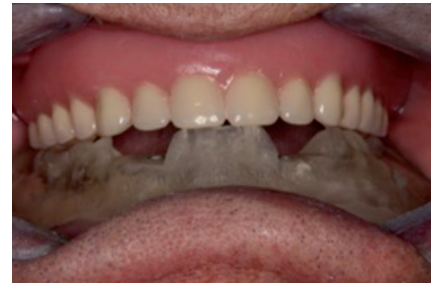

Figure 11: Surgical guide

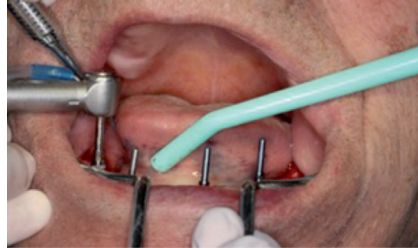

Figure 12: 5 implants placement

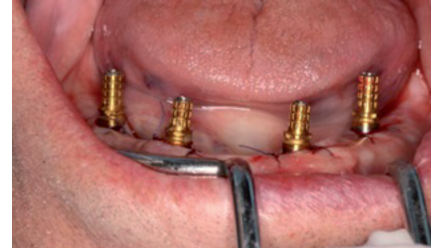

Figure 13: Screwing of 4 temporary cylinders

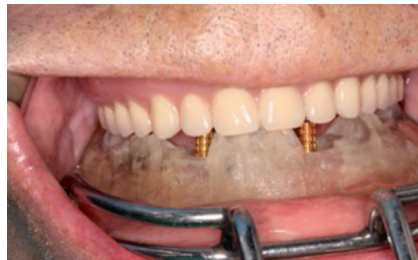

Figure 14: cylinder height adjustment

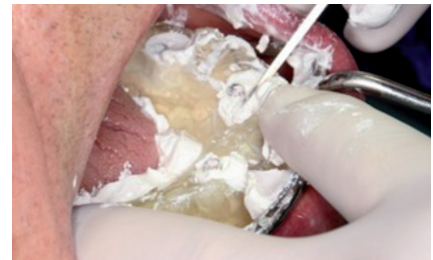

Figure 15: Impression

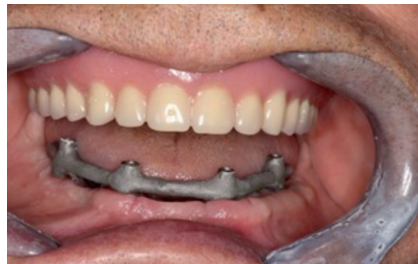

Figure 16: Testing the bar

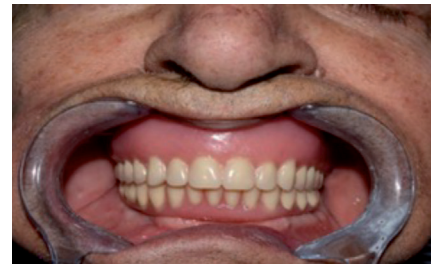

Figure 17: Prosthesis insertion

of 4 implants (Replace system - Nobel Biocare Göteborg, Sweden). (Fig 10)

A Cone Beam Computed Tomography (CBCT) was taken and a surgical guide was created in order to facilitate the right implant placement using the guided surgery technique. (Fig 11)

The surgical guide will be used as a prosthetic guide as well. The occlusion was checked and the flapless surgical placement of the 4 implants was performed. (Fig 12)

The temporary abutments were screwed on the multiunits previously set up and adjusted in occlusion. (Fig 13, 14)

Teflon tape was packed into the access opening of the screw access opening and an impression using plaster was taken using the prosthetic guide. (Fig 15)

The impression was verified and then poured and stone cast was obtained. A bar was then fabricated in the laboratory and tested. The prosthesis was finally inserted. (Fig 16, 17)

Case report 3:

A patient presented with an edentulous mandibular ridge. 5 implants (Branemark system - Nobel Biocare Göteborg, Sweden) were placed. 5 months later, the decision has been made to proceed with hybrid prosthesis. (Fig 18)

Twist-Lock impression copings were screwed onto multiunits (Fig 19, 20) and an alginate impression was taken. After removal of the impression, the replicas of the multiunits were screwed into the impression copings and placed in the alginate.

The stone was poured and the cast has allowed for the making of the customized tray. (Fig 21)

Pick Up impression copings were screwed onto the replicas of the multiunits and connected using wax. A customized resin tray was made and verified in the mouth after having screwed the impression copings. (Fig 22, 23)

After closing the screw entrance with Teflon, a plaster impression was taken. (Fig 24) The final model will allow the fabrication of a stone cast that verifies the precision of the impression.

After recording the occlusion (Fig 25), the bar was made, tested and its stability validated.

(Fig 26, 27)

The laboratory returned the prosthesis ready for insertion in the mouth. (Fig 28)

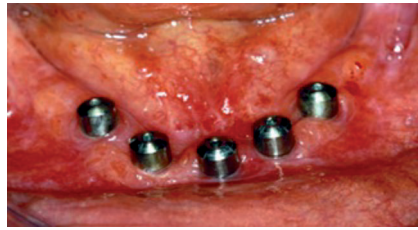

Figure 18: 5 implants placement

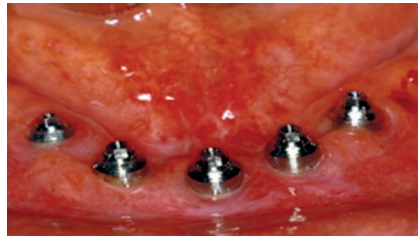

Figure 19: Screwing 5 multiunits

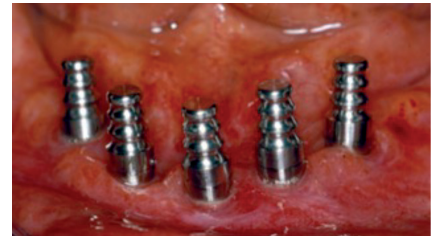

Figure 20: Screwing 5 Twist-lock coping

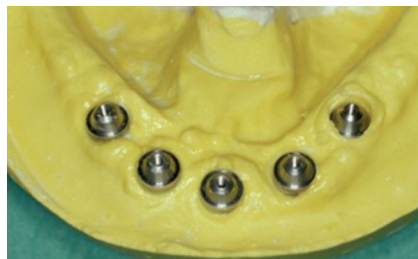

Figure 21: Primary impression

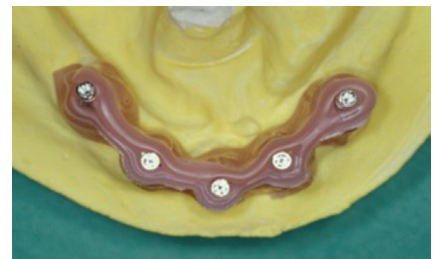

Figure 22: Customized tray fabrication

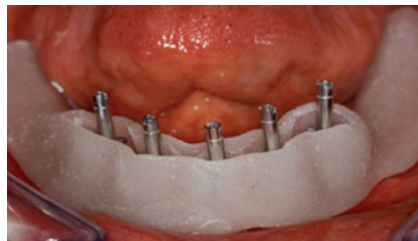

Figure 23: Tray Validation

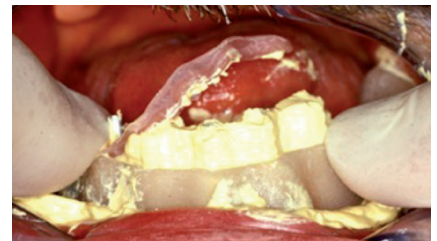

Figure 24: Plaster impression

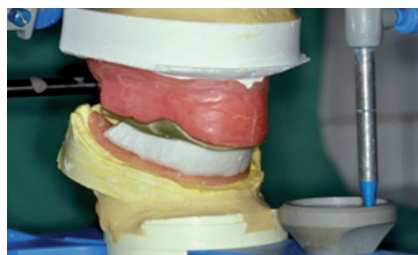


Figure 25: Occlusal registration

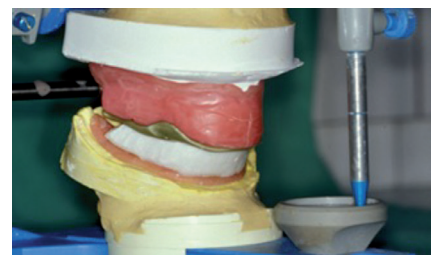


Figure 26: Fabrication of the bar




Figure 27: Validation of the bar

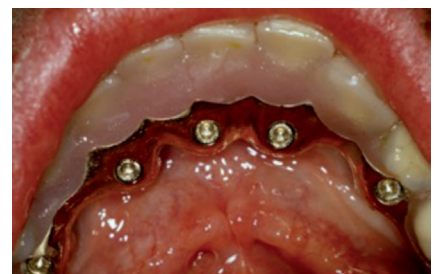

Figure 28: Prosthesis insertion

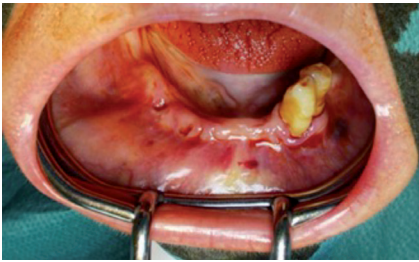


Figure 29: Clinical case 4

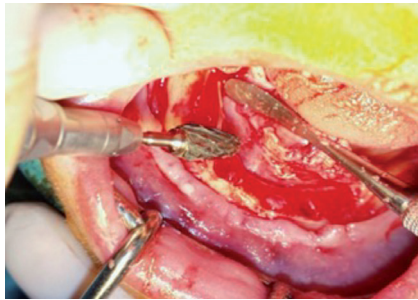


Figure 30: Bone resection

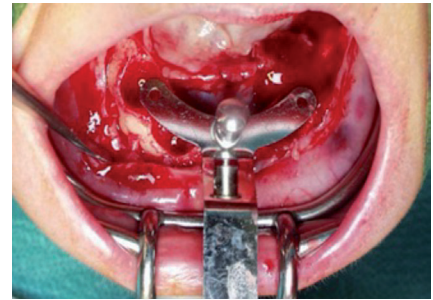


Figure 31: Positioning template

Case Report 4:

A patient presents with two teeth left for extraction at the mandible. (Fig 29)

We decided to make a prosthesis with a prefabricated metal framework (Novum system – Nobel Biocare - Göteborg, Sweden).

The Novum system was improved and replaced by Trefoil system (Nobel Biocare) used nowadays. However the transfer of prosthetic data are similar.

The Novum system can only be used when:

- 1- The horizontal bone width is at least 7 mm
- 2- The interforaminal distance is at least 3.2 cm
- 3- The available prosthetic space is at least 15 mm
- 4- The shape of the occlusal mandibular arch coincides with that of the prefabricated lower bar.

The full radiological assessment necessary for the treatment plan of the patient was completed and the surgical procedure started.

We started by opening a flap, then verifying the correct placement of the lower bar in regards of the bone ridge and the interforaminal distance.

Horizontal bone resection was necessary to obtain a 7mm bone width. (Fig 30)

The positioning template allowed placement of the medial implant. (Fig 31) An evaluation template was used to verify if the bone plate is correct and the interforaminal distance is sufficient. (Fig 32)

The steps follow one another according to a well-defined protocol which will allow the placement of 2 distant implants. (Fig 33, 34)

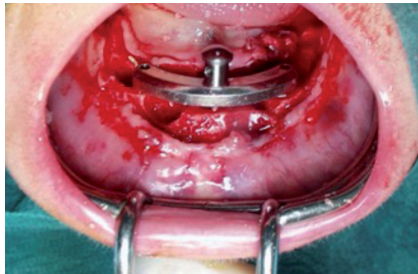


Figure 32: Evaluation template

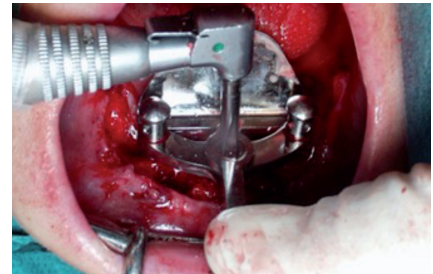


Figure 33: Drilling

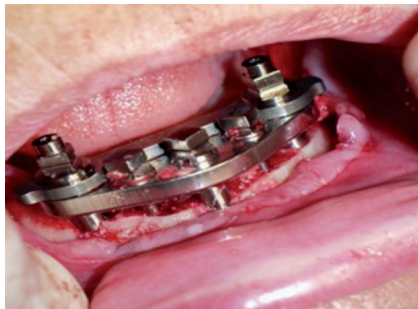

Figure 34: 3 implants placement

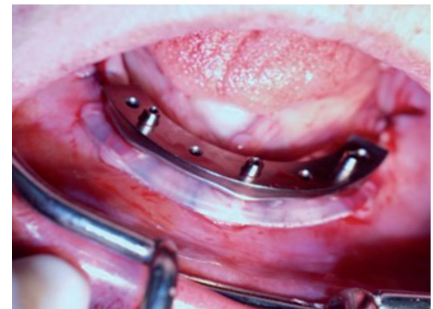

Figure 35: Screwing the lower bar

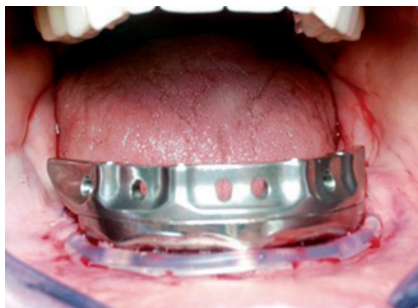


Figure 36: Screwing the upper bar

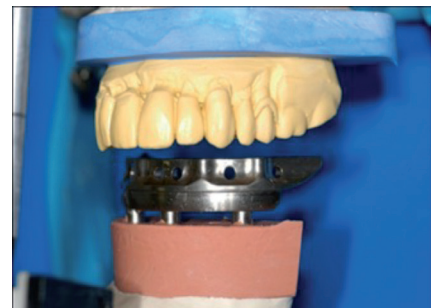

Figure 37: Articulator transfer

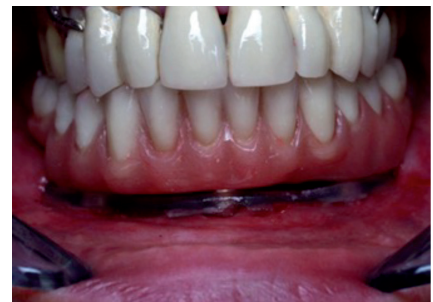

Figure 38: Prosthesis insertion

Thus, 3 implants (5mm width and 10mm length) were placed. The inferior bar was then positioned on the implants using 3 prosthetic screws. (Fig 35)

The upper bar was later positioned on the lower bar using 4 screws. (Fig 36) A silicone was used on the upper bar. The patient was asked to close to the correct vertical dimension previously determined.

The maxillary cast, was transferred using a bow face to an articulator. The mandibular cast mounted on the articulator is in fact the replica of the lower aluminum bar.

The upper bar was later removed from the mouth and screwed onto the lower aluminum bar. The silicone paste will allow to mount the lower model on the articulator. (Fig 37)

Denture teeth were assembled on the upper bar, tried in the mouth and then sent to the laboratory for the fabrication of the definitive prosthesis. (Fig 38)

Discussion

Case report 1:

The technique is fast, clean and comfortable for the patient. The amount of acryl must be large enough to ensure the stability of the transfers. The volumetric dimensional variation is linear. In fact, during the setting of the acryl, a "Shrinkage" phenomenon takes place. This phenomenon will cause a dynamic tension on the impression copings which will jeopardize the accuracy of the recording.

To overcome this problem, it is necessary that the bar is delivered in 4 segments, each one fixed apart on the appropriate implant. The entirety is connected using Duralay resin (Reliance Dental Manufacturing LLC Alsip IL, USA) in the mouth, sent to the laboratory for welding, retested in the mouth and verified. [5]

Case Report 2:

The impression plaster used is the white plaster of Paris. After dehydration in the open air, the gypsum is

transformed into white plaster Snow White™ Plaster, Kerrdental Kloten

Switzerland. This plaster is used to cast the primary impressions.

One of the things that makes this material appropriate of impressions is the presence of smaller particles of calcium sulfate B-hemihydrate obtained after treatment.

Dehydration of the gypsum in an autoclave transforms it into hard stone plaster type 1 and extra hard type 2 used to cast the secondary impressions.

The mechanical properties of plaster are the best (rigidity of 700 Ncm) compared to those of polyether (140 Ncm), silicone (74 Ncm) or even polysulfides (30 Ncm).

The impression is taken with a surgical guide that is spaced enough and able to provide proper space for enough plaster. Apart from the fact that the procedure is messy and unpleasant for the patient, the physico-chemical quality of the final product, even the plaster, is proportional to the quantity used. [6, 7]

Case report 3:

The plaster used is the same as the one in Case Report 2 except that it is used with an open customized tray prepared on a primary cast.

The qualities of the plaster can then be exploited to the maximum since the quantity used is limited to the strict minimum. As a result, the procedure becomes less unpleasant and less messy.

The stone key allows to validate the impression. In this procedure, where a customized tray was used, the stone key didn't break contrary to the one used in the Case Report 2 where the stone key often breaks. This makes this procedure highly effective. [7, 8, 9]

Case report 4:

The major disadvantage of this procedure is the significant mutilation of the bone in the vertical plane which allows to obtain a 7mm bone width. This makes the use of the "Novum" system very limited.

However, the major advantage is the lack of impressions and data transfer to the laboratory. All steps are standardized, both surgical and prosthetic. [10]

Conclusion

When it comes to the transfer to the laboratory of prosthetic data in the case of hybrid implant supported prosthesis, the "Novum System" remains the most accurate technique.

However, this procedure requires anatomical and prosthetic criteria that limit its use. In conventional techniques, white plaster using a customized impression tray remains the most accurate technique that allows clinical data to be transferred to the laboratory with the least amount of inaccuracy.

References

1. Testori T, Del Fabbro M, Galli F, Francetti L, Taschieri S, Weinstein R. Immediate Occlusal Loading the Same Day or the Day After Implant Placement: Comparison of 2 Different Time Frames in Totally Edentulous Lower Jaws. *Journal of Oral Implantology*. 2004 Oct 1; 30(5):307-13.
2. Stricker A, Gutwald R, Schmelzeisen R, Gellrich NG. Immediate loading of 2 interforaminal dental implants supporting an overdenture: clinical and radiographic results after 24 months. *Int J Oral Maxillofac Implants*. 2004 Dec; 19(6):868-72.
3. Taruna M, Chittaranjan B, Sudheer N, Tella S, Abusaad Md. Prosthodontic Perspective to All-On-4® Concept for Dental Implants. *J Clin Diagn Res*. 2014 Oct; 8(10):16-9.
4. Papaspyridakos P, Chen C-J, Gallucci GO, Doukoudakis A, Weber H-P, Chronopoulos V. Accuracy of implant impressions for partially and completely edentulous patients: a systematic review. *Int J Oral Maxillofac Implants*. 2014 Aug; 29(4):836-45.
5. Kim J-H, Kim KR, Kim S. Critical appraisal of implant impression accuracies: A systematic review. *J Prosthet Dent*. 2015 Aug; 114 (2):185-192.
6. Al Quran FA, Rashdan BA, Zomar AAA, Weiner S. Passive fit and accuracy of three dental implant impression techniques. *Quintessence Int*. 2012 Feb; 43(2):119-25.
7. Holst S, Blatz MB, Bergler M, Goellner M, Wichmann M. Influence of impression material and time on the 3-dimensional accuracy of implant impressions. *Quintessence Int*. 2007 Jan; 38(1):67-73.
8. Wee AG. Comparison of impression materials for direct multi-implant impressions. *J Prosthet Dent*. 2000 Mar; 83(3):323-31.
9. Cabral LM, Guedes CG. Comparative analysis of 4 impression techniques for implants. *Implant Dent*. 2007 Jun; 16(2):187-94.
10. Popper HA, Popper MJ, Popper JP. The Brånemark Novum protocol: description of the treatment procedure and a clinical pilot study of 11 cases. *Int J Periodontics Restorative Dent*. 2003 Oct; 23(5):459-65.