

5-2-2022

Post-surgical management of cleft lip and palate: Realization of nasal conformer

Saloua HAMZAOUI

Mohamed AZHARI

Hasnaa ROKHSSI

Majid SAKOUT

Oussama BENTAHAR

Follow this and additional works at: <https://digitalcommons.aaru.edu.jo/iajd>

Recommended Citation

HAMZAOUI, Saloua; AZHARI, Mohamed; ROKHSSI, Hasnaa; SAKOUT, Majid; and BENTAHAR, Oussama (2022) "Post-surgical management of cleft lip and palate: Realization of nasal conformer," *International Arab Journal of Dentistry*. Vol. 13: Iss. 1, Article 7.

Available at: <https://digitalcommons.aaru.edu.jo/iajd/vol13/iss1/7>

This Original Article is brought to you for free and open access by Arab Journals Platform. It has been accepted for inclusion in International Arab Journal of Dentistry by an authorized editor. The journal is hosted on [Digital Commons](#), an Elsevier platform. For more information, please contact rakan@aar.edu.jo, marah@aar.edu.jo, u.murad@aar.edu.jo.

POST-SURGICAL MANAGEMENT OF CLEFT LIP AND PALATE: REALIZATION OF NASAL CONFORMER

Hamzaoui Saloua* | Azhari Mohamed** | Rokhssi Hasnaa*** | Sakout Majid****
Bentahar Oussama*****

Abstract

Background: the given important role of the post-surgical nasal conformer in the management of cleft lip and palate, the publication of this type of case reminds us of the multidisciplinary management of cleft lip and palate of newborns, and reminds us of the usefulness of having this type of device in the therapeutic arsenal even if surgical techniques have progressed.

Case presentation: This is a newborn boy from northern Morocco who was diagnosed with a unilateral cleft lip and palate. He was first placed in an orthosis with a pre-surgical conformer on his second day of life.

When he was four months, he then underwent corrective surgery in two stages: firstly, closure of the lip and nose, and secondly, closure of the alveolar region and the palate. For the conformer that interests us in this work, it was performed after three weeks of the first surgery, in order to have better results after the second surgery

Conclusions: In summary, the presentation of this case shows us the importance of post-surgical conformers in the management of infants with cleft lip and palate and their ability to achieve better functional and aesthetic results for the patient without forgetting their psychological impact on the parents.

Key words: Cleft lip-alveolar-palate, Maxillofacial Prosthesis, Nasal Conformer, Post-surgical management, Realization.
IAJD 2022;13(1): 49-52.

* DDS, Dentist specialist in maxillofacial prosthodontics. Faculty of Dentistry- Mohammed V University- Rabat - Morocco. Captain dentist at the Mohamed V military instruction hospital in Rabat – Morocco.

**** DDS/PhD in Dentistry: Professor of Higher Education (PES) in conservative odontology. Faculty of Dentistry- Mohammed V University – Rabat – Morocco. Odontology Service Chief- Military Instruction Hospital Mohamed V- Rabat – Morocco. E-mail: m.sakout@um5s.net.ma

** DDS: Assistant professor in maxillofacial prosthodontics. Faculty of Dentistry- Mohammed V University- Rabat- Morocco. E-mail: mohamed.azhari@um5s.net.ma

***** DDS/PhD in Dentistry: Professor of Higher Education (PES) in maxillofacial prosthodontics. Faculty of Dentistry- Mohammed V University- Rabat- Morocco. E-mail: o.bentahar@um5s.net.ma

*** DDS: Assistant professor in maxillofacial prosthodontics. Faculty of Dentistry- Mohammed V University- Rabat- Morocco. E-mail: hasnaa_ro@hotmail.com

Corresponding Author: Hamzaoui Salwa
e-mail: hamzaouisaloua@gmail.com

PRISE EN CHARGE POST-CHIRURGICALE DE LA FENTE LABIO-PALATINE : RÉALISATION D'UN CONFORMATEUR NASAL

Résumé

Contexte : compte tenu du rôle important du conformateur nasal post-chirurgical dans la prise en charge des fentes labiales et palatines, la publication de ce type de cas nous rappelle la prise en charge multidisciplinaire des fentes labiales et palatines du nouveau-né, et nous rappelle l'utilité d'avoir ce type de dispositif dans l'arsenal thérapeutique même si les techniques chirurgicales ont progressé.

Présentation du cas : Il s'agit d'un garçon nouveau-né originaire du nord du Maroc chez qui on a diagnostiqué une fente labiale et palatine unilatérale. Il a d'abord été placé dans une orthèse avec un conformateur pré-chirurgical le deuxième jour de sa vie.

À l'âge de quatre mois, il a ensuite subi une chirurgie correctrice en deux étapes : d'abord, la fermeture de la lèvre et du nez, puis la fermeture de la région alvéolaire et du palais. Pour le conformateur qui nous intéresse dans ce travail, il a été effectué après trois semaines de la première chirurgie, afin d'avoir de meilleurs résultats après la deuxième chirurgie.

Conclusions : En résumé, la présentation de ce cas nous montre l'importance des conformateurs post-chirurgicaux dans la prise en charge des nourrissons atteints de fente labiale et palatine et leur capacité à obtenir de meilleurs résultats fonctionnels et esthétiques pour le patient sans oublier leur impact psychologique sur les parents.

Mots clés : Fente labio-alvéolo-palatine, Prosthodontie maxillo-faciale, Conformateur nasal, Gestion post-chirurgicale, Réalisation.

IAJD 2022;13(1): 49-52.

Introduction

Cleft lip and palate are defects resulting from a defect in the fusion of the facial buds at the end of the first month of embryogenesis. Their aetiology is multifactorial while their treatment is complex, multidisciplinary and follows a precise timetable from birth to adulthood. However, the presence of unilateral or bilateral nasal sequelae of clefts, whether because of a disease or a primary surgery, has serious consequences for maxillofacial growth [1,2].

The post-surgical nostril conformer is a device in the therapeutic arsenal of the Maxillofacial Prosthodontist which has an important place in the management of cleft lip-alveolar-palate.

Interests of the nasal conformers in the post-surgical management of cleft lip and palate

The post-surgical nasal conformer has interest in the treatment of infant clefts on several levels. Therapeutically, it allows to avoid a second surgical

step which is difficult for an infant or in case of refusal of the parents of a second surgical step.

Functionally, it facilitates ventilation by raising the nasal wings, this pneumatization allows an orthopaedic action and a growth of the maxillae and the nasal cavities [3].

The post-surgical nasal conformer has also an aesthetic role by correcting the nasal depression.

Not forgetting its psychological help for parents who find themselves involved in their child's treatment.

Realization a post-surgical nasal conformer

The realization of the post-surgical nasal conformer requires three steps: the first step is taking the impression of the nostril orifices, then a second step in the laboratory which consists in using the mould obtained to realize the conformer.

and finally, a clinical stage to insert the conformer and teach the parents the directions for use.

Step 1: Facial impression/ Facial casting (figures 1 to 4)

Step 2: Casting the Impression and Making the nasal conformer (figures 5 to 8)

Step 3: Insertion and Maintaining (figures 9 and 10)

Discussion

There is much discussion about the importance of post-surgical nasal conformers in the post-surgical management of cleft lip and palate.

According to Talamant's team, in the management of cleft lip and palate, priority should be given to the nose, ensuring the patency of the nostrils and centering of the nasal septum, both during surgery and afterwards with the use of nasal conformer [3] and therefore they support the value of these conformers in the post-surgical management while emphasizing their combined role with secondary surgery in the management of cleft lip-alveolar-palate [5].

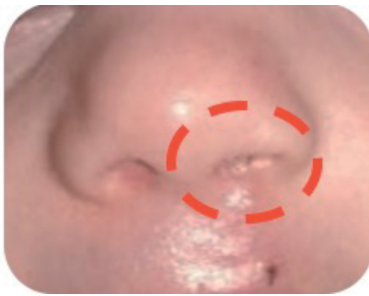


Fig. 1: Patient three weeks after surgery

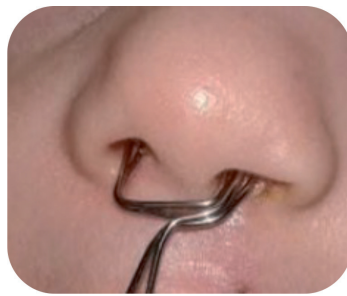

Fig. 2: Supporting fork of the shaped impression material

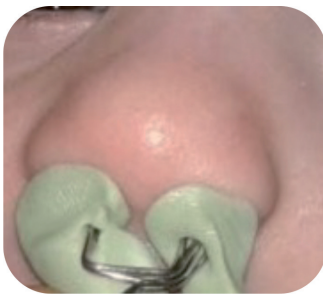

Fig. 3: Nasal orifice impression with high viscosity silicone

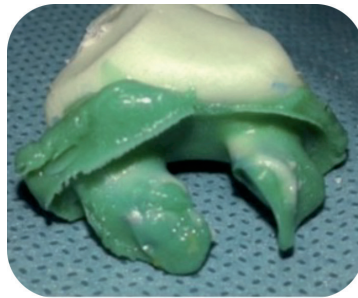


Fig. 4: Relining the impression with a low viscosity silicone



Fig. 5: Model from the nasal orifice impression



Fig. 6: stems for the nasal orifice



Fig. 7: the transparent resin in place

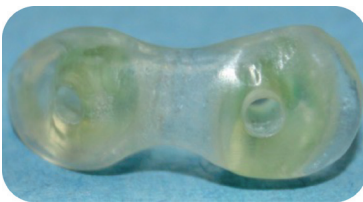

Fig. 8: Aspect of the conformer after the polymerization of the resin

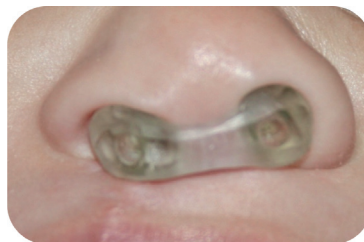

Fig. 9: Placement of the nasal conformer

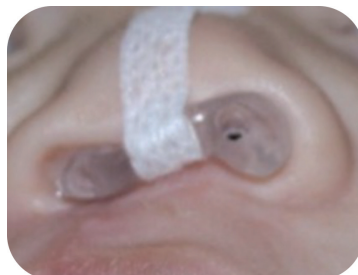

Fig. 10: Using medical tape to hold the nasal conformer in place

This vision is also adopted by the team of Titiz et al [6] who insist on their role in restoring ventilation, aesthetics by correcting the collapse of the nose nasal wing without forgetting their important orthopedic role in the growth of the maxilla from the first operation

While the team of Marsuo et al [7] showed in their study that the use of the conformer alone is sufficient in the post-surgical treatment without going through a second surgical step.

Ozyazgan and Eskitascioglu [8] also report in their presentation of the conformer the importance of the use of the nasal conformer in maintaining the results obtained by surgery.

On the other hand, Saboye [9] and Bhuskute's team [10] totally neglect the effect of this orthosis in the post-surgical management of cleft lip-alveolar-palate.

Thus, nostril conformers are still of interest in the treatment of cleft lip-alveolar-palate as shown by several studies. However, their adoption remains a matter of practitioner performance.

Conclusion

The role of nasal conformers in the post-surgical management of cleft lip and palate remains considerable given their advantages. However, the management of this type of pathology must involve a multidisciplinary team that establishes a treatment plan adapted to each case.

Conflict of Interest

The authors state that there is no conflict of interest with respect to the publication of this article.

References

1. Benoist M. Réhabilitation et prothèse maxillo-faciales. J. Prêlat, 1978-454p.
2. J.J. AKNIN. Le point sur les fentes labio-alvéolo-palatines. Rev Orthop Dento Faciale 2008;42:391-402. Doi: [org/10.1051/odf:2008045](https://doi.org/10.1051/odf:2008045)
3. J.-C. Talmant *, J.-Ch. Talmant, J.-P. Lumineau. Traitement primaire des fentes labio-palatines. Ses grands principes. Ann Chir Plast Esthet (2016); 61(5): 348-359. Doi: [org/10.1016/j.anplas.2016.06.007](https://doi.org/10.1016/j.anplas.2016.06.007)
4. J.C. Talmant, J.P. Lumineau, G. Rousteau. Prise en charge des fentes labio-maxillo-palatines par l'équipe du docteur Talmant à Nantes. Article original. Annales de Chirurgie Plastique Esthétique 2002;47:116-25. Doi: [org/10.1016/S0294-1260\(02\)00095-X](https://doi.org/10.1016/S0294-1260(02)00095-X)
5. J-Claude Talmant , J-Christian Talmant. Rhinoplastie de fente primaire et secondaire. Annales de Chirurgie Plastique Esthétique 2014;59(6):555-584. Doi: [org/10.1016/j.anplas.2014.08.004](https://doi.org/10.1016/j.anplas.2014.08.004)
6. S. Titiz, A. Aras. Presurgical Orthopedic Treatment Using Modified Nostril Retainers in Patients With Unilateral Cleft Lip With or Without Cleft Palate. The Journal of Craniofacial Surgery 2017; 28(6): 1570-1572. Doi: [10.1097/SCS.0000000000003647](https://doi.org/10.1097/SCS.0000000000003647)
7. K. Marsuo, T. Hirose, T. Otagiri, N. Norose. Repair of Cleft Lip with Nonsurgical Correction of Nasal Deformity in the Early Neonatal Period. Plastic & Reconstructive Surgery 1989;83(1):25-31.
8. I.Ozyazgan, T. Eskitascioglu. A new reshaped nostril retainer. Plastic & Reconstructive Surgery; March 2000;105(2): 804 Doi: [10.1097/00006534-200002000-00061](https://doi.org/10.1097/00006534-200002000-00061)
9. J. Saboye. La septoplastie lors de la chéilorhinoplastie primaire dans les fentes labio-palatines unilatérales. Annales de Chirurgie Plastique Esthétique 2018;63(1):81-85. Doi : [org/10.1016/j.anplas.2017.10.002](https://doi.org/10.1016/j.anplas.2017.10.002)
10. A.A. Bhuskute, T.T. Tollefson. Cleft Lip Repair, Nasoalveolar Molding, and Primary Cleft Rhinoplasty. Facial Plastic Surgery Clinics of North America 2016;24(4):453-466. Doi : [org/10.1016/j.fsc.2016.06.015](https://doi.org/10.1016/j.fsc.2016.06.015)