

1-22-2020

Ceramic veneers: a case report

Carina MEHANNA ZOGHEIB

Antonio AFRAM

Follow this and additional works at: <https://digitalcommons.aaru.edu.jo/iajd>

Recommended Citation

ZOGHEIB, Carina MEHANNA and AFRAM, Antonio (2020) "Ceramic veneers: a case report," *International Arab Journal of Dentistry*. Vol. 9: Iss. 1, Article 5.

Available at: <https://digitalcommons.aaru.edu.jo/iajd/vol9/iss1/5>

This Case Report is brought to you for free and open access by Arab Journals Platform. It has been accepted for inclusion in International Arab Journal of Dentistry by an authorized editor. The journal is hosted on [Digital Commons](#), an Elsevier platform. For more information, please contact rakan@aarj.edu.jo, marah@aarj.edu.jo, u.murad@aarj.edu.jo.

CERAMIC VENEERS: A CASE REPORT

Carina Mehanna Zogheib* | Antonio Afram** | Maroun Ghaleb***

Abstract

Contemporary dentistry's main aim is to re-establish a patient's esthetic appearance. In order to achieve this goal, minimal invasive techniques are required such as bleaching, direct composites and indirect ceramic veneer restorations, instead of ceramic crowns.

Many problems in the esthetic zone may be resolved with bleaching techniques but the need for an alternative for crowns- when bleaching is impossible to achieve or gives insufficient results- led to the advent of laminate veneers.

These techniques may be processed in two different ways: direct or indirect. Direct laminate veneers are prepared in the dental clinic by applying layers of composite material directly to the prepared tooth surface. Indirect laminate veneers may be produced from ceramic materials, in the dental laboratory.

In this case report, ceramic veneers were used for a patient with esthetic problems related to cervical abrasion and discolorations on her upper canines and premolars. The preparation and cementation are described step-by-step and the technique discussed.

As a conclusion, ceramic veneer restorations may be a treatment option for patients with esthetic problems similar to the one reported in this case.

Keywords: Dental veneers - dental porcelain - tooth discolorations - dental laminate - 3D printing.

IAJD 2018;9(1):32-41.

LES « VENEERS »: A PROPOS D'UN CAS

Résumé

L'objectif principal de la dentisterie contemporaine est de rétablir l'aspect esthétique du visage du patient. Afin d'atteindre cet objectif, des techniques mini-invasives sont requises, telles que le blanchiment, les composites directs et les restaurations indirectes en céramiques, à la place des couronnes en céramiques.

De nombreux problèmes dans la zone esthétique peuvent être résolus avec les techniques de blanchiment, mais la nécessité d'une alternative pour les couronnes - lorsque le blanchiment est impossible à réaliser ou donne des résultats insuffisants - a conduit à l'apparition des facettes en céramique.

Ces restaurations peuvent être réalisées selon deux techniques différentes: directe ou indirecte. Les facettes directes sont préparées en appliquant des couches de composite directement sur la surface dentaire préparée. Les facettes indirectes peuvent être produites à partir de matériaux en céramiques, dans le laboratoire dentaire.

Dans ce cas clinique, des facettes en céramique ont été utilisées pour un patient avec des problèmes esthétiques liés à des abrasions cervicales et à des décolorations sur les canines et prémolaires maxillaires. La technique, la préparation et le collage sont décrits étape par étape. En conclusion, les restaurations céramiques peuvent être une option de traitement pour les patients présentant des problèmes esthétiques similaires à ceux rapportés dans ce cas.

Mots clés: facettes dentaires - porcelaine dentaire - décoloration dentaire - stratifié dentaire - imprimer en 3D.

IAJD 2018;9(1):32-41.

* DDS, DEA, PhD, FICD,
Professor,
Director of Esthetic and Restorative Dentistry
postgraduate program
Faculty of Dental Medicine,
Saint Joseph University, Beirut.
carina.mehannazogheib@usj.edu.lb

** Clinical instructor,
Dpt of Prosthetic Dentistry,
Faculty of Dental Medicine,
Saint Joseph University, Beirut.

Clinical instructor,
Dpt of Restorative and Esthetic Dentistry,
Faculty of dental medicine,
Saint Joseph University, Beirut

Introduction

Cosmetic dentistry has become largely popular and widely known as a result of social trends and increased media coverage. Nowadays, the current trend in dentistry is the conservative approach which uses minimal invasive techniques. These techniques should guarantee a good dental function, phonation and optimal esthetics especially in the anterior zone.

Shade, shape and malposition of anterior teeth might lead to major esthetic problems [1].

In order to solve such problems, the only technique that was used for a long time was dental crowning [2]. However, this technique is not conservative; it can damage the periodontium and remove excessive dental tissue [3].

Therefore, new techniques emerged like bleaching and laminate veneer restorations. Since bleaching can correct some discolorations only and has no effect on dental malpositions, the porcelain veneer technique was introduced to the dental profession in the 1980s by Dr. John Calamia [4].

Laminate veneers are restorations envisioned to correct existing abnormalities, esthetic deficiencies and discolorations [5, 6]. They are bonded to the underlying tooth, mainly on enamel if the preparation is minimal [7]. They can either be direct or indirect laminate veneers.

Direct laminate veneers are prepared in the dental clinic by applying layers of composite material directly to the prepared tooth surface. The advantages of this technique are: minimal tooth preparation, low cost for patients compared with indirect techniques, reversibility of the treatment and absence of need for long laboratory procedures or an additional adhesive cementing system [8]. In addition, polishing of direct laminate veneers and repairing are relatively easy [9]. Still, their main disadvantages are low resistance to wear, discoloration and fractures [2, 8].

Indirect laminate veneers are produced from ceramics, in the dental

laboratory. There are many principal indications for ceramic laminate veneers: tooth discoloration resistant to bleaching procedures, the need for modification in anterior teeth morphology and the rehabilitation of compromised anterior teeth. Ceramic veneers are also indicated in uneven, chipped, worn or misshaped teeth [10], as well as for rotated teeth, coronal fractures, congenital or acquired malformations, diastemas, discolored restorations, palatally positioned teeth, missing lateral incisors, abrasions, erosions and worn anterior teeth [11-13].

Their advantages are high resistance against attrition, abrasion and fractures [14], color stability, optimal aesthetics, maintaining periodontal health (since ceramics are biocompatible and veneers are frequently supra-gingival), longevity of the adhesion to enamel, and good mechanical properties. They can reestablish the strength and function of teeth [11].

A literature review by Peumans et al. concluded that the adhesive porcelain veneer complex was very strong, with optimal bonding being achieved when the preparation was contained in enamel, correct adhesive treatment procedures carried out, and a suitable luting composite used. It was also concluded that the maintenance of aesthetics by porcelain veneers was excellent in the medium to long term, the periodontal response good and the patient satisfaction was high [7].

However, the main disadvantages of these indirect restorations are: the need for more than one session most of the time, higher cost [15-17], the need for an additional adhesive cement [1, 2] and removal of enamel: although the goal with veneers is to be as conservative as possible, it is necessary in most of the cases to remove 0.5-1mm of enamel in order to fabricate veneers that fit properly; this is very minimal, but it is irreversible. And despite the minimally invasive technique which should be employed, it should not be assumed that success rates of porcelain laminate veneers are 100% (7). Dumfahrt and Schaffer in an

evaluation of 191 porcelain veneers, have reported an estimated survival probability of 91% at 10 years, with six of seven failures occurring when the veneers were partially bonded to dentine (7).

However, the most important parameter for the long-term success of porcelain veneers remains an optimal case selection [16, 17].

Since its introduction in the early 1990's, intra-oral scanning processes and technologies have greatly improved and became diversified. An alternative and an improvement regarding taking the impression is the use of intra-oral scanners. Digital dentistry has become popular because of its versatile applications. Computer-aided design and computer-aided manufacturing (CAD-CAM) has been successfully used in prosthodontics; 3-dimensional printing is now a booming technology.

Three-dimensional (3D) printing, that follows the intraoral scanning, has been applied in many areas of dentistry as it offers efficiency, affordability, accessibility, reproducibility, speed, and accuracy. It can be classified in 4 general categories: 1) extrusion printing; 2) inkjet printing; 3) laser melting /sintering and 4) lithography printing. Light or lithography printing (which often also use lasers as the light source) use photopolymers, and the 3D structure results from direct exposition of the polymer to light as the sample holder moves up or down. On this latter method, two equally common approaches are utilized. In common stereolithography (SLA) printing, which is the method used in this study, a galvano-mirror scanner directs the laser light to raster the surface of a vat of monomers, exposing voxels to create 3D polymer structures in digital projection printing (or DMD-DPP, which stand for digital micromirror device-digital projection printing), on the other hand, a set of micromirrors control the on-off actuation of light to polymerize monomers an entire single layer at a time, and as a build platform

raises, a 3D polymer structure is created layer-by-layer [19].

3D printing or rapid prototyping technology has been used in different fields of dentistry, including surgical planning, fabricating maxillofacial prosthesis, making fixed and removable dental prosthodontics, orthodontics and implant dentistry. Desktop 3D printers along with 3D software provide opportunities for the use of polymer-based 3D-printed materials across all aspects of dentistry. They enable the in-office printing of diagnostic casts, teaching aids, die-trimmed casts of prepared teeth, and surgical guides [20].

In the present paper, the adopted approach was the most conservative and effective, aiming to ensure that the esthetic and functional outcomes met the patient's expectations.

Case report

Grace S., a 60-year-old pharmacist was referred to the Esthetic Dentistry Department at the Saint Joseph University, Beirut. Her chief complaint was the unaesthetic aspect of her upper canines and premolars which led to an unpleasant smile (Fig. 1).

The clinical and radiographic examination showed good periodontal health and the absence of big restorations on these teeth. Full ceramic crowns were done one year before on her 4 upper incisors. There was no periodontal or endodontic problem in this region.

Her medical history didn't show any systemic problem or detrimental habits. The patient was nonsmoker.

Two treatment plans were presented and discussed with the patient: the full-ceramic crowns option and the veneers option.

A complete review of the case, of the socioeconomic status of the patient, of her esthetic expectations and oral hygiene conditions was done. Since she was satisfied with her anterior teeth and did not want to change them, and because she categorically refused to undergo another crowning

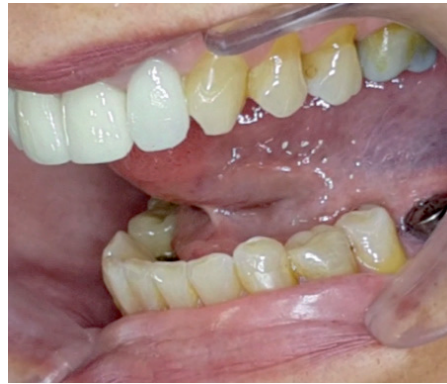

Fig. 1: Initial situation.

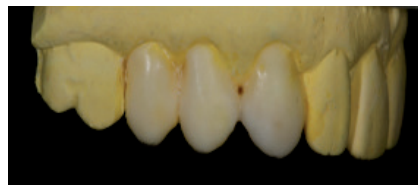

Fig. 2a: Wax-up on the right maxillary canine and premolars.

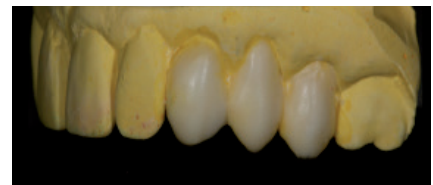

Fig. 2b: Wax-up on the left maxillary canine and premolars.

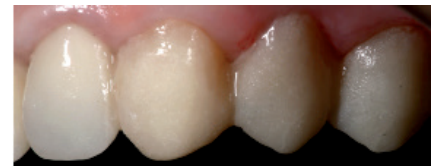

Fig. 3: Mock-up on the left maxillary canine and premolars.

procedure, the case was deemed suitable for restoration with glass-ceramic veneers on her 6 upper lateral teeth (bilateral canines and premolars). Fortunately, we had the opportunity to work with the same dental laboratory (Feghali Dental Lab.) who fabricated her anterior crowns and who had all the information about the material and the shades used.

The final decision was taken after a diagnostic wax-up (Figs. 2a and 2b) was made for assessment of suitability of the veneer restorations.

The procedure for the preparation of the teeth and the pros and cons were explained to the patient in full details. A mock-up (Fig. 3) was prepared with a silicon impression material (3M Express STD VPS Impression Putty, Maplewood, Minnesota, U.S.) placed over the wax-up to create a silicone

index. Provisional material (Luxatemp star DMG, Hambourg, Germany) was injected into the silicone index and seated on patient's dentition. The excess was detached from the impression before final setting and the silicone index was removed from the patient's mouth after setting of the provisional material. This mock-up was used as an aesthetic pre-evaluative temporary (APT) which provided a 3-D evaluation guide and simulated the final restorations.

The patient approved and consented on the treatment after seeing the mock-up.

The final treatment plan consisted in the preparation and the bonding of six glass-ceramic veneers on her maxillary lateral teeth (bilateral canines and premolars).

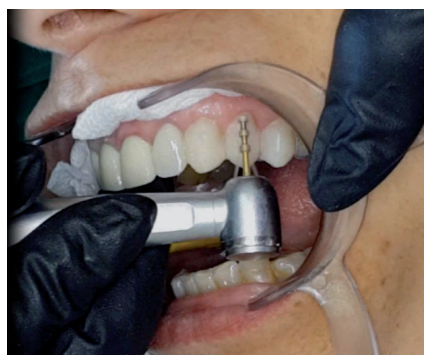

Fig. 4: Horizontal cuts.

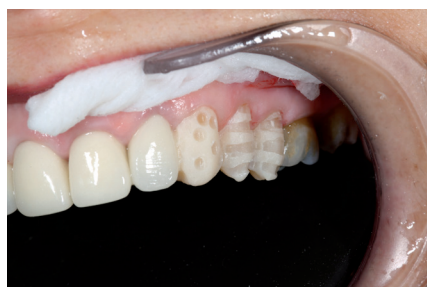

Fig. 5: Grooves were pinpointed.

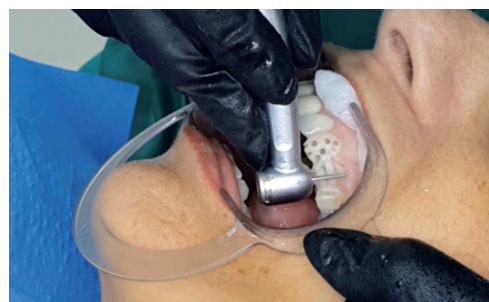
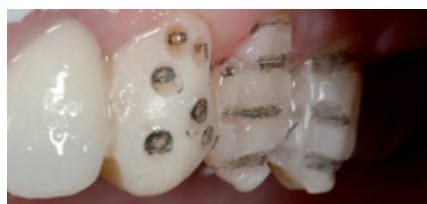
Fig. 6: Vestibular reduction.

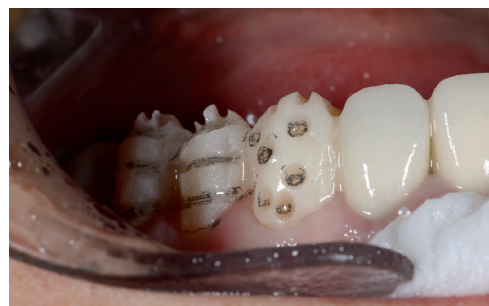

Fig. 7: Incisal grooves.

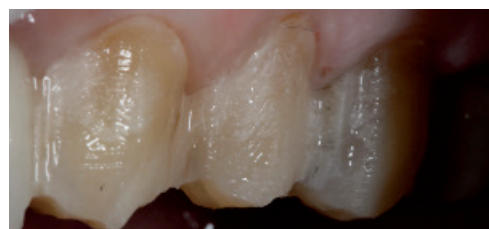

Fig. 8: Final preparation before removing the remaining mock-up.

The first clinical appointment

Surface preparation

Teeth were prepared with minimal tooth reduction in enamel using special diamond burs (Meisinger (2413) Laminate Veneer Kit, Germany).

The trimming was done according to the aesthetic pre-evaluative temporary (APT) technique which enables the dentist to achieve highly aesthetic results while preserving tooth structure [21-23] and which is used as a guide, with the help of depth cutter burs.

Horizontal cuts were made on APT with a depth cutter or gauge bur (# 834-FG-018) by moving it across the labial surface from mesial to distal, to develop three evenly spaced grooves, each 0.4 mm in depth (Fig. 4).

The grooves were pinpointed with a pen for a better visualization (Fig. 5).

The labial reduction was then done using a shoulder prep diamond bur (# 852 G 806 314) to remove a uniform thickness of the remaining labial tooth structure between the depth cuts of facial surface. This reduction is done following the 3 directions of the tooth (incisal, middle and gingival) in order to achieve a uniform and homothetic preparation (Fig. 6).

This reduction extended interproximally with preservation of the contact point to prevent teeth movement during temporization and to preserve the gingival embrasure [24, 25].

The contact between the teeth was preserved. It was broken only when we needed to shift the midline or if we had major tooth-size discrepancies or contact area modification into type I [24]. The preparation wrapped interproximally to the lingual in the

gingiva-proximal area. Otherwise, the unprepared tooth structure would be visible when seen from the side [22, 24, 26].

The 1.5mm incisal edge depth cuts were placed with a bur (MADC 015 bur, Kerr west Collins IOA, USA) (Fig. 7) and the excess of resin eliminated occlusally to have an adequate thickness of the ceramics in the incisal butt preparation area.

The cervical chamfer margin finish line was juxta-gingival in order to preserve the gingiva and to facilitate cleaning [11].

The final preparation before removing the remaining mock-up was evaluated (Fig. 8).

In areas where the APT was thin, the preparation reached the tooth structure and dental tissue was removed. But, in areas where APT was thick,

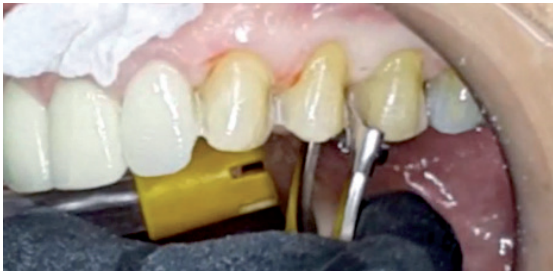

Fig. 9: Microcut used between the prepared teeth to separate interproximal surfaces .

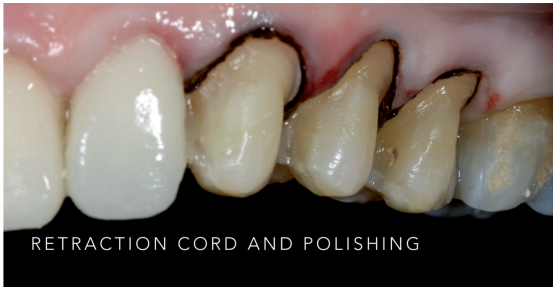

Fig. 10: A # 00 retracting cord was inserted around the preparations.

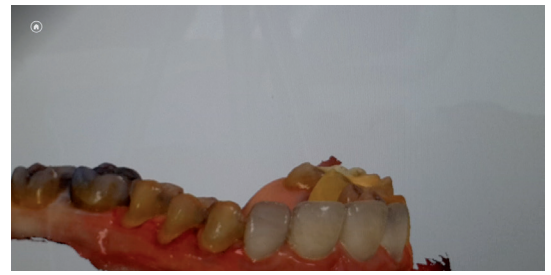

Fig. 11: Scan image technique.

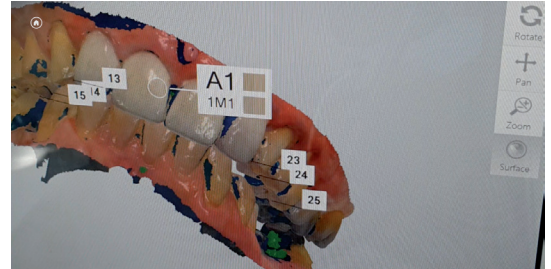


Fig. 12: Choice of color technique.

no tooth preparation occurred. This outcome shows that this technique allows an accurate and minimal invasive preparation [21- 23].

The preparations were then polished and all line angles were maintained rounded removing all the rough edges to minimize stress build-up during function. It is important to make sure that the incisal third of the preparation curves back toward the lingual to avoid having a buckteeth aspect with the veneers in place. The Microcut instrument (3030 TDV, Pomerode - Santa Catarina –

Brazil) was then used between the prepared teeth to separate the interproximal surfaces. This procedure improves visualization for lab technician without breaking the contact point due to the instrument thickness of only 0.05mm (Fig. 9).

A reduction guide was fabricated using the diagnostic wax-up to ensure adequate reduction of the dental surfaces before taking the impression.

A # 00 retracting cord was inserted around the preparations and then the

preparations were completely finished and polished. (Fig. 10)

Scanning

The cord was left in place 8-10 minutes and the intraoral preliminary scan was done with TRIOS-3Shape intraoral scanner (Holmens Kanal 7, 4, 1060 Copenhagen K Denmark). Then the cord was removed. The zoom button was hit and the scan was redone over the gingival margins. The existing cord seen in the first scan disappeared and was replaced with scan image without cord. (Fig. 11)

Choice of color

The shade measurement was done by the shade measurement tool of the same scanner which gives HD photos for a digital reliability of the color choice (Fig. 12).

Temporization

A transparent silicone material (Elite glass, Zhermack, Badia Polesine, Italy) was then applied on the diagnostic wax-up to make a clear matrix for

fabrication of provisional veneer restorations (Fig. 13).

37% Phosphoric acid gel (Scotchbond™ Universal Etchant 3M Maplewood, Minnesota, U.S.) was applied on enamel in a Spot-Etching technique for 30 seconds. A drop of this acid was put at the mid-central facial surfaces of canines and premolars (Fig. 14a). Spot bonding resin (3M ESPE Adper Adhesive, Minnesota, U.S.A) (Fig. 14b) was applied on the etched spots and light-polymerized to optimize retention [27].

The matrix was loaded with composite resin material (3M ESPE Filtek Z250 A2 syringe composite, Maplewood , Minnesota, U.S) (Fig. 14c) and positioned over the prepared teeth. Light curing of the composite resin was done through the transparent impression material (Fig.14d).

The matrix was then removed and trimming of excess material was carried out with a finishing bur (889LC Meisinger Germany). Occlusion was checked and adjusted accordingly. Final polishing with points (POGO,




Fig. 13: Transparent silicone material to make a clear matrix.

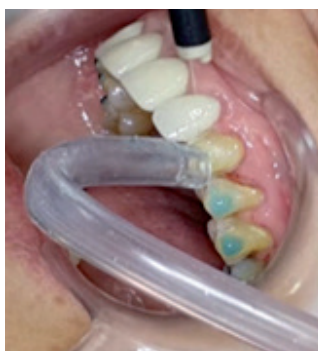

Fig. 14a: Spot-etching technique.

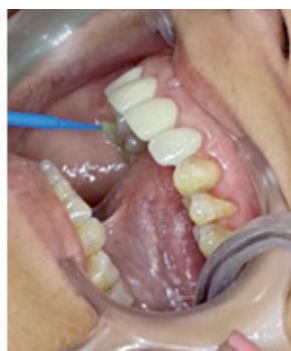

Fig. 14b: Spot-bonding technique.

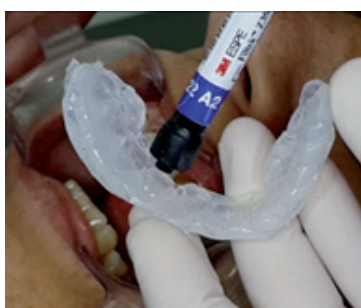

Fig. 14c: Temporization using flowable composite in the silicone matrix.

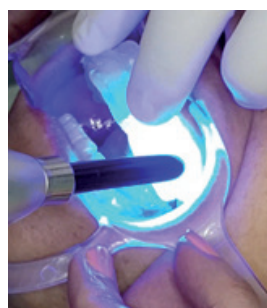

Fig. 14d: Polymerization through the transparent matrix.

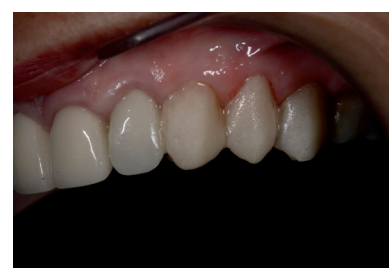

Fig. 15: Provisional veneer restorations.

Dentsply, 3M ESPE Spiral Finishing and Polish Maplewood, Minnesota, U.S) was then performed (Fig. 15). The patient left the clinic satisfied with her appearance.

The second clinical appointment

Removing temporaries

Rather than trying to remove the temporaries with hemostats, it is easier to cut them off. Slices were made using a bur through the facial and incisal surfaces of the temporaries without touching the tooth. The temporaries were cracked with a rigid instrument to remove them (Fig. 16).

Try-in

It is always better to try- in the veneers individually to check for marginal fit without the influence of potential tight contacts. Once the fitting was confirmed, we checked the contacts between them.

The try-in paste used was translucent (Ivoclar Vivadent Esthetic Ic, Schaan, Liechtenstein) and it showed that it was a good choice for final cementation (Figs. 17a and 17b).

Dental surface preparation

The framed rubber dam (Ivoclar vivadent, Schaan, Liechtenstein) was placed in order to have a dry and clean field and teeth were etched with 37 % phosphoric acid for 10 seconds on dentin and 15 seconds on enamel (Fig. 18).

The bonding agent (Ivoclar Vivadent Esthetic Ic, Schaan, Liechtenstein) was applied but no photopolymerization was done.

Ceramic surface preparation

After rinsing out the water-soluble try-in cement and drying the internal surface of the veneers, a polyvinyl siloxane material (Express light-body 3M Maplewood, Minnesota, U.S) was used to fix the veneers on a waxed paper to facilitate their treatment (Fig. 19).

5% Hydrofluoric acid (HA) was applied during 20 seconds to etch the E-max intaglio surface [28]. The application of HA forms a retentive etching pattern by dissolving silicon ions in the glassy state.

The silane (3M Scotch AP115 Silane Glass Maplewood, Minnesota, U.S) was then placed on the internal aspects of the veneer (Fig. 20). It is left in place for 60 seconds, then air-evaporated.

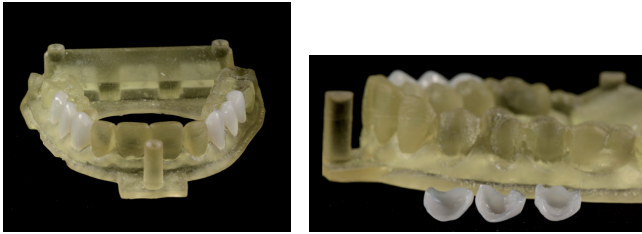
The high chemical affinity between silicon and fluoride ions leads to the formation of silicon fluoride derivatives which are soluble and can be rapidly washed off with water.[29].

The polyvinyl siloxane material in which the veneers were embedded helped in avoiding to get silane on the outer surface of the restorations because this excess would have made resin cement stick to the outer surface which would have increased the difficulty to remove it after bonding the veneers to the tooth [21, 23].

The bonding agent (Ivoclar Vivadent esthetic Ic, Schaan, Liechtenstein) was applied but no photopolymerization was done.

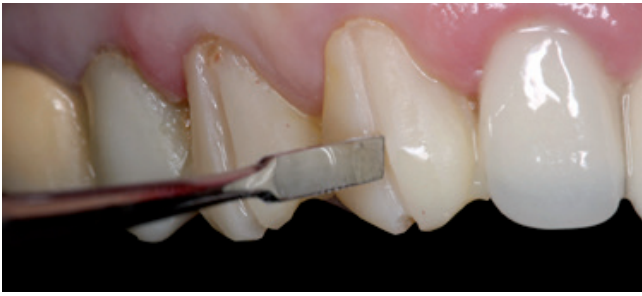

Fig.16: Removing the temporaries.



Figs.17a and 17b: The veneers on the 3D model.

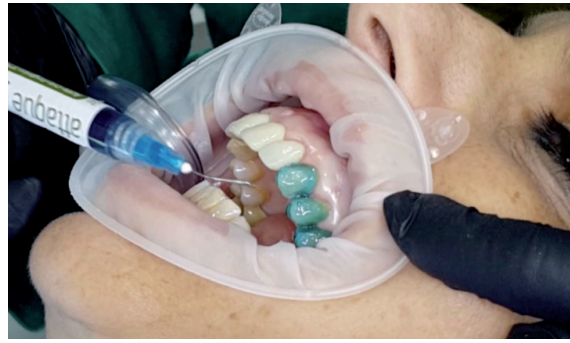

Fig.18: Etching with 37% phosphoric acid.



Fig.19: Etching and rinsing the veneers.

Bonding veneers

Teeth were separated by Mylar strips or Teflon tapes.

Light-polymerized resin cement (Ivoclar Vivadent esthetic lc, Schaan, Liechtenstein) was applied to the intaglio of each veneer restoration just before placing it on the tooth surface. (Fig. 21a).

The veneers were carried to the dental surface and held gently in place using a sticky pole (Fig. 21b). Light curing was done for 2-3 seconds using the “tack-and-wave” technique: each restoration was “tacked” to place using a 2.0 mm light guide in the center of the restoration for 1 second. Then light guide was “waved” for 3 seconds from buccal and 3 seconds from lingual surfaces approximately 2.5 cm from the ceramic surface (Fig. 21c).

This technique established a “semi-gel” state which enabled us to remove the excess cement from gingival and interproximal margins with an explorer before final polymerization (Fig. 21d).

Then, the restorations were flossed to remove excess from the interproximal area.

A liquid strip like Glycerine gel (E-Z Lubricating Jelly, Chester labs, Cincinnati USA) was applied on the margins to prevent the oxygen-inhibited layer of composite cement.

Final polymerization was achieved by curing the restorations for at least one minute per tooth.

Finishing and Polishing

Once all the veneers have been cleaned up with an explorer and floss, the excess veneer cement was removed from the palatal margin and the occlusion was adjusted using the bur 7408 12-fluted carbide which is very well adapted to the palatal surfaces (Fig. 22).

Polishers (POGO Dentsply, 3M ESPE Spiral Finishing and Polish Maplewood, Minnesota, U.S) were then used to give the final luster (Figs. 23a and 23b).

The patient was satisfied and she declared that the result matched her expectations with reality and she asked to have her lower teeth done the same way. She was instructed in the oral hygiene and recall visits were scheduled every 6 months (Figs. 24a and 24b).

Discussion

In the 21st century, layered feldspathic ceramic is still the state of the art in esthetic veneers.

However, laminate veneers have become a standard dental procedure [17]. This is due to the need for a conservative esthetic solution for the intermediate problems of anterior teeth and the evolution of the bonding systems as well as the improvement in dental ceramic materials from feldspathic porcelain to new glass-ceramic formulations with high strength and resistance to chipping. Compared to crowns, ceramic veneers offer a conservative preparation design. The




Fig. 20: Application of silane.

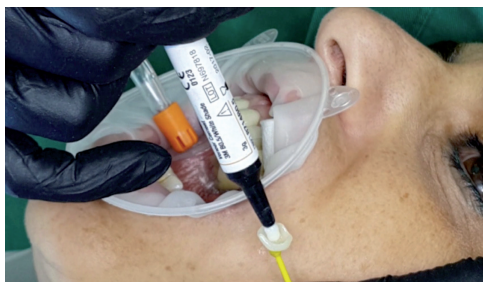

Fig. 21a: Application of resin cement.

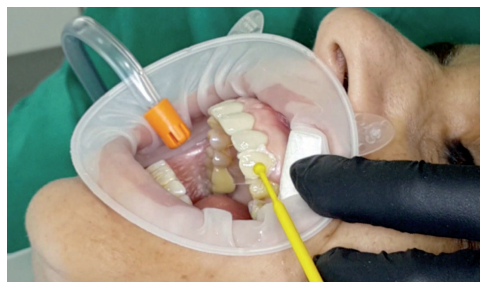

Fig. 21b: Placing the veneer restoration on the tooth.

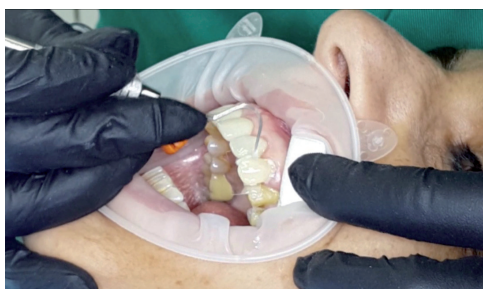

Fig. 21c: Polymerization for 2 seconds.

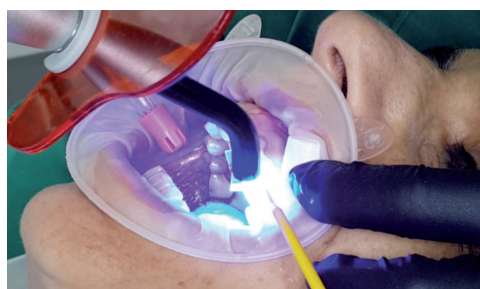

Fig. 21d: Removing the excess of cement.



Fig. 22: fluted carbide bur.



Figs. 23a and 23b: Polishers to give the final luster.

minimal depth, ranging from 0.3 to 0.5 mm leads to a reliable bonding in enamel in order to maintain preparations minimally invasive with no or minimal involvement of dentin [30]. In a clinical study done by Gurel et al. in 2012 on 580 porcelain veneers over a period of 12 years, failures were observed when preparations had 20 percent involvement of dentin, but no veneer failures were observed when preparations were completely confined to enamel [21]. Burke reached the same conclusion in a review article that analyzed 24 papers published on the survival of porcelain veneers [31].

The gingival retraction cords were used in this case to have a dry and cleared field for intraoral scanning.

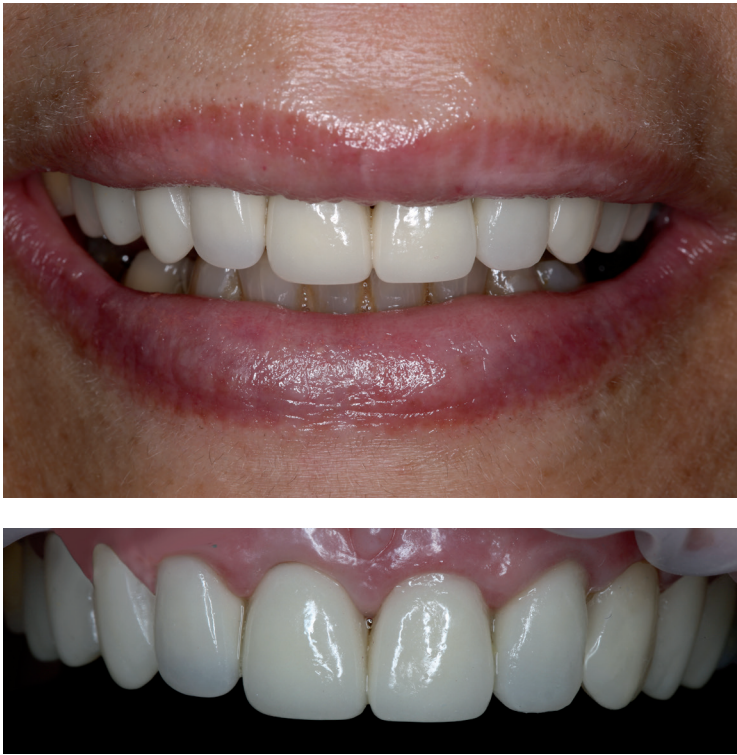Even though gingival retraction paste can more effectively help to achieve a dry field and at the same time be less injurious to soft tissues, its ability to displace gingival tissues, compared to retraction cords, was compromising according to the systemic review done by C.Huang in 2016 [32].

Aesthetic pre-evaluative temporary (APT) technique was used to allow the patient to judge the final restorative design before the provisional restoration had been made. This lead to predictable aesthetic outcome and no under or over preparations of the teeth ensuring minimally invasive tooth preparation [21-23]. Therefore the APT technique advantages include

foreseeable aesthetics, optimal occlusion, and phonetics [21, 22].

The intraoral scanning was employed in this case because according to many articles [33-35], this technique has many advantages:

* Regarding the dentist, a superior output related to the level of detail of the dentition and soft tissue provided; real color representation (i.e. tooth shades and gingiva texture can be detected better), real time representation, usability, standardization, open system flexibility and cost-effectiveness. Add to this an improved workflow because a single imaging session provides models for records and diagnostics, eliminates the need for



Figs. 24a and 24b: Final result.

a conventional impression and stone model, provides instant educational information for the dentist as well as the patient. Thus preparation and restoration analysis can be directly monitored on the screen;

- * Concerning the lab and the impression itself, easy communication and reduced lab turnaround times, fast acquisition, no impression tray disinfection and cleanage and no waste products. A digital model is always available in the same original quality, easy archivability, selective repeatability and standardization;

- * Regarding the patient, elimination of the risk of potential choking hazards, patients gagging, reduction of the number of appointments needed, enhanced patient education and Improved case acceptance.

The shade was selected by the TRIOS- 3 shape. The digital impression solution embeds the teeth shade information into the intraoral scan which is

then used to design the restoration. This makes communication of the teeth shade much simpler and eliminates several steps in the workflow for both the lab and dentist. Several studies found the reliability of the objective, computer-based systems higher compared with the subjective, visual method for color determination [36].

Conclusion

Preparing a tooth to receive a ceramic veneer, taking the impression and bonding the veneer are relatively simple procedures. However, choosing the optimal case according to the indications, to the patient's aesthetic needs and avoiding over treatments remain the most important parameters for the longevity and sustainability of this procedure.

Laminate veneer restorations can be a treatment option for patients with esthetic problems of anterior teeth,

when applied judiciously, with good patient hygiene motivation, in order to provide them with the most desirable esthetic appearance.

References

1. Yuzugullu B, Tezcan S. Comparative indications of laminate veneer restoration types used for colored and eroded teeth . 2005; Cumhuriyet University, Di Hekimli i Fakültesi Magazine Volume: 8 Issue: 2.
2. Hickel R, Heidemann D, Staehle HJ, Minnig P, Wilson NH. Direct composite restorations: Extended use in anterior and posterior situations. *Clin Oral Investig* 2004 Jun 1;8(2):43–4.
3. Aristidis GA, Dimitra B. Five-year clinical performance of porcelain laminate veneers. *Quintessence Int Berl Ger* 1985 2002 Mar;33(3):185–9.
4. Calamia JR. Etched porcelain veneers: the current state of the art. *Quintessence Int Berl Ger* 1985;16(1):5.
5. Zorba YO, Ercan E. Direkt uygulanan kompozit laminate veneerlerin klinik değerlendirilmeleri: iki olgu sunumu. *SÜ Diş Hek Fak Derg* 2008;17(2):130–5.
6. Özdemir E, Ağuloğlu S, Değer Y. The esthetic rehabilitation of three patients with enamel defect on anterior teeth by using laminate composite and porcelain veneer (case reports). *Acta Odontol Turc* 2009;26(3):171.
7. Burke FJ, Lucarotti PS. Ten-year outcome of porcelain laminate veneers placed within the general dental services in England and Wales. *J Dent*. 2009 Jan 1;37(1):31–8.
8. Hemmings KW, Darbar UR, Vaughan S. Tooth wear treated with direct composite restorations at an increased vertical dimension: results at 30 months. *J Prosthet Dent* 2000;83(3):287–293.
9. Berksun S, Kedici PS, Sağlam S. Repair of fractured porcelain restorations with composite bonded porcelain laminate contours. *J Prosthet Dent* 1993;69(5):457–458.
10. Morimoto S, Albanesi RB, Sesma N, Agra CM, Braga MM. Main Clinical Outcomes of Feldspathic porcelain and glass-ceramic laminate veneers: A systematic review and meta-analysis of survival and complication rates. *Int J Prosthodont*.2016;29(1).
11. Esthetic, occlusal, and periodontal rehabilitation of anterior teeth with minimum thickness porcelain laminate veneers. *J Prosthet Dent* 2014 Dec 1;112(6):1315–8.
12. Belser UC, Macne P, Macne M. Ceramic laminate veneers: continuous evolution of indications. *J Esthet Restor Dent* 1997;9(4):197–207.
13. Mangani F, Cerutti A, Putignano A, Bollero R, Madini L. Clinical approach to anterior adhesive restorations using resin composite veneers. *Eur J Esthet Dent Off J Eur Acad Esthet Dent* 2007;2(2):188–209.
14. Jordan RE. Esthetic composite bonding: techniques and materials. Mosby; 1993.
15. Bağış B, Bağış HY. Porselen laminate veneerlerin klinik uygulama aşamaları: Klinik bir olgu sunumu. *Ank Üniversitesi Diş Hekim Fakültesi Derg* 2006;33(1):49–57.
16. El-Badrawy W, El-Mowafy O. Comparison of porcelain veneers and crowns for resolving esthetic problems: two case reports. *J Can Dent Assoc* 2009;75(10):701–704.
17. El-Mowafy O. The use of both porcelain veneers and all-porcelain crowns in restoring anterior teeth. *Canadian Dental Assoc* 2006.
18. Patzelt SB, Lamprinos C, Stampf S, Att W. The time efficiency of intraoral scanners: an in vitro comparative study. *J Am Dent Assoc* 2014;145(6):542–551.
19. Tahayeri A, Morgan M, Fugolin AP, Bompolaki D, Athirasala A, Pfeifer CS, Ferracane JL, Bertassoni LE. 3D printed versus conventionally cured provisional crown and bridge dental materials. *Dent Mater* 2017 Oct 27.
20. Three-dimensional printing in contemporary fixed prosthodontics: A technique article. *J Prosthet Dent* 2017 Sep 6.
21. Gurel G, Morimoto S, Calamita MA, Coachman C, Sesma N. Clinical performance of porcelain laminate veneers: outcomes of the aesthetic pre-evaluative temporary (APT) technique. *Int J Periodontics Restorative Dent* 2012;32(6).
22. Gürel G, Gürel G. The science and art of porcelain laminate veneers. Quintessence London; 2003.
23. Magne M, Magne P, Cascione D, Munck I. Optimized laboratory-fabricated provisionals. *Dent Dialogue* 2006;5(2):68–76.
24. Rouse JS. Full veneer versus traditional veneer preparation: A discussion of interproximal extension. *J Prosthet Dent* 1997 Dec 1;78(6):545–9.
25. Priest G. Proximal margin modifications for all-ceramic veneers. *Pract Proced Aesthetic Dent PPAD* 2004;16(4):265–72.
26. Gürel G. Porcelain laminate veneers: minimal tooth preparation by design. *Dent Clin North Am* 2007;51(2):419–431.
27. Kurtz KS. Constructing direct porcelain laminate veneer provisionals. *J Am Dent Assoc* 1995;126(5):653–656.
28. Posritong S, Borges ALS, Chu T-MG, Eckert GJ, Bottino MA, Bottino MC. The impact of hydrofluoric acid etching followed by unfilled resin on the biaxial strength of a glass-ceramic. *Dent Mater* 2013;29(11):e281–e290.
29. Lu H, Wang Q, Li Z, Lai G, Jiang J, Shen Z. A specific chemodosimeter for fluoride ion based on a pyrene derivative with trimethylsilyl ethynyl groups. *Org Biomol Chem* 2011;9(12):4558–4562.
30. Pippin DJ, Mixson JM, Soldan-Elis AP. Clinical evaluation of restored maxillary incisors: veneers vs. PFM crowns. *J Am Dent Assoc* 1995;126(11):1523–1529.
31. Burke FT. Survival rates for porcelain laminate veneers with special reference to the effect of preparation in dentin: a literature review. *J Esthet Restor Dent* 2012;24(4):257–265.
32. Huang C, Somar M, Li K, Mohadeb JVN. Efficiency of cordless versus cord techniques of gingival retraction: A systematic review. *J Prosthodont* 2017 Apr 1;26(3):177–85.
33. Cecilia Goracci, Lorenzo Franchi, Alessandro Vichi and Marco Ferrari. Accuracy, reliability, and efficiency of intraoral scanners for full-arch impressions: a systematic review of the clinical evidence. *European Journal of Orthodontics*. 2016 Aug; 38(4):422–8.
34. Garino F, Garino B. The OrthoCAD iOC intraoral scanner: A six-month user report. *J Clin Orthod*. 2011 Mar; 45(3): 161–4.
35. Francesco Mangano, Andrea Gandolfi, Giuseppe Luongo, and Silvia Logozzo. Intraoral scanners in dentistry: a review of the current literature. *BMC Oral Health*. 2017; 17: 149.
36. Monica Anand, Pratheek Shetty, Sudhakar G Bhat. Shade matching in fixed prosthodontics using instrumental color measurements and computers. *J Indian Prosthodont Soc* 2007;7:179–83.