

2023

Cone Beam Computed Tomographic Assessment of Radiographic Changes After Indirect Pulp Capping Using Diode Lasers And Silver Diamine Fluoride In Permanent Molars With Deep Carious Lesions

Mohamed El-Tayeb M.N.

Department of Endodontics, Faculty of Oral and Dental Medicine, Badr University in Cairo, Cairo, Egypt

Mohamed Nabeel

Endodontic Department, Faculty of Oral and Dental Medicine, Misr International University, Cairo, Egypt

Follow this and additional works at: <https://digitalcommons.aaru.edu.jo/iajd>



Part of the [Endodontics and Endodontology Commons](#)

Recommended Citation

El-Tayeb, Mohamed M.N. and Nabeel, Mohamed (2023) "Cone Beam Computed Tomographic Assessment of Radiographic Changes After Indirect Pulp Capping Using Diode Lasers And Silver Diamine Fluoride In Permanent Molars With Deep Carious Lesions," *International Arab Journal of Dentistry*. Vol. 14: Iss. 2, Article 16.

Available at: <https://digitalcommons.aaru.edu.jo/iajd/vol14/iss2/16>

This Original Article is brought to you for free and open access by Arab Journals Platform. It has been accepted for inclusion in International Arab Journal of Dentistry by an authorized editor. The journal is hosted on [Digital Commons](#), an Elsevier platform. For more information, please contact rakan@aarj.edu.jo, marah@aarj.edu.jo, u.murad@aarj.edu.jo.

CONE BEAM COMPUTED TOMOGRAPHIC ASSESSMENT OF RADIOGRAPHIC CHANGES AFTER INDIRECT PULP CAPPING USING DIODE LASERS AND SILVER DIAMINE FLUORIDE IN PERMANENT MOLARS WITH DEEP CARIOUS LESIONS: AN *IN-VIVO* STUDY

Mohamed M.N. El-Tayeb¹ | Mohamed Nabeel²

Aim: To compare the preservation of pulp vitality by indirect pulp capping using Diode laser and Silver Diamine Flouride in management of deep carious lesions.

Methods: Thirty patients with an age range of 18-46 years were selected and randomly divided into 3 equal groups: Group 1 (Control group): indirect pulp capping was performed using Biodentine, Group 2: Diode laser with an output power of 0.5 watt was applied before Biodentine placement, and Group 3: Application of Silver Diamine Flouride followed by Biodentine. Pre-operative clinical assessment and radiographs were performed before intervention and then the patients received their treatment and final restorations. Follow-up with clinical assessments was performed after 3 and 6 months. Cone beam computed tomography was performed at the day of intervention and after 6 months. Clinical and Radiographic data were collected, tabulated and statistically analyzed to compare between the success rates of indirect pulp capping using diode laser, Silver Diamine Flouride and Biodentine in management of deep carious lesions.

Results: The results of clinical assessment for all groups have shown success rate of 100%. The remaining dentin thickness was significantly increased in all study groups after application of intervention. Also, the remaining dentin density showed significant increase in all groups, where Diode laser application with an output power of 0.5 watt group was significantly higher than the control group, with no significant difference between other groups.

Conclusions:

Within the limitations of the current study, the following can be concluded:

1. Using Biodentine in indirect pulp capping is the treatment of choice in management of deep carious lesions.
2. Silver Diamine Flouride can be used as an alternative indirect pulp capping material.
3. Diode laser can show promising results in terms of Cavity Disinfection & can have better biomodulating outcomes on the pulpal tissue healing and repair.

Keywords: Biodentin, Silver diamine flouride, Diode laser, Indirect pulp capping.

Correspondence to:

Mohamed M.N. El-Tayeb. E-mail: eltayeb65@hotmail.com

Conflicts of interest:

The authors declare no conflicts of interest.

1- Lecturer of Endodontics, Department of Endodontics, Faculty of Oral and Dental Medicine, Badr University in Cairo, Cairo, Egypt. eltayeb65@hotmail.com

2- Lecturer of Endodontics, Endodontic Department, Faculty of Oral and Dental Medicine, Misr International University, Cairo, Egypt. dr.neebo@hotmail.com

ÉVALUATION TOMODENSITOMÉTRIQUE PAR FAISCEAU CONIQUE DES MODIFICATIONS RADIOGRAPHIQUES APRÈS COIFFAGE PULPAIRE INDIRECT À L'AIDE DE LASERS À DIODE ET DE FLUORURE DE DIAMINE D'ARGENT SUR DES MOLAIRES PERMANENTES PRÉSENTANT DES LÉSIONS CARIEUSES PROFONDES: : ETUDE IN VIVO

Objectif : Comparer la préservation de la vitalité pulpaire par coiffage pulpaire indirect à l'aide d'un laser à diode et de fluorure d'argent diamine dans la prise en charge des lésions carieuses profondes.

Méthodes : Trente patients âgés de 18 à 46 ans ont été sélectionnés et répartis au hasard en 3 groupes égaux : Groupe 1 (groupe témoin) : le coiffage pulpaire indirect a été réalisé à l'aide de Biodentine, Groupe 2 : laser à diode d'une puissance de 0,5 watt a été appliqué avant la mise en place de Biodentine, et Groupe 3 : Application de fluorure d'argent diamine suivie de Biodentine. Un bilan clinique préopératoire et des radiographies ont été réalisés avant l'intervention, puis les patients ont reçu leur traitement et leurs restaurations définitives. Un suivi avec des évaluations cliniques a été réalisé après 3 et 6 mois. Une tomodensitométrie à faisceau conique a été réalisée le jour de l'intervention et après 6 mois. Les données cliniques et radiographiques ont été collectées, tabulées et analysées statistiquement pour comparer les taux de réussite du coiffage pulpaire indirect utilisant le laser à diode, le fluorure d'argent diamine et la biodentine dans la prise en charge des lésions carieuses profondes.

Résultats: Les résultats de l'évaluation clinique pour tous les groupes ont montré un taux de réussite de 100 %. L'épaisseur restante de la dentine a augmenté de manière significative dans tous les groupes d'étude après l'application de l'intervention. En outre, la densité de la dentine restante a montré une augmentation significative dans tous les groupes, avec un résultat significativement plus élevée que dans le groupe témoin pour l'application du laser à diode, et sans différence significative entre les autres groupes.

Conclusions: Dans les limites de la présente étude, on peut conclure ce qui suit :

1. L'utilisation de Biodentine dans le coiffage pulpaire indirect est le traitement de choix dans la prise en charge des lésions carieuses profondes.
2. Le fluorure de diamine d'argent peut être utilisé comme matériau alternatif de coiffage indirect de la pulpe.
3. Le laser à diode peut montrer des résultats prometteurs en termes de désinfection des cavités et peut avoir de meilleurs résultats de biomodulation sur la guérison et la réparation des tissus pulpaire.

Mots clés: Biodentine, Fluorure d'argent diamine, Laser à diode, Coiffage pulpaire indirect.

Introduction

A better understanding of the caries process has led to major changes in the management of carious lesions [1]. In order to avoid additional caries recurrence and treatment failure, earlier treatment techniques aim for complete non-selective removal till reaching hard dentin [2]. However, this method leads to unnecessary pulp exposure during excavation, necessitating the use of additional therapeutic treatments such pulp capping or even endodontic therapy [3, 4]. Indirect pulp capping, which removes only soft demineralized and infected dentin, has been adopted in the management of carious lesions in order to prevent direct pulp capping or root canal treatment [4]. The dentin pulp complex is then restored with a suitable restorative material to stop microleakage, which is followed by the insertion of a biocompatible substance that promotes healing [5].

For many years, calcium hydroxide has been regarded as the “gold standard” of pulp capping materials because of its superior anti-bacterial qualities and capacity to promote the production of hard tissue [6]. However, it has a poor seal, extremely soluble and is susceptible to disintegration over time [7]. The development of so-called “tunnel defects” in reparative dentin formed underneath calcium hydroxide is another disadvantage related with calcium hydroxide [7].

As a result, a number of additional substitute materials are now utilized for indirect pulp treatment. Indirect pulp capping agent Mineral Trioxide Aggregate (MTA) has emerged as one of the most effective of these. A relatively recent calcium silicate-based cement with characteristics comparable to MTA is called Biodentine (Septodont, USA). As a result, Biodentine is also marketed as having potential as an indirect pulp capping agent [7].

Previous studies have shown that caries process become arrested in the remaining contaminated den-

tin, as cariogenic bacteria become nonviable due to absence of the substrate [8]. Despite these, it cannot be completely claimed whether the remaining bacteria or their metabolites have any detrimental effects on the pulp or not [9, 10]. As there is still controversy regarding the fate of microorganisms, some studies claimed that such bacteria could persist under the restoration affecting the success of the treatment [11].

Therefore, several additional approaches for arresting the remaining affected dentin, could be crucial clinically. With the advent of technology and quest for newer material has prompted the clinicians to explore the remineralizing abilities of various other materials. Silver Diamine Fluoride (SDF) has been employed as an alternative treatment for caries prevention and arrest, and interest in its use has been expanding [12]. Previous research has shown that SDF raises the pH of biofilm, lowers dentin demineralization, and acts as an antibacterial agent against cariogenic bacteria [13]. The use of SDF as an indirect pulp capping material has also been shown to exhibit no pulpal inflammatory response and to detect the production of tertiary dentin under a histological analysis [13].

Since the middle of the 1990s, the use of lasers has been widely spread in the field of dentistry. Diode lasers stand out from other types of lasers because to its compact design, lower price when compared to other lasers, smaller size, and diverse additions. It is typically employed for soft tissue operations in dentistry [1].

Diode laser disinfection of root canals has demonstrated promising results, outperforming the range of any other chemical disinfectant. Diode lasers can eliminate bacteria up to 500 μm depth in dentin, as opposed to chemical agents, which can only reach 100 μm deep, according to Gutknecht et al [14]. Additionally, a recent study found that Diode lasers can be employed safe-

ly as an alternate method for cavity disinfection because their temperature rise is shown to be below the pulp's critical threshold [15].

It is additionally claimed that diode laser has the capacity to biomodulate the metabolic activity of cells that resemble odontoblasts, hence promoting the formation of mineralized nodules. Additionally, it increases fibroblast growth factor production and decreases the generation of inflammatory mediators, which accelerates the healing and remodeling processes [16]. Better clinical outcomes could result from all these diode laser's possible uses.

However, limited studies are available regarding the necessity and efficacy of Diode laser in management of deep carious lesions. Therefore, a randomized clinical trial comparing the preservation of pulp vitality by indirect pulp capping using Diode laser and Silver Diamine Fluoride in management of deep carious lesions might be of value. The research null hypothesis was that there's no difference between the effect of indirect pulp capping using Diode laser or Silver Diamine Fluoride in maintaining pulp vitality compared to the usage Biodentine in management of deep carious lesions in permanent teeth.

Methods

The following study was approved by the ethical review committee and institutional review board at Misr International University with IRB code: MIU-IRB-2122-226.

1. Sample Size Calculation

Using power analysis, the total sample size for a Chi-square test comparing four groups was calculated. Based on the findings of a prior study [17] and the expectation that Laser Group will offer a success rate of 50%, calculation used success rate as the primary outcome.

The absence of pertinent references led to the formulation of this presumption. The minimum estimated sample size was 24 indi-

viduals, and the effect size (w) was calculated using alpha (α) levels of 0.05 (5%) and beta (β) levels of 0.10 (10%), i.e., power = 90%.

A 20% dropout rate was made up for by adding an additional 30 individuals. Thus, there will be 10 subjects in each group. G*Power software (Version 3.1.9.2; Heinrich-Heine-Universität Düsseldorf, Germany) was used to calculate sample size.

2. Study Design & Settings

This randomized controlled clinical trial study was carried on 30 patients with an age range of 18 -46 years. This trial was reported following the Consolidated Standards of Reporting Trials (CONSORT) guidelines to ensure transparent and complete reporting [18].

3. Sample selection:

a) Criteria of patient selection [6]: Inclusion criteria:

Patients included in this study were between 18-50 years old, able to tolerate necessary restorative procedures, accepting the 6 months follow-up period, having asymptomatic vital permanent posterior teeth with occlusal primary deep carious lesions involving 2/3 of the entire dentin thickness, as assessed using bitewing radiograph [5]. One tooth per patient was enrolled into the study.

Exclusion criteria:

Medically compromised patients, pregnant women, patients showing allergy to any of the restorative materials, and anesthetics, and uncooperative patients were excluded from the study.

In Addition, teeth with previous restorations, spontaneous pain, or prolonged pain after sensitivity tests (cold and electrical tests), teeth with periapical radiolucencies and sensitivity to percussion were also excluded.

b) Criteria for discontinuing or modifying intervention:

If patients showed any signs of severe postoperative pain, the res-

toration was removed, and endodontic treatment or extraction was performed.

4. Allocation & Randomization:

Computer generated randomization for sequence was held at the 1st visit. Randomization was performed through computed software (www.randomizer.org (Copyright© 1997-2021 by Geoffrey C. Urbaniak and Scott Plous)).

The number corresponding to each treatment procedure was recorded on cards kept inside sequentially numbered, opaque, sealed envelopes.

5. Blinding:

This trial was Single blinded as only the Outcome assessors were blinded. Both, the participants, and principal investigator were not blinded owing to the use of obviously different methods; laser, and Silver Diamine Fluoride.

6. Sample grouping:

All patients were randomly divided into three equal groups:

Group 1 (Control): patients with deep carious teeth received conservative caries management (selective caries removal to firm dentin) and then Biodentine (Septodont, USA) was placed followed by the final restoration.

Group 2: patients with deep carious teeth received conservative caries management (selective caries removal to firm dentin) and then single application of Diode laser (EPIC X™, BIOLASE, USA) with 940 nm and an output power of 0.5 watt to the cavity was performed. Then the teeth were restored with Biodentine and the final restoration.

Group 3: patients with deep carious teeth received conservative caries management (selective caries removal to firm dentin) and then Silver Diamine Fluoride (Riva star, SDI, UK) was applied with a micro-tip applicator for 15 seconds to the floor of the cavity, following the manufacturer instructions. The teeth were then restored with Biodentine and the final

restoration.

7. General Operative procedures:

The procedures involved performing conservative caries management with or without using either Diode laser or Silver Diamine Fluoride for one tooth per patient. Patients were randomly allocated into one of the three study groups using computer software (www.randomizer.org). The same final restorative materials were used in all groups, so that the outcome would only reflect the effect of the technique used.

Each patient was assessed for eligibility, the procedures were explained to him/her and the consent form was signed. Preoperative clinical assessment and periapical radiographs were performed before starting the procedures. Local anesthesia (Artinibsa 4% 1:100.000, Inibsa Dental S.L.U, Spain) was administered and the tooth was isolated with a rubber dam (Sanctuary™ Dental Dam, Perak, Malaysia). Access to the lesion was gained with a sterile high-speed bur (#245 bur, Meisinger GmbH, Germany), using a high-speed handpiece (Pana Air®, NSK, Japan). Selective caries removal to firm dentin strategy was performed following the guidelines published by the International Caries Consensus Collaboration (7).

Caries was completely removed from the surrounding cavity walls, leaving at least 2 mm rim of peripheral sound tooth structure for good adaptation and seal to the restoration [19]. Superficial necrotic carious fragments, that deform when an instrument is pressed into it and can be easily scooped up with little force being required, were removed from the pulpal floor using a sharp sterile excavator, while affected firm dentin was left on the floor to avoid pulpal exposure [7].

8. Intervention Application:

Group 1 (Control):

After caries removal, Biodentine (Septodont, USA) was mixed according to the manufacturer's instruc-

tions and uniformly placed over the floor of cavity, then the cavity was restored with the final restoration.

Group 2:

The cavity was then disinfected using Diode laser (EPIC X™, BIO-LASE, USA) with 940 nm and an output power of 0.5 watt. A 400 μm noninitiated tip was used for cavity irradiation, in a noncontact mode (2mm distance), 5 sec/mm² in sweeping motion, with energy density 690.60 J/cm² [15] (Figure 1).

Group 3:

Silver Diamine Fluoride (Riva star, SDI, UK) was applied for 15 seconds to the floor of the cavity, following the manufacturer instructions.




Figure 1: Diode laser with an output power 0.5 Watt

9. Restorative Procedure:

The cavity was first filled with Biodentine material (Septodont, USA) following the manufacturer's instructions as an indirect pulp capping material, leaving a space 2mm distance for the final restoration. Then selective etching of enamel was performed using 35% phosphoric acid gel (Scotchbond™ Universal Etchant, 3M ESPE, Deutschland GMBH, Germany) for 15 seconds, rinsed for 15 seconds with water, and gently air dried for 5 seconds., followed by application of

a single layer of universal adhesive (Single Bond Universal, 3M ESPE, Germany), then light cured using LED light curing unit (Elipar™ S10, 3M ESPE, USA) according to the manufacturer's instructions.

Resin composite (Filtek Z250, 3M ESPE, USA) was then applied in approximately 2 mm increments and each increment was light cured for 20 seconds, then the final increment was light cured for 40 seconds following the manufacturer's instructions. Occlusion was checked using an articulating paper (Blue Red Combo 0.0035"/89 μm, Crosstex® International, USA), and high spots were removed.

10. Post-operative instructions and follow-up:

Patients received postoperative instructions and oral hygiene guidelines that should be followed during the follow-up period. After three months patients recalled to follow-up the pulp vitality and restoration condition. Follow-up was performed after 3 and 6 months. Assessment of criteria for success was performed by the outcome investigators according to the evaluation chart.

11. Clinical and Radiographic Evaluation:

Upon completing the intervention, the patients were recalled after 3 and 6 months to assess outcome. Regarding the primary outcome, in previous studies the authors used a binary variable indicating whether the restored tooth maintained its

vitality at the outcome investigation time [21]. Success requires positive results in all five tests mentioned here. Clinical success was evaluated by: Cold pulp testing: using a refrigerant spray (Hygenic® Endo-Ice®; Coltene, Ohio, USA), Absence of postoperative pain, Sensitivity to percussion, Inspection for Sinus/ fistula /swelling: using visual inspection (positive/negative).

Radiographic evaluation was done using Cone Beam Computed Tomography at immediate postoperative: Cranex 3D, Soredex, Finland CBCT machine was used to assess the dentin thickness by using the linear measurement tool and measuring the distance from the base of restoration to the pulp on sagittal, coronal, or cross-sectional images generated from CBCT scans after orientation of the orthogonal planes using the software vertical and horizontal reference lines (Figure 2a). Radiographic density of remaining dentin was calculated using the density measurement tool for the same area (Figure 3a). The exposure parameters used are (5cm*5cm) field of view, 8 mA, 90 KvP, 0.085mm voxel size and the software used (ONDemand 3D). At Six months post-operative, CBCT scan was performed using same machine as immediate postoperative with the same exposure parameters and same linear and density measurements evaluated after generating the same images from the software using the software vertical and horizontal reference lines for standardization (Figure 2b & 3b).

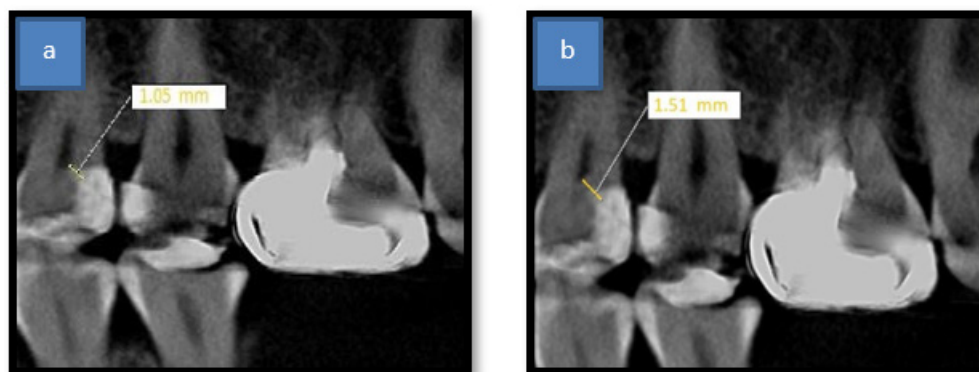


Figure 2: a) CBCT measurement of immediate post-operative remaining dentin thickness, b) CBCT measurement of Six months post-operative remaining dentin thickness

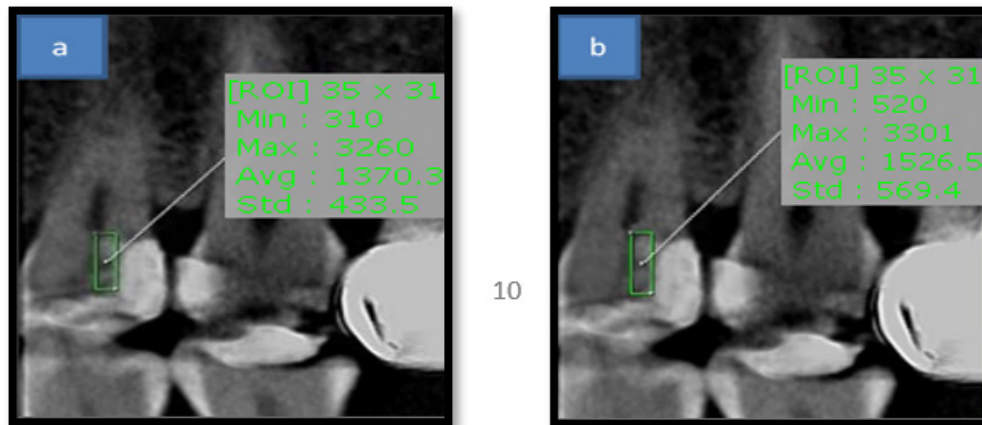


Figure 3: a) CBCT measurement of immediate post-operative remaining dentin density, b) CBCT measurement of Six months post-operative remaining dentin density

12. Statistical Analysis:

Clinical and Radiographic data were collected, tabulated, checked for normality and statistically analyzed to compare between the performance of Diode laser and Silver Diamine Fluoride.

Numerical data were explored for normality by checking the distribution of data and using tests of normality (Kolmogorov-Smirnov and Shapiro-Wilk tests). SPSS version 23.0 was used for data management and data analysis. Median and range when appropriate described quantitative data. Where data were non-normally distributed, the Wilcoxon Signed Ranks Test for paired comparisons and Kruskal-Wallis Test for more than two study groups comparisons. P value was two tailed and considered significant at 0.05 level.

Results

1. Results of Clinical Assessment:

Results of clinical assessment for all groups have shown success rate of 100%, as there was positive response to cold pulp testing, absence of postoperative pain, pain on percussion, swelling, fistula or sinus during all follow-up periods.

2. Results of Cone Beam Computed Tomography Assessment:

2.1. Remaining Dentin Thickness assessment:

The results of remaining dentin thickness at immediate postoperative assessment showed non-significant difference between the three groups, with a P value of 0.445. While group 2 (application of Diode laser with an output power of 0.5watt) have shown the highest

increase in the remaining dentin thickness at six months post-operative assessment, with no statistical significance among other groups, with a P value of 0.466. However, the paired comparison of remaining dentin thickness between immediate and six months postoperative assessment showed significant increase in each group (Table 1, Figure 4).

2.2. Remaining Dentin Density assessment:

The current study showed that there was non-significant difference between studied groups in remaining dentin density at immediate postoperative assessment. The p value between the three studied groups at immediate postoperative assessment was 0.111 (statistically insignificant difference). However,

Table 1: Remaining Dentin thickness assessment among the study groups:

	Dentin Thickness Before		Dentin Thickness After		p-value (paired comparison)
	Median	Range	Median	Range	
Group 1	2.03	1.77-2.37	2.52	2.27-2.88	0.011*
Group 2	2.04	1.56-2.24	2.55	2.09-2.78	0.011*
Group 3	1.98	1.61-2.14	2.47	2.07-2.62	0.011*
p-value (between groups)	0.445		0.466		

*P value is significant ≤ 0.05

Table 2: Remaining dentin density assessment among the study groups:

	Dentin Density Before		Dentin Density After		p-value (paired comparison)
	Median	Range	Median	Range	
Group 1	591.00	529.44-619.12	890.59 b	852.62-960.42	0.012*
Group 2	645.31	550.18-741.28	993.57 ^a	900.11-1081.24	0.012*
Group 3	650.26	542.08-792.56	924.36 ^{ab}	816.95-1063.32	0.012*
p-value (between groups)	0.111		0.030*		

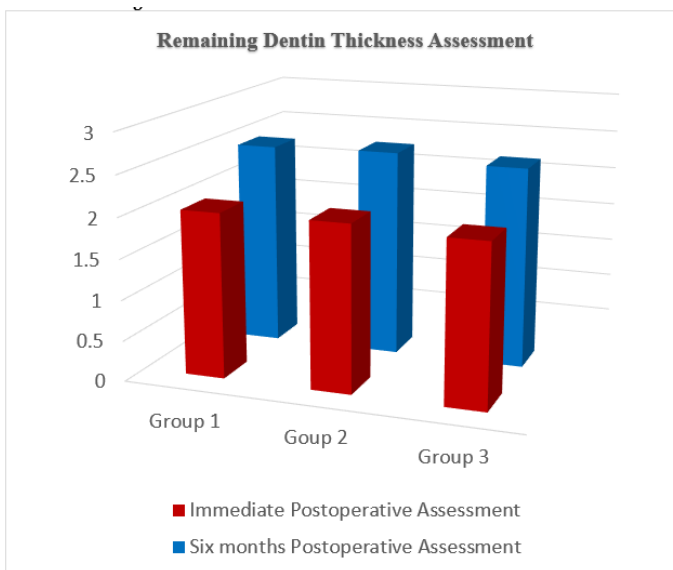


Figure 4: Bar chart showing remaining dentin thickness assessment among the study groups.

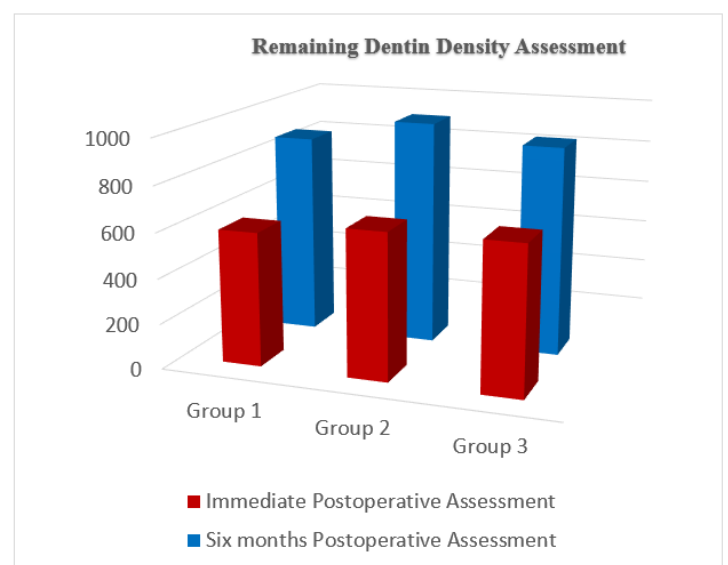


Figure 5: Bar chart showing remaining dentin density assessment among the study groups.

the p value between the three studied groups at six months postoperative assessment was 0.030* (statistically significant difference), where group 2 (application of Diode laser with an output power of 0.5watt) was significantly higher than group 1 (control), with no significant difference between the other group. While the paired comparison of remaining dentin density between immediate and six months postoperative assessment showed significant increase in each group (Table 2, Figure 5).

Discussion

Invasive treatment strategies, such as one-step full caries removal, pose a considerable risk to the pulpal health of the tooth, including pulpal exposure, when treating deep carious lesions in teeth with a healthy pulp. These invasive strategies assume that pulp vitality will deteriorate in the future, and that root canal treatment will be necessary. Although this strategy may be highly effective, it is more burdensome and costly on an individual and societal level, particularly in low

and middle-income countries. As a result, some patients may agree to tooth extraction, in order to avoid the cost of lengthy and expensive restorative dental treatments [5].

To reduce unwanted pulpal exposure, indirect pulp capping modality have been adopted. The main objective of the indirect pulp treatment is to maintain the vitality of teeth with reversible pulp injury. The rationale for this treatment modality is based on the observation that reduction in bacterial counts can help in utilizing the healing potential of odontoblasts which results in deposition of tertiary dentin matrix or sclerotic

dentin [22]. This is mediated by the activation of endogenous signaling molecules, which are present at the dentinal matrix and are solubilized by various agents used for indirect pulp treatment [23].

Calcium hydroxide-based compounds have been utilized extensively as therapeutic agents for Indirect Pulp Capping and other procedures since they were first introduced by Hermann in 1930. Pyrophosphatase activity is increased by the release of calcium, which helps to maintain dentin mineralization and create dentin bridges. Considering newer materials, like as mineral trioxide aggregate (MTA), which exhibits outstanding promise in endodontic applications such direct pulp capping, was prompted by the limitations of calcium hydroxide. However, it is relatively more expensive, has a delayed setting time, initial looseness, and poor handling characteristics [24].

The search for an ideal material for lining deep cavities is a matter of ongoing research. Need to evaluate different types of materials clinically and compare them with each other cannot be overemphasized. A novel bioactive calcium silicate-based cement called Biodentine has just been introduced as a replacement for dentin. This new biologically active material aids its penetration through opened dentinal tubules to crystallise and interlock with dentin and give mechanical qualities. It was performed using cement technology based on the MTA, and it exhibits benefits in various characteristics including physical quality and handling [25].

Regardless of the deep caries management strategy, it is essential to actively reduce the amount of bacteria in infected dentin to guarantee the long-term vitality of the tooth [26]. In this study, the remaining carious dentin was treated using either Diode laser with an output power (0.5 watt) or Silver Diamine Fluoride.

Silver Diamine Fluoride (SDF), a recently proposed indirect pulp cap-

ping substance, releases high fluoride and encourages the formation of reparative dentin. The original purpose of silver diamine fluoride (SDF) was as a cariostatic. Its effectiveness in the treatment and prevention of caries has been shown in several clinical investigations [27]. SDF aids in the deposition of silver phosphate to regain mineral content, which causes the tooth structure to reharden. Fluoride is also released [28].

Diode laser is gaining popularity in recent years and is considered to be a breakthrough in the field of dentistry as it enables dentists to perform many dental treatments in a faster and more efficient way [29]. It has a role in different procedures including soft tissue procedures mainly gingivectomy, frenectomy, gingival depigmentation, and many other surgeries. It is also used in teeth desensitization and whitening [30].

Regarding its antimicrobial effect, diode laser has its widespread application in periodontal pockets disinfection and endodontic treatment owing to its ability to eliminate any remaining viable bacteria with great efficacy [31].

This antimicrobial effect, known as the photothermal effect, is based on a rise in temperature that kills off bacterial cells [32]. Additionally, it is important to note that superior clinical outcomes have been demonstrated when employing diode lasers with different parameters in studies for direct pulp capping that fall within the safe limits as suggested by Gutknecht et al 2005 [33]. As said, the advantage of diode laser is that it promotes greater pulpal tissue repair and healing [35]. In order to evaluate its potential and capacity to promote the formation of reparative dentin, cavity disinfection in the current study was carried out using a diode laser with an output power of (0.5 watt [15]).

Regarding methods of assessment performed in the present study, clinical assessment with combined binary outcome (success/fail-

ure) for evaluation, was carried out mainly using pulp vitality test (cold test), along with percussion test and visual assessment of signs of failure like swelling, sinus or fistula. It is emphasized that any conclusions should be interpreted with the idea that only histologic procedures are capable of conclusively diagnosing pulpal health, which is not feasible in clinical practice. Without a histologic diagnosis, clinicians must interpret information gathered through reported symptoms, palpation, percussion, radiography, and pulp tests with caution [36]. Cold testing, in conjunction with radiographs, history, and clinical presentation, can provide more reliable information on the clinical success of maintaining pulp vitality [37].

Cone beam computed tomography was used in this study, as another method of assessment. Since the most apparent sign of pulp damage repair is the creation of the tertiary dentin matrix. According to the degree of the elicited response and the conditions under which the new tissue matrix is generated, the process of tertiary dentin deposition can be categorized as reactionary or reparative [38]. A desirable criterion for a vital pulp treatment is that the remineralized tissue develop a thick structure approximating dentin to adequately protect the pulp. Histologic examinations are the sole way to determine the thickness and type of tissue generated [39]. However, this cannot be carried out in a clinical *in vivo* study.

Intraoral periapical radiographs or panoramic imaging were the only means for assessment of reparative dentin formation, there are several limitations for using such techniques [40]. such procedures provide two-dimensional imaging of a three-dimensional structure, that is considered to be an inaccurate method of assessment.

Recently, cone beam computed tomography imaging is a novel and noninvasive approach that enables the examination of tooth tissue without destroying it [41]. In

addition, three-dimensional reconstruction of cone beam computed tomographic images eliminates the superimposition of surrounding structures [42]. So, such technique analyzes the type and quantity of tissue formed with direct and indirect pulp capping treatment in terms of thickness, to assess tertiary dentin formation, and radiodensity, to assess remineralization and thus predict the success of the procedure accurately [43].

Regarding the time of cone beam computed tomography assessment, it was done after 6 months interval. As previous studies have confirmed radiographic increase in the mineral content mostly after 6 months of clinical intervention [44]. Also, in a study performed by Maltz et al., increased radioopacity and reparative dentin formation after indirect pulpal treatment, were significantly observed in the first 6-7 months (no change in radioopacity between 6-7 months and 36-45 months) [45].

Thus, the current study was carried out to compare the preservation of pulp vitality by indirect pulp capping using Diode laser and Silver Diamine Fluoride in management of deep carious lesions. Performing this study might be of great value, since the usage of diode laser could yield to better clinical outcomes in management of deep carious lesions, minimizing the need for root canal treatment. Also, this leads to price reduction by decreasing the number of procedures and visits needed.

Results of the current study regarding the clinical assessment, success rates for all groups were 100% at all follow up periods. The clinical success reported could be attributed to the correct diagnosis, and the sealing of demineralized dentin with a restoration, providing a proper peripheral and coronal seal, depriving bacteria from the oral cavity substrate. Thus, decreasing bacterial load diversity, arresting caries process, allowing time for pulp to heal [3].

This was consistent with earlier research, as Elchaghaby et al. 2020 [46] reported clinical and radiographic success rates of 100% when comparing calcium hydroxide with photoactivated disinfection for indirect pulp treatment of young permanent molars. Additionally, these outcomes were comparable to those reported by Gruythuysen et al. in 2010 [47], who asserted that indirect pulp treatments performed on young patients' primary and permanent teeth have demonstrated great survival rates [47]. This was also in line with Sharma et al.'s findings from 2014 [20], who compared the efficiency of photoactivated disinfection against calcium hydroxide in disinfecting remaining carious dentin in deep cavities and reported successful outcomes for all treated teeth at all follow-up intervals, with only one tooth being considered a failure.

According to the findings of the current study, all three study groups showed a considerable increase in residual dentin thickness following the application of the intervention, with no statistically significant differences between the groups. This could be explained by the fact that, independent of the technique used, Biodentine was used in all groups as an indirect pulp capping material, which contributed to the increase in tertiary dentin development. This can be explained by the superior qualities of Biodentine as a dentine substitute, as it can promote odontoblastic activity and reparative dentin formation through the induction of cell differentiation, making it completely biocompatible and able to induce the apposition of the reactionary dentin [25].

While regarding the results of the remaining dentin density, the findings of the current study showed significant increase in three study groups, where group 2 (application of Diode laser with an output power of 0.5watt) was significantly higher than group 1 (control), with no significant difference between the other group. This was consistent with oth-

er in vitro and in vivo investigations that found laser aided pulp capping to have important advantages over conventional methods [48]. Diode laser also has a bio-stimulation impact, which includes reducing inflammation and discomfort, increasing cell growth, cyto-differentiating odontoblastic-like cells, producing dentin extracellular matrix, and creating reparative dentin [49]. These findings were also in agreement with other studies that supported the biostimulatory role of laser therapy on odontoblastic like cells enhancing dentinogenesis [50-53].

Due to its efficiency in reducing the microbial load in the remaining infected dentin and the fact that the temperature rise is below the pulp's critical threshold, diode laser has also been mentioned in the literature as a safe alternative strategy for cavity disinfection [15, 54, 55]. Our study's findings were in line with earlier studies' findings that diode laser is an efficient cavity disinfection and a cutting-edge strategy for treating primary deep caries [56-59].

The primary mechanisms of this antibacterial activity are the thermal and photodisruptive effects of the diode laser, which kill bacteria by destroying the integrity of their cell walls and denaturing their proteins because cellular proteins are extremely sensitive to thermal changes [56, 1, 60]. Additionally, it causes the water inside the tubules to expand and compress as deeply as possible, which might result in an acoustic wave powerful enough to disturb bacteria [1, 57].

Such effectiveness might attribute to better outcomes, by eradication of the remaining cariogenic bacteria in the infected dentin, which could allow better pulp repair and reparative dentin formation. However, there is lack of evidence concerning the long-term therapeutic effectiveness of diode laser in the treatment of deep caries lesions.

Group 3 (indirect pulp capping using Silver Diamine Fluoride) demonstrated acceptable results in terms of remaining dentin density, which

was consistent with earlier studies that suggested Silver Diamine Fluoride could create an alkaline environment to make CaF₂ less soluble, acting as a fluoride reservoir for acid challenges by cariogenic bacteria, preventing demineralization of hydroxyl apatite, and protecting collagen from deterioration in demineralized tissues [61].

Additionally, it has the ability to greatly enhance dentin hardness and decrease dentin collagen degradation [62]. Because silver ions may interact with negatively charged peptidoglycans in bacterial cell walls and impair membrane transport function, which in turn causes cellular deformities and loss of viability, silver diamine Fluoride also exhibits antibacterial characteristics [12]. Additionally, fluoride ions can

promote the growth and alkaline phosphatase activity of human dental pulp cells at low concentrations, which in turn results in the production of reparative dentin [13].

Based on the findings of the current study, the null hypothesis was rejected. These could still favor the usage of diode laser in management of deep carious lesion, because of its promising results, that might lead to better clinical outcomes.

Limitations of the study include enrollment of patients meeting the inclusion criteria, compliance of patients for the follow-up periods, the short-term follow-up period, so further long-term evaluation of the clinical success with larger sample size should be performed.

Conclusions

Within the limitations of the current study, the following can be concluded:

1. Using Biodentine in indirect pulp capping is the treatment of choice in management of deep carious lesions.
2. Silver Diamine Fluoride can be used as an alternative indirect pulp capping material.
3. Diode laser can show promising results in terms of cavity disinfection & can have better biomodulating outcomes on the pulpal tissue healing and repair.

Informed consent: informed consents were obtained from all participants included in the study.

References

1. Uday Mohan PVM, Uloopi S, Vinay C, Chandrasekhar Rao R. In Vivo Comparison of Cavity Disinfection Efficacy with APF gel, Propolis, Diode laser, and 2% Chlorhexidine in Primary Teeth. *Contemp Clin Dent.* 2016; 7(1):45–50.
2. Cieplik F, Buchalla W, Hellwig E, Al-Ahmad A, Hiller K-A, Maisch T. Antimicrobial Photodynamic Therapy as An Adjunct for Treatment of Deep Carious Lesions-A systematic review. *Photodiagnosis Photodyn Ther.* 2017;18:54–62.
3. Ricketts D, Lamont T, Innes N, Kidd EAM, Clarkson JE. Operative Caries Management in Adults and Children. *CDSR.* 2013;(3):1–52.
4. Thompson V, Craig RG, Curro FA, Green WS, Ship JA. Treatment of Deep Carious Lesions by Complete Excavation or Partial Removal: A Critical Review. *J Am Dent Assoc.* 2008;139(6):705–12.
5. Bjørndal L, Reit C, Bruun G, Markvart M, Kjaeldgaard M, Näsman P. Treatment of Deep Caries Lesions in Adults: Randomized Clinical Trials Comparing Stepwise vs. Direct Complete Excavation, and Direct Pulp Capping vs. Partial Pulpotomy. *Eur. J. Oral Sci.* 2010;118(3):290–7.
6. Nowicka A, Lipski M, Parafiniuk M, Sporniak-Tutak K, Lichota D, Kosierkiewicz A, et al. Response of human dental pulp capped with Biodentine and mineral trioxide aggregate. *J. Endod.* 2013;39(6):743-747.
7. George V, Janardhanan SK, Kumaran P, Xavier AM. Clinical and radiographic evaluation of indirect pulp treatment with MTA and calcium hydroxide. *J Indian Soc Pedod Prev Dent.* 2015;33(2):104-110.
8. Franzon R, Guimarães LF, Magalhães CE, Haas AN, Araujo FB. Outcomes of One-Step Incomplete and Complete Excavation in Primary Teeth: A 24-Month Randomized Controlled Trial. *Caries Res.* 2014;48(5):376–83.
9. Carvalho JC, Dige I, Machiulskiene V, Qvist V, Bakhshandeh A, Fatturi-Parolo C, et al. Occlusal Caries: Biological Approach for Its Diagnosis and Management. *Caries Res.* 2016;50(6):527–42.
10. Innes NPT, Frencken JE, Bjørndal L, Maltz M, Manton DJ, Ricketts D, Landuyt K Van, Banerjee A, Campus G, Doméjean S, Fontana M, Leal S, Lo E, Machiulskiene V, Schulte A, Splieth C, Zandona A, Schwendicke F. Managing Carious Lesions: Consensus Recommendations on Terminology. *Adv. Dent. Res.* 2016;28(2):49–57.
11. Duque C, de Cássia Negrini T, Tomoko Sacono N, Fabiano Gomes Boriollo M, Francisco Hoffling J, Hebling J. Genetic Polymorphism of Streptococcus Mutans Strains Associated with Incomplete Caries Removal. *Braz. J. Oral Sci.* 2009;8(1):2-8.
12. Chu CH, Mei L, Seneviratne CJ, Lo ECM. Effects of silver diamine fluoride on dentine carious lesions induced by Streptococcus mutans and Actinomyces naeslundii biofilms. *Int J Paediatr Dent.* 2012;22(1):2-10.
13. Korwar A, Sharma S, Logani A, Shah N. Pulp response to high fluoride releasing glass ionomer, silver diamine fluoride, and calcium hydroxide used for indirect pulp treatment: An in-vivo comparative study. *Contemp Clin Dent.* 2015;6(3):288-292.
14. Gutknecht N, Franzen R, Schippers M, Lampert F. Bactericidal Effect of a 980-nm Diode Laser in the Root Canal Wall Dentin of Bovine Teeth. *J Clin Laser Med Surg.* 2004;22(1):9–13.
15. Mirzaie M, Yassini E, Ashnagar S, Hadadi A, Chini-forush N. Evaluation of Temperature Change during Antimicrobial Photodynamic Therapy with Two Different Photosensitizers in Dental Caries. *Photodiagnosis Photodyn Ther.* 2016;14:115–8.
16. Bidar M, Moushekhian S, Gharechahi M, Talati A, Ahrari F, Bojarpour M. The Effect of Low-Level Laser Therapy on Direct Pulp Capping in Dogs. *J Lasers Med Sci.* 2016;7(3):177–83.
17. Ali AH, Koller G, Foschi F, Andiappan M, Bruce KD, Banerjee A, Mannocci F. Self-Limiting versus Conventional Caries Removal: A Randomized Clinical Trial. *J. Dent. Res.* 2018;97(11):1207-1213.
18. Moher D, Hopewell S, Schulz KF, Montori V, Gotzsche PC, Devereaux PJ. CONSORT 2010 explanation and elaboration: updated guidelines for reporting parallel group randomised trials. *Int. Surg. J.* 2012;10(1):28-55.
19. Hayashi M, Fujitani M, Yamaki C, Momoi Y. Ways of Enhancing Pulp Preservation by Stepwise Excavation--A Systematic Review. *J. Dent.* 2011;39(2):95–107.
20. Sharma S, Logani A, Shah N. Comparative Efficacy of Photo-Activated Disinfection and Calcium Hydroxide for Disinfection of Remaining Carious Dentin in Deep Cavities: A Clinical Study. *Restor. Dent. Endod.* 2014;39(3):195–200.
21. Borges FMC, de Melo MAS, Lima JPM, Zanin ICJ, Rodrigues LKA. Antimicrobial Effect of Chlorhexidine Digluconate in Dentin: In vitro and In Situ Study. *J. Conserv. Dent.* 2012;15(1):22–26.
22. Venkatesh N, Kavyashree B, Amitha H A. Comparative Assessment Of Success Rate Of Indirect Pulp Treatment With 2% Chlorhexidine Gluconate Disinfecting Solution, Calcium Hydroxide And Resin Modified Glass Ionomer Liner In Primary Teeth - A Prospective Study. *IOSR-JDMS.* 2016;15(2) 45-53.

23. Singhal M, Chaudhary CP, Anand R, Singh N, Sahni T. Recent Advancements Of Indirect Pulp Capping In Primary Teeth: A Review. *J Adv Med Dent Sci Res*. 2015;3(5):5.
24. Mohammadi Z, Dummer P. Properties and Applications of Calcium Hydroxide in Endodontics and Dental Traumatology. *Int Endod J*. 2011;44(8):697-730.
25. Hashem D, Mannoci F, Patel S, Manoharan A, Watson TF, Banerjee A. Evaluation of The Efficacy of Calcium Silicate vs Glass Ionomer Indirect Pulp Capping and Restoration Assessment Criteria: A Randomized Controlled Clinical Trial-2-Year Results. *Clin. Oral Investig*. 2019;23(4):1931-1939.
26. Haapasalo M, Orstavik D. In Vitro Infection and Disinfection of Dentinal Tubules. *J. Dent. Res*. 1987;66(8):1375-1379.
27. Shen Q, Sun J, Wu J, Liu C, Chen F. An in vitro investigation of the mechanical-chemical and biological properties of calcium phosphate/calcium silicate/bismutite cement for dental pulp capping. *J Biomed Mater Res B Appl Biomater* 2010;94B(1):141-8.
28. Gupta A, Sinha N, Logani A, Shah N. An ex vivo study to evaluate the remineralizing and antimicrobial efficacy of silver diamine fluoride and glass ionomer cement type VII for their proposed use as indirect pulp capping materials - Part I. *J Conserv Dent*. 2011;14(2):113-6.
29. Matar LAR, Dowidar KML, Talat DM, Kholief DA. Effectiveness of Chlorhexidine as A Cavity Disinfectant in Atraumatic Restorative Treatment in Primary Teeth (Randomized Controlled Clinical Trial). *Alex. dent. j*. 2021;46(2):178-184.
30. Liu JX, Werner J, Kirsch T, Zuckerman JD, Virk MS. Cytotoxicity Evaluation of Chlorhexidine Gluconate on Human Fibroblasts, Myoblasts, and Osteoblasts. *JBJS*. 2018;3(4):165-172.
31. Olivi G, Olivi M. Physics of Lasers. *Lasers in Restorative Dentistry: A practical Guide*. 1st ed., Springer-Verlag Berlin Heidelberg. 2015:39-50.
32. Vitale MC, Zaffe D, Botticell AR, Caprioglio C. Diode Laser Irradiation and Flouride Uptake in Human Teeth. *Eur Arch Paediatr Dent*. 2011;12(2):90-92.
33. Lee BS, Lin YW, Chia JS. Bacterial Effects of Diode Laser on Streptococcus Mutans after Irradiation Through Different Thickness of Dentin. *LSM*. 2006;38(1):62-69.
34. Pirnat S, Lukac M, Ihan A. Study of The Direct Bactericidal Effect of Nd:YAG and Diode Laser Parameters Used in Endodontics on Pigmented and Non-Pigmented Bacteria. *Lasers Med Sci*. 2011;26(6):755-761.
35. Gutknecht N, Franzen R, Meister J, Vanweersch L, Mir M. Temperature Evolution on Human Teeth Root Surface After Diode Laser Assisted Endodontic Treatment. *Lasers Med Sci*. 2005;20(2):99-103.
36. Deng Y, Zhu X, Zheng D, Yan P, Jiang H. Laser Use in Direct Pulp Capping: A Meta-Analysis. *J Am Dent Assoc*. 2016;147(12):935-942.
37. Hilton TJ. Keys to Clinical Success with Pulp Capping: A Review of Literature. *Oper. Dent*. 2009;34(5):615-625.
38. Pereira MA, Santos-Júnior RB dos, Tavares JA, Oliveira AH, Leal PC, Takeshita WM, Barbosa-Júnior AM, Bertassoni LEB, Faria-e-Silva AL. No Additional Benefit of Using a Calcium Hydroxide Liner During Stepwise Caries Removal: A Randomized Clinical Trial. *J Am Dent Assoc*. 2017;148(6):369-76.
39. Gopikrishna V, Pradeep G, Venkateshbabu N. Assessment of Pulp Vitality: A Review. *Int. J. Paediatr. Dent*. 2009;19(1):3-15.
40. Pitt Ford TR, Patel S. Technical Equipment for Assessment of Dental Pulp Status. *Endodontic Topics*. 2004;7(1):2-13.
41. Murray PE, Windsor U, Smyth TW, Hafez AA, Cox CF. Analysis of Pulpal Reactions to Restorative Procedures, Materials Pulp Capping, and Future Therapies. *Crit. rev. oral biol. med*. 2002;13(6):509-520.
42. Pitt Ford TR. Pulpal Response to A Calcium Hydroxide Material for Capping Exposures. *Oral Surgery*. 1985;59:194-197.
43. Tyndall DA, Rathore S. Cone-beam CT Diagnostic Applications: Caries, Periodontal Bone Assessment, and Endodontic Applications. *Dent Clin North Am*. 2008;52(4):825-841.
44. Maret D, Molinier F, Braga J, Peters OA, Telmon N, Treil J, Inglese JM, Cossie A, Khan JL, Sixou M. Accuracy of 3D Reconstructions Based on Cone Beam Computed Tomography. *J. Dent. Res*. 2010;89(12):1465-1469.
45. Maret D, Peters OA, Galibourg A, Dumoncel J, Esclassan R, Khan JL, Sixou M, Telmon N. Comparison of The Accuracy of 3-Dimensional Cone Beam Computed Tomography and Micro-Computed Tomography Reconstructions by Using Different Voxel Sizes. *J. Endod*. 2014;40(9):1321-1326.
46. Young SM, Lee JT, Hodges RJ, Chang TL, Elashoff DA, White SC. A Comparative Study of High-Resolution Cone Beam Computed Tomography and Charge-Coupled Device Sensors for Detecting Caries. *Dentomaxillofac Radiol*. 2009;38(7):445-451.
47. Maltz M, De Oliveira EF, Fontanella V, Bianchi R. A Clinical, Microbiologic, and Radiographic Study of Deep Caries Lesions after Incomplete Caries Removal. *Quintessence Int*. 2002;33(2):151-159

48. Maltz M, Oliveira EF, Fontanella V, Carminatti G. Deep Caries Lesions after Incomplete Dentine Caries Removal: 40-Month Follow-Up Study. *Caries Res.* 2007;41(6):493–6.
49. Elchaghaby MA, Moheb DM, El Shahawy OI, Abd Al-samad AM, Rashed MAM. Clinical and Radiographic Evaluation of Indirect Pulp Treatment of Young Permanent Molars Using Photo-Activated Oral Disinfection versus Calcium Hydroxide: A Randomized Controlled Pilot Trial. *BDJ Open.* 2020;6:4.
50. Gruythuysen RJM, Gruythuysen R, van Strijp AJP, van Strijp G, Wu M-K. Long-Term Survival of Indirect Pulp Treatment Performed in Primary and Permanent Teeth with Clinically Diagnosed Deep Carious Lesions. *J. Endod.* 2010;36(9):1490–1493.
51. Olivi G, Genovese MD, Maturo P, Docimo R. Pulp capping: Advantages of Using Laser Technology. *EJPD.* 2007;8(2):89-95.
52. Edurado FP, Bueno DF, De Freitas PM, Marques MM, Passos-bueno MR, Edurado CP, Zaltz M. Stem Cell Proliferation Under Low Intensity Laser Irradiation: A Preliminary Study. *LSM.* 2008;40(6):433-438.
53. Bjordal JM, Johnson MI, Iversen V, Aimbire F, Lopes-Martins RA. Low-Level Laser Therapy in Acute Pain: A Systematic Review of Possible Mechanisms of Action and Clinical Effects in Randomized Placebo-Controlled Trials. *Photomed Laser Surg.* 2006;24(2):158-168.
54. De Almeida LF, Basso FG, Turrioni APS, De-Souza CCA, Hebling J. Metabolic Activity of Odontoblast-Like Cells Irradiated with Blue LED (445 nm). *Lasers Med Sci.* 2016;31(1):119-125.
55. Huang GT, Gronthos S, Shi S. Mesenchymal Stem Cells Derived from Dental Tissues vs Those from Other Sources: Their Biology and Role in Regenerative Medicine. *J. Dent. Res.* 2009;88(9):792-806.
56. Emelyanov AN, Kiryanova VV. Photomodulation of Proliferation and Differentiation of Stem Cells by The Visible and Infrared Light. *Photomed Laser Surg.* 2015;33(3):164-174.
57. Nammour S, Zeinoun T, Bogaerts I, Lamy M, Geerts SO, Bou Saba S. Evaluation of Dental Pulp Temperature Rise During Photo-Activated Decontamination (PAD) of Caries: An In Vitro Study. *Lasers Med Sci.* 2010;25(5):651–4.
58. Jain S, Mathur S, Jhingan P, Sachdev V. Evaluation of Temperature Rise and Efficacy of Cavity Disinfection with Diode Laser: An In Vivo Study. *J. Conserv. Dent.* 2019;22(6):583-587.
59. Taha MY, Al-habeeb A, Nayif M. Antibacterial Effects of Diode Laser and Chlorhexidine gluconate on *Streptococcus mutans* in Coronal Cavity. *WMCD.* 2013;4(8):WMC004179.
60. Safan A, Youssef T, Zaazou MH, El-Moez SIA, El-Shinawy H, Sadony DM. Antibacterial Effect of Silver and Gold Nanoparticles and Diode Laser Against *Lactobacillus Acidophilus* Bacteria. *Int. j. adv. res.* 2014;2(8):34-38.
61. Mei ML, Chu CH, Lo ECM, Samaranayake LP. Fluoride and silver concentrations of silver diammine fluoride solutions for dental use. *Int J Paediatr Dent* 2013;23(4):279-85.
62. Mei ML, Li QL, Chu CH, Yiu CKY, Lo ECM. The inhibitory effects of silver diamine fluoride at different concentrations on matrix metalloproteinases. *Dent Mater.* 2012;28(8):903-908.