

2-12-2017

## Ex vivo comparative study between four endodontic instruments used to prepare long oval canals

Ali MAROUF

Follow this and additional works at: <https://digitalcommons.aaru.edu.jo/iajd>

---

### Recommended Citation

MAROUF, Ali (2017) "Ex vivo comparative study between four endodontic instruments used to prepare long oval canals," *International Arab Journal of Dentistry*. Vol. 8: Iss. 2, Article 3.  
Available at: <https://digitalcommons.aaru.edu.jo/iajd/vol8/iss2/3>

This Scientific Article (Research Note) is brought to you for free and open access by Arab Journals Platform. It has been accepted for inclusion in International Arab Journal of Dentistry by an authorized editor. The journal is hosted on [Digital Commons](#), an Elsevier platform. For more information, please contact [rakan@aar.edu.jo](mailto:rakan@aar.edu.jo), [marah@aar.edu.jo](mailto:marah@aar.edu.jo), [u.murad@aar.edu.jo](mailto:u.murad@aar.edu.jo).

## EX VIVO COMPARATIVE STUDY BETWEEN FOUR ENDODONTIC INSTRUMENTS USED TO PREPARE LONG OVAL CANALS

Ali Marouf\*

### Abstract

The aim of this study was to compare the shaping ability of ProTaper rotary instruments (Universal), ProTaper rotary instruments (Next), hand ProTaper instruments and traditional NiTi hand instruments in long oval-shaped root canals.

Forty human teeth with long oval-shaped root canals were sectioned at one level in the apical third, 3 mm from the apex. A modified Bramante technique was used; changes in the surface area ( $\Delta A$ ) of the root canal were analyzed. The sample was divided into four sub-groups of 10 teeth. Each group was prepared using one of the four instrumentation systems. The morphological changes were analyzed using a software program (AutoCAD 2013). The data were subjected to an ANOVA one-way test with a significance level of  $p < 0.05$ . The changes in the surface area of the apical third of the treated teeth were not statistically significant among the four groups.

**Keywords:** Long oval canal - k file - ProTaper instruments.

IAJD 2017;8(1):15-19.

## ÉTUDE COMPARATIVE EX VIVO ENTRE QUATRE INSTRUMENTS ENDODONTIQUES UTILISÉS POUR PRÉPARER LES LONGS CANAUX DE FORME OVALE

### Résumé

L'objectif de cette étude était de comparer la capacité de mise en forme des instruments rotatifs ProTaper, des instruments ProTaper manuels et des instruments NiTi manuels traditionnels dans de longs canaux radiculaires de forme ovale. Quarante dents humaines présentant cette morphologie radiculaire ont été sectionnées à 3 mm de l'apex. La technique de Bramante modifiée a été utilisée et les variations de la surface canalaire ont été analysées à un grossissement  $\times 10$ . L'échantillon a été divisé en quatre sous-groupes contenant chacun 10 dents, et les dents de chaque groupe ont été traitées par l'un des quatre systèmes d'instrumentation sélectionnés. Les modifications morphologiques ont été analysées par le programme logiciel (AutoCAD 2013). Le test ANOVA utilisé n'a pas montré de différences significatives entre les quatre groupes.

**Mots clés:** canal oval long - lime k - instruments ProTaper.

IAJD 2017;8(1):15-19.

---

\* PhD,  
Associate Prof, Manchester University, England  
Dpt of Dental Therapeutics,  
Faculty of Dentistry, Tishreen University, Lattakia, Syria  
maroufali@outlook.com.

## Introduction

Cleaning and shaping of root canal is the cornerstone for the success of endodontic treatment [1]. It is essential for the elimination of microorganisms and their products. According to the European Association of Endodontics, the primary objectives in cleaning and shaping the root canal system are the prevention of the occurrence of infection, supporting the healing of lesions through removing the infected soft and hard tissue, facilitating the access of the irrigants to the apical canal area, creating space for the delivery of medicaments and permitting a tight obturation [1].

Schilder (1970) identified five goals that must be achieved in the preparation design: 1) a continuously tapering funnel must be created with its narrowest diameter at the periodontal ligament and its widest diameter at the coronal opening; 2) the canal cross section must be narrower as we head apically; 3) the final shape after preparation must commensurate with the original shape of the channel; 4) the original location of the apical foramen must not change and 5) should be kept as small as possible [2]. In addition, Schilder identified four biologic objectives: 1) preparation should be kept within the canal only, 2) preparation debris should not be pushed outside the apical foramen, 3) removal of all the pulp tissue from the root canal system and 4) creation of enough space for irrigation and filling material [2].

In spite of the ongoing development and the improvement of the root canals preparation techniques, a mechanical preparation of all the root canal walls is still scarcely done [3]. This is mostly related to the fact that the internal shape of the root canals is not always conical or circular [4]. The cross-section of the root canals has recently been classified as follows: circular, elliptical, long, oval-shaped and abnormal [5].

The long oval-shaped canals are considered difficult to prepare because files tend to maintain the original

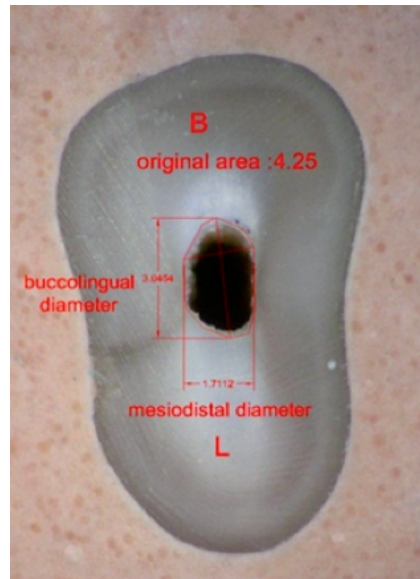


Fig. 1: Canal area before preparation.

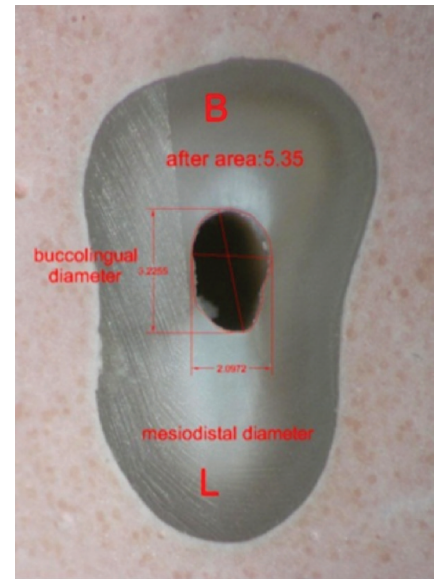


Fig. 2: Canal area after preparation.

canal shape in the central of the canal; this does not allow adequate preparation in the buccal-lingual area [6-11].

The introduction of nickel-titanium tools has contributed in improving the quality of root canals preparation by increasing the diameter and the taper of the prepared canals [12, 13]. High elastic properties of nickel-titanium alloy allow the fabrication of files that have the ability to carry out continuous rotational movements while creating a suitable taper of the root canal, without changing its shape [14, 15].

Multiple preparation techniques with different instruments have been used to prepare long oval-shaped canals such as hand and rotary nickel-titanium instruments. However, they were not able to prepare the entire radicular system and to maintain the original canal shape [9, 16-20].

This study aims to compare four different instruments used for endodontic preparation and evaluate their ability in shaping the apical part of long oval-shaped root canals 3 mm from the apical foramen.

## Materials and methods

### Sample collection

Forty extracted single-rooted human teeth were collected. The teeth were ultrasonically cleaned then stored in distilled water at room temperature until utilization.

The sample was selected based on the following criteria:

- Single rooted tooth.
- Tooth should have one apical foramen. This has been verified by examining the teeth apices using magnifying loops.
- Curvature of the canal is no more than 10 degrees, verified using radiographic x-ray images in both mesial-distal and buccal-lingual directions. Curvature calculation was done using AutoCAD 2014.
- Tooth length of no more than 24 mm.
- Teeth have not been endodontically treated before.

### Sample preparation

Access cavities were prepared using round diamond bur (Horico -

ISO 001/016 FG). Barbed needles were used for removal of pulpal tissue from the canal. Measurement of the working length was done using Mani k-file #10 and an endodontic ruler (SybronEndo).

The apical foramen of each tooth was sealed with light-cured composite. Each tooth was placed separately in a metal mold filled with plaster so that the longitudinal axis of the tooth was parallel to the longitudinal axis of the mold. After that, teeth were cross-sectioned using a diamond disc (Exact BS310; Bio-Optica, Milano, Italy). The apical section was photographed by stereozoom microscope (SZM-2, Optika, Italy) connected to a computer and a camera (Nikon E 8800, Japan). Images were analyzed on AutoCAD 2013 (AutoDesk, San Rafael, CA) to obtain the canal area before preparation (Fig. 1).

After that, the two sections were gathered within the casting mold. A k-file was inserted into the canal to ensure that there is no ledge between the tooth sections. Then teeth were randomly and equally allocated to one of the four groups (N1=N2=N3=N4=10). Each group was prepared using one of the preparation systems:

\* Group I (Traditional manual preparation): Canals were prepared using a Nickel Titanium hand files (Dentsply, Maillefer, Ballaigues, Switzerland). Gates Glidden #3 and #4 (Dentsply, Maillefer, Ballaigues, Switzerland) were used to expand the canals access cavity.

K-files #15 up to #40 were used on the entire perimeter of the canal. The k-files were inserted to the working length constantly. The main k-file was #40 and each k-file was used on the long oval-shaped canal walls at least three times until the walls of the canal showed a sense of smooth while filing.

\*Group II (ProTaper hand files): Canals were prepared using Nickel Titanium ProTaper hand files (Dentsply, Maillefer, Ballaigues, Switzerland). SX, S1 and S2 files were used following the crown-down technique. Then S1, S2, F1 and F2 files were used. F2 file was the final instrument to be used.

$\Delta A$	Third apical at 3 mm from the root apex
	Mean $\pm$ Std. Deviation
Tpre	0.3830 $\pm$ 0.28968
PTH	1.5290 $\pm$ 1.55593
PTU	1.4830 $\pm$ 1.10508
PTN	1.1880 $\pm$ 0.79257
p-value	0.068

Table 1: Changes in the canal diameter  $\Delta A$  after preparation.

Tpre: Traditionnal preparation; PTH: ProTaper hand files; PTU: ProTaper Universal; PTN: ProTaper Next.

All files were inserted to the working length and used at least three times on the canal walls until the canal walls showed a sense of smooth while filing.

\*Group III (ProTaper "Universal" rotary preparation): Canals were prepared using Nickel Titanium Universal ProTaper (Dentsply, Maillefer, Ballaigues, Switzerland). SX, S1 and S2 files were used following the crown-down technique. Then S1, S2, F1 and F2 files were used. F2 file was the final instrument to be used. All files were inserted to the working length. Universal ProTaper files were used on an electric micro-motor handpiece (X-Smart Endodontic Motor, Dentsply International, Inc) at 250 rpm.

\*Group IV (ProTaper "Next" rotary preparation): Canals were prepared using ProTaper Next rotary system which consists of two files only and the C-Smart rotary system at 300 rpm. X1 file was used first after irrigation of the pulp chamber.

Sodium hypochlorite 5.25% irrigant per canal was used during preparation with a rate of 2 mm and EDTA 17% (Metabiome Co, Korea) with a rate of 1 mm for each canal.

After preparation, 2 mm of EDTA were kept in the canal for 2 minutes. Then each canal was rinsed with saline solution. After that, all canals were dried using paper cones (Dia-Dent Inc, USA).

After that, the two sections of each tooth were removed from the mold and were photographed in the same situation that they had been photographed before preparation. Photos then were analyzed using AutoCAD 2013 to calculate the canal area after preparation (Fig. 2).

### Evaluation of the canal preparation

Changes after preparation were evaluated in the apical third of the root canals:

Changes in preparation area: Canal area after preparation – canal area before preparation.

$$A = \text{Post } A - \text{Pre } A \Delta$$

Area before preparation and area after preparation: mean and standard deviation were calculated and one way- ANOVA statistical testing was done followed by post-hoc test.

## Results

The results of the changes on the entire canal wall are listed in the table 1 by calculating changes in the area  $\Delta A$  in the apical third, 3 mm from the apex. The highest value of the canal surface changes was obtained with the ProTaper hand instruments even though the differences were not significant.

The lowest value was observed in the first group, prepared traditionally with the NiTi hand files. Also, the dif-

ference was not statistically significant with the other groups.

## Discussion

The mechanical preparation of the root canal system is considered one of the most important steps in endodontic treatment [1]. The purpose of endodontic treatment is to prevent the occurrence of periapical periodontitis and to ensure the healing of periapical lesions when occurring. This is achieved through removal of the infected pulpal tissue from root canal, creating enough space for irrigants and medicaments, maintaining the anatomical position of the apical foramen, facilitating the process of canal obturation, avoiding the transmission of bacteria into the periapical area and finally maintaining sound the root canal architecture [4].

Despite the ongoing development and the amelioration in root canals preparation techniques, a mechanical preparation for the entire walls of the canal is rarely accomplished [3] due to the complexity of the root canal system and its anatomical structure. The best way to prepare canals is according to a circular section while maintaining the original anatomical structure of the root canal. However, achieving that form of preparation is usually difficult because the natural anatomical shapes of root canals are not always circular but tend to be irregular long and oval. Because the cross-section of the most human teeth is not always circular, human teeth with single long oval-shaped canal have been used in this study, especially that the prevalence of long oval-shaped canals in teeth is more than 25% [4, 5, 11].

The Bramante technique modified by Kuttler [21] was used in this study because it is easy and inexpensive compared to the computerized tomography [22, 23].

The ProTaper Next was recently launched in the market. This system has a special design so that the file rotation axis does not match with the axis passing from the center of mass.

This is known as “offset” design. The resulting mechanical wave motion is transmitted through the working portion of the file. This non-symmetrical design reduces the file friction with the dentin [24].

The results of the current study showed no statistically significant differences between the different preparation groups. Our results are in agreement with those of Paqué et al. [25] who showed that the increase in the preparation diameter of root canals in the apical third is not statistically significant when using nickel-titanium rotary instruments. Also, Grande et al. [22] compared NiTi rotary instruments and stainless steel reciprocating files in preparation of long oval-shaped canals; they found no statistically significant differences in the apical third. Cumbo [26] compared Mtwo and BioRace preparation systems. The difference in the root canal enlargement wasn't statistically significant especially in apical third of the canals. These results can be attributed to the large degree of similarity between these two systems; also, the shape of the root canal was not determined via cross-sections. SAF and K3 systems were compared when preparing flat-oval root canals in the study of Versiani et al. [27]; no statistically significant difference was noted between the two systems.

## Conclusion

Within the limitations of the present study, it can be concluded that the four preparation groups did not render any statistically significant change in the apical third of the root canal at 3 mm from the root apex.

Further research are still needed that include preparation along the root canal and not only in the third apical to find ways to reach out to the best method of root canal preparation.

## References

- Hulsmann M, Peters OA, Dummer PMH. Mechanical preparation of root canals: shaping goals, techniques and means. *Endodontic topics* 2005;10(1):30-76.
- Schilder H. Filling root canals in three dimensions. *J Endodont* 2006;32(4):281-90.
- Aydin C, Tunca YM, Senses Z, Baysallar M, Kayaoglu G, Ørstavik D. Bacterial reduction by extensive versus conservative root canal instrumentation in vitro. *Acta Odontologica Scandinavica* 2007;65(3):167-70.
- Schilder H. Cleaning and shaping the root canal. *Dent Clin North Am* 1974;18:269-96.
- Jou YT, Karabucak B, Levin J, Liu D. Endodontic working width: current concepts and techniques. *Dental Clinics* 2004;48(1):323-35.
- Metzger Z, Teperovich E, Zary R, Cohen R, Hof R. The self-adjusting file (SAF). Part 1: respecting the root canal anatomy—a new concept of endodontic files and its implementation. *J Endodont* 2010 Apr 30;36(4):679-90.
- Paqué F, Peters OA. Micro-computed tomography evaluation of the preparation of long oval root canals in mandibular molars with the self-adjusting file. *J Endodont* 2011;37(4):517-21.
- Rodig T, Hulsmann M, Muhge M, Schafers F. Quality of preparation of oval distal root canals in mandibular molars using nickel-titanium instruments. *Int Endodont J* 2002;35(11):919-28.
- Weiger R, ElAyouti A, Löst C. Efficiency of hand and rotary instruments in shaping oval root canals. *J Endodont* 2002;28(8):580-3.
- Paqué F, Ganahl D, Peters OA. Effects of root canal preparation on apical geometry assessed by micro-computed tomography. *J Endodont* 2009;35(7):1056-9.
- Wu MK, R'oris A, Barkis D, Wesselink P. Prevalence and extent of long oval canals in the apical third. *Oral Surgery, Oral Medicine, Oral Pathology, Oral Radiology, and Endodontology* 2000;89(6):739-43.
- Walia HM, Brantley WA, Gerstein H. An initial investigation of the bending and torsional properties of Nitinol root canal files. *J Endodont* 1988;14(7):346-51.
- Thompson SA. An overview of nickel-titanium alloys used in dentistry. *Int Endodont J* 2000;33(4):297-310.
- Schäfer E, Schulz-Bongert U, Tulus G. Comparison of hand stainless steel and nickel titanium rotary instrumentation: a clinical study. *J Endodont* 2004;30(6):432-5.
- Schäfer E. Shaping ability of Hero 642 rotary nickel-titanium instruments and stainless steel hand K-Flexofiles in simulated curved root canals. *Oral Surgery, Oral Medicine, Oral Pathology, Oral Radiology, and Endodontology* 2001;92(2):215-20.
- Wu MK, Sluis LW, Wesselink PR. The capability of two hand instrumentation techniques to remove the inner layer of dentin in oval canals. *International Endodont J* 2003;36(3):218-24.
- Elayouti A, Chu AL, Kimionis I, Klein C, Weiger R, Löst C. Efficacy of rotary instruments with greater taper in preparing oval root canals. *Int Endodont J* 2008;41(12):1088-92.
- De-Deus G, Barino B, Zamolyi RQ, Souza E, Fonseca A Jr, Fidel S, Fidel RA. Suboptimal debridement quality produced by the single-file F2 ProTaper technique in oval-shaped canals. *J Endodont* 2010;36(11):1897-900.
- Barbizam JV, Fariniuk LF, Marchesan MA, Pecora JD, Sousa-Neto MD. Effectiveness of manual and rotary instrumentation techniques for cleaning flattened root canals. *J Endodont* 2002;28(5):365-6.
- Taha NA, Ozawa T, Messer HH. Comparison of three techniques for preparing oval-shaped root canals. *J Endodont* 2010;36(3):532-5.
- Kuttler S, Garala M, Perez R, Dorn SO. The endodontic cube: a system designed for evaluation of root canal anatomy and canal preparation. *J Endodont* 2001;27(8):533-6.
- Grande NM et al. Cross-sectional analysis of root canals prepared with NiTi rotary instruments and stainless steel reciprocating files. *Oral Surgery, Oral Medicine, Oral Pathology, Oral Radiology, and Endodontology*. 2007;31;103(1):120-6.
- Bergmans L, Van Cleynenbreugel J, Wevers M, Lambrechts P. A methodology for quantitative evaluation of root canal instrumentation using microcomputed tomography. *Int Endodont J* 2001;34(5):390-8.
- Ruddle CJ, Machtou P, West JD. The shaping movement 5th generation technology. *Dentistry today* 2013 Apr.
- Paqué F, Balmer M, Atting T, Peters OA. Preparation of oval-shaped root canals in mandibular molars using nickel-titanium rotary instruments: a micro-computed tomography study. *J Endodont* 2010;36(4):703-7.
- Cumbo E, Russo R, Gallina G. Assessment of root canal enlargement using Mtwo and BioRace rotary files. *The Scientific World Journal* 2015;23:2015.
- Versiani MA, Pécora JD, de Sousa-Neto MD. Flat-oval root canal preparation with self-adjusting file instrument: a micro-computed tomography study. *J Endodont* 2011;37(7):1002-7.